

RESEARCH ARTICLE

A Novel “Onder Speculum” to Visualize and Retract the Cervix During Transcervical Procedures in Small Ruminants

Nail Tekin ÖNDER ¹ (*)  Taygun GÖKDEMİR ¹  Muhammet Can KILIÇ ¹  Oğuzhan ŞAHİN ¹ 
Murat Can DEMİR ²  Savaş YILDIZ ¹  Cihan KAÇAR ²  Yavuz ÖZTÜRKLER ¹ 

¹ Department of Reproduction and Artificial Insemination, Faculty of Veterinary Medicine, Kafkas University, TR-36100, Kars - TÜRKİYE

² Department of Obstetrics and Gynecology, Faculty of Veterinary Medicine, Kafkas University, TR-36100 Kars - TÜRKİYE



(*) **Corresponding author:** Nail Tekin ÖNDER

Tel: +90 507 388 9600

Email: nailtekinonder@gmail.com

How to cite this article?

Önder NT, Gökdemir T, Kılıç MC, Şahin O, Demir MC, Yıldız S, Kaçar C, Öztürkler Y: A novel “Onder Speculum” to visualize and retract the cervix during transcervical procedures in small ruminants. *Kafkas Univ Vet Fak Derg*, 30 (1): 101-106, 2024.
DOI: 10.9775/kvfd.2023.30605

Article ID: KVFD-2023-30605

Received: 20.09.2023

Accepted: 18.11.2023

Published Online: 09.12.2023

Abstract

The visualization of the cervix and subsequent manipulations during transcervical applications in sheep might require a degree of straining reflexes while using the Collin Speculum. Therefore, this study aimed to develop and to evaluate the feasibility of a new alternative speculum design for non-surgical assisted reproductive procedures in small ruminants. Collin speculum (CS) and the new “Onder speculum” (OS) were used to assess cervical entrance in 30 ewes. The OS efficiency for a successful cervical retraction was also evaluated. Data showed that the cervical entrance was visible in 8 out of the 30 females with CS, while it was observed in all the animals when using OS ($P < 0.001$). The latter was successful in the retraction of the cervical entrance in 10 randomly selected animals out of the total. To conclude, the newly developed speculum effectively supported the implementation of non-surgical assisted reproductive procedures in small ruminants and was also considered to have the potential to facilitate non-invasive reproductive techniques in these species.

Keywords: Small ruminants, Speculum, Cervix entrance

INTRODUCTION

Small ruminant breeding has a significant role in some nations with regards to animal-based food intake and holds a crucial place in human nutrition. In addition to the production of meat and milk, it also serves as a great contributor to the country's economy through its involvement in the manufacture of wool, mohair, and leather. Assisted reproductive techniques are frequently employed to regulate the reproductive processes in sheep exhibiting seasonal breeding patterns ^[1-3]. Artificial insemination (AI), a prominent biotechnology approach within assisted reproductive methods, involves the introduction of fresh, cooled or frozen male gamete cells into female animals ^[4]. Another assisted reproductive strategy employed to enhance productivity in sheep breeding falls within the realm of embryo production. Sheep that are commonly chosen as donors in embryo production undergo superovulation techniques. After

this process, the embryos pass through a series of flushing processes before being transferred to carrier animals ^[5,6]. Surgical techniques are generally used in the context of AI and embryo production procedures in sheep, mostly owing to the intricate nature of the cervix. Nevertheless, apart from the constraining prerequisites associated with surgical techniques, such as the considerable cost of instruments and the necessity for highly skilled staff, there is also the potential occurrence of adhesions subsequent to surgical treatments, which can lead to numerous adverse outcomes that detrimentally impact the wellbeing of animals. For this reason, many researchers are currently engaged in the exploration of non-invasive procedures and their implementation in ovine assisted reproductive methodologies ^[7-9].

Reproductive management in small ruminants remains a focal field of interest among scientists, mostly because of the challenges associated with cryopreserving semen



as well as the complexities involved in AI and multiple ovulation and embryo transfer (MOET) procedures [10-12]. In the context of AI and embryo production in cows, practitioners have the ability to manipulate the cervix by contacting it through the rectum using one arm while concurrently managing catheters with the other hand [13]. However, the structure of the cervix has been identified as having a particularly hard aspect for practitioners, namely in some techniques such as AI and MOET procedures which limit their use [8,9,11]. Therefore, in non-surgical embryo production in sheep, researchers describe the initial step as retracting the cervical line to align with the vaginal entrance line, thereby facilitating visibility of the cervical opening. Following this phase, cervical manipulations could be conducted [8,14].

The duck-billed speculum is mostly used in AI techniques conducted on sheep [15,16]. According to different studies, the CS is used in procedures involving embryo flushing and transfer, which necessitate cervical manipulations. In this particular instrument, the speculum can be removed from the vagina subsequent to the stabilization of the cervical entrance, achieved by employing forceps directed through the vaginal canal [8,17,18]. According to reports, it is expected that the insertion of the speculum into the vaginal cavity will cause pushing reflexes in the animal. As a result, the cervical opening is predicted to shift slightly towards the dorsum to allow visualization of the cervical entrance [19]. The main objective of this study was to develop and evaluate the feasibility of a novel speculum design. The proposed speculum aimed to facilitate visualization of the cervix without eliciting the reflexive response associated with speculum insertion. Additionally, it was designed to allow the manipulation of the cervical line by means of forceps, allowing for posterior retraction.

MATERIAL AND METHODS

Ethical Approval

The Scientific Ethical Committee of Kafkas University in Kars, Türkiye has granted approval for all issues pertaining to the experimental setups and evaluation methodologies under the reference number KAÜ-HADYEK 2023-047.

Animal

A total of 30 Tuj ewes, aged between 2 and 5 years, were housed under identical conditions at Prof. Dr. Ali Riza Aksoy Education, Research and Application Farm, Kafkas University, Faculty of Veterinary Medicine in Kars, Türkiye.

Experimental Design

The present investigation involved the selection of a sample of 30 animals in order to investigate the effect of CS and OS on the observation of the cervical inlet.

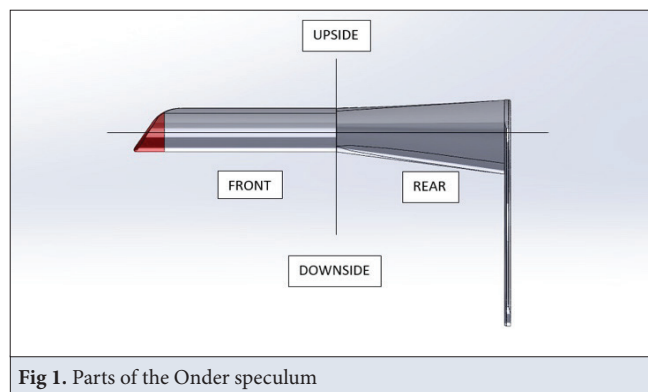


Fig 1. Parts of the Onder speculum




Fig 2. X and Y axis of rear cavity

To minimize the impact of individual differences, the same animals have been used in both the CS and OS experimental groups for the entire period of the research. No additional interventions were performed apart from the manipulation of the speculum.

The study also evaluated the potential efficacy of the OS for transcervical applications by evaluating its success in 10 ewes. During this phase, an assessment was conducted based on the criteria of retracting the cervical entrance and successfully completing the stages involving the removal of the speculum. The successful completion of all stages was deemed acceptable.

Speculum Design

The speculum was designed to have a length of 10 cm in the front region, 8.5 cm in the rear region, and a combined length of 18.5 cm, as depicted in Fig. 1. An angled transition was observed at a distance of 1.5 cm from the tip of the front portion of the speculum. To enhance structural integrity, the thickness of the material was modified to 2.5 mm in the anterior and posterior regions, while the handle portion was adjusted to a thickness of 3 mm. The anterior section was constructed in a circular shape, with a diameter of 2 cm within its inner region. The upper opening at the front measures 1 cm and the rear measures

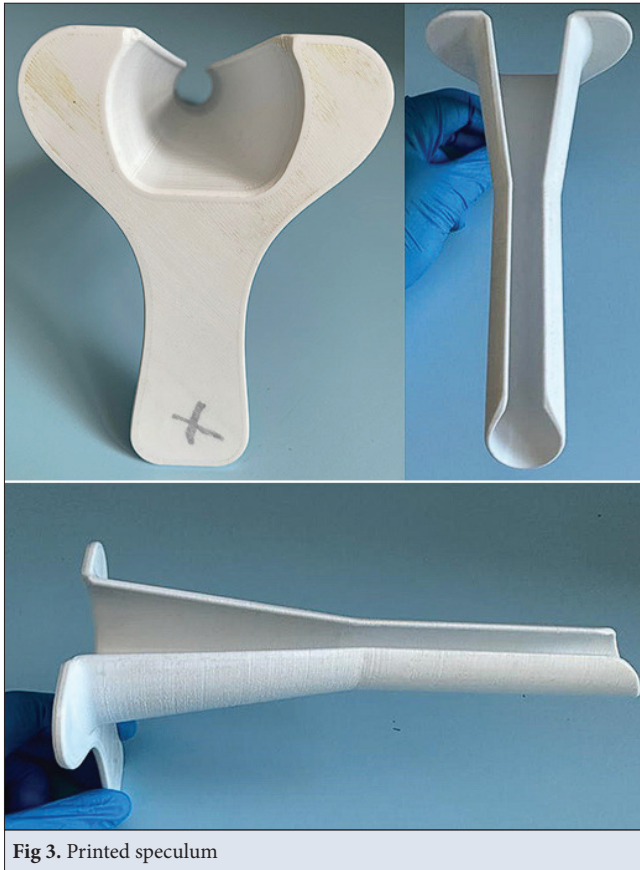


Fig 3. Printed speculum

3 cm, whereas the x and y axes have dimensions of 3.5 cm and 4.5 cm, respectively (Fig. 2). The posterior portion of the speculum exhibits lateral regions measuring 2 cm, while the length of the handle is 8 cm.

The speculum was created with the computer-aided design software SolidWorks 2022, employing a three-dimensional design approach. Subsequently, it was manufactured utilizing polylactic acid material by using a Creality Ender-5 Plus 3D printer (Shenzhen, China) with a 100% fill rate. In Fig. 3, the printed version of the speculum is presented from different angles.

Speculum Testing and Cervical Penetration

Sheep were restrained in a standing position, and to prevent contamination, the tail was tied. Prior to the speculum application, the perineal region underwent a cleansing procedure using povidone iodine. Small CS and OS were lubricated, the vulva was opened, and speculums were inserted into the vagina in order. Subsequently, attempts were made to locate the cervical entrance simply through the use of speculum movements. A head lamp was used to observe the cervical entrance with a speculum.

At the cervical penetration phase, only the OS was used. The technique used by Pereira et al.^[20] underwent modifications as described by Önder et al.^[21]. The cervical entrance was grasped with forester ring forceps. Following

Table 1. Speculums and instances of successful outcomes

Success Status	Collin (n/Total)	Onder (n/Total)
Successful	8 (30) ^a	30 (30) ^b
Fail	22 (30)	0 (30)

^{a,b} Values with different superscripts in the same column are significantly different (P<0.001)

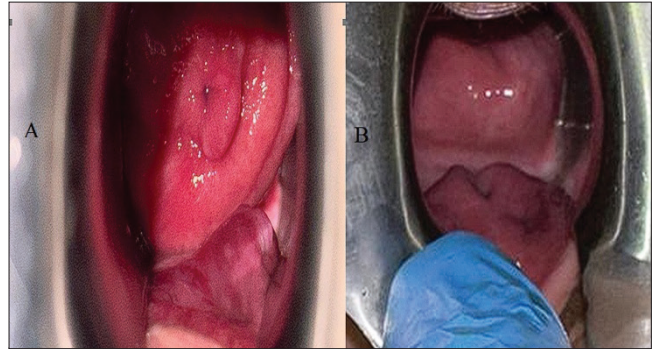


Fig 4. Successful visualization of cervical entrance (A) and Failure in visualization (B)

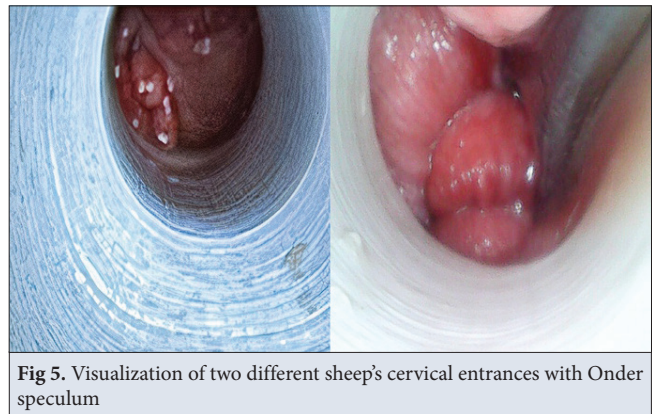


Fig 5. Visualization of two different sheep's cervical entrances with Onder speculum

the removal of the speculum, the cervix was subsequently moved in a caudal direction.

Statistical Analysis

The statistical analysis of the study was conducted using the SPSS program (SPSS 28.0 for Windows; SPSS, Chicago, IL, USA). The Pearson Chi-Square method was used to analyze the data in this study. The statistical significance level has been set at an acceptable value of P<0.05, and the corresponding outcomes were reported accordingly.

RESULTS

In this present work, it was observed that the cervical entrance was directly visible in 8 out of the 30 females examined while using the CS. With OS, cervical entrance was observed in all the animals (Table 1). Statistical analysis revealed a significant difference between the speculums (P<0.001). In Fig. 4, successful and unsuccessful applications are presented visually with the CS. In Fig. 5,

a section was taken from the successful application with the OS. Regarding the retraction of the cervical entrance using the OS, our data showed a complete success in 10 randomly selected animals out of a total of 30.

The use of the OS revealed that the Polylactic acid (PLA) substance employed for producing the product using a 3D printer did not cause any adverse impacts on animals. It was observed that the OS could be easily directed into the vaginal canal, up to the opening of the cervix. The positioning of the cervical port was adjusted to the distal end of the speculum, enabling the subsequent manipulation of the cervix region using forceps. Following the secure positioning of the cervix, an assessment was conducted to determine the feasibility of removing the speculum from the vagina without encountering any complications, while the forceps remained within the speculum. During this phase, it was noted that the removal of the speculum proceeded without any complications. It has been found that in some animals, the complete insertion of the speculum into the vaginal canal is not possible. Nevertheless, it has been noted that even in such instances, the speculum did not compromise its easy-to-use features.

It was seen that the animals exhibited pushing reactions as the speculum proceeded into the vagina while using both speculums. The fact that the cervix was only visible in 8 animals when using the CS suggests that the strength of the animal's pushing reflexes might have an impact on the cervical line's position, causing it to point in the animal's dorsal region.

DISCUSSION

In our clinical experience, the observation and manipulation of the cervix have posed significant challenges in transcervical surgeries conducted on sheep. In light of these issues encountered in visualizing the cervix predominantly through the speculum and the subsequent difficulties in stabilizing the cervical entrance, our research attempts have been directed toward designing an alternative speculum.

The utilization of computer-aided drawing tools enables the production of products through 3D printers, eliminating the need for molds in the manufacturing process. A diverse range of raw materials are utilized in the manufacturing process of items through the utilization of 3D printers. According to reports, the commonly utilized raw materials consist of filaments, which are thermoplastic polymers. PLA, a type of thermoplastic material, is notable for its biocompatible and biodegradable characteristics, as well as its comparatively reasonable pricing [22,23]. It finds applications in diverse industries, including the automotive, textile, and biomedical sectors [23]. In the presented study,

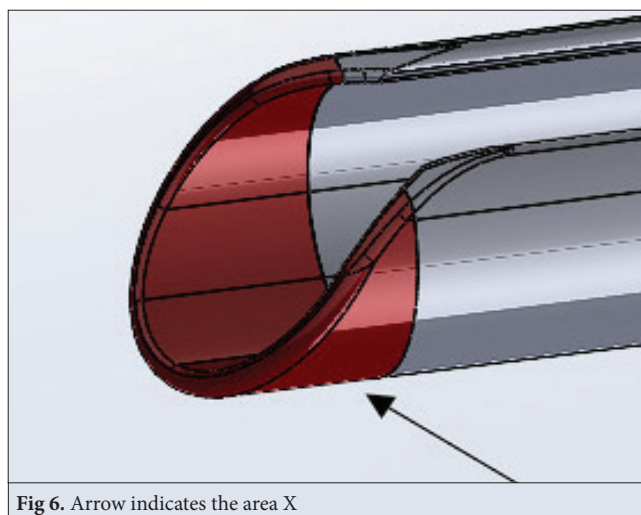


Fig 6. Arrow indicates the area X

PLA was preferred in speculum production due to its use in the biomedical field. In our investigation, we did not see any discernible adverse effects of this substance utilized in the fabrication of speculums on the animal subjects. No adverse outcomes, such as stretching, bending, or breaking of the speculum, were seen throughout usage, as the material was manufactured to meet the specified thickness and full filling rate outlined in its design.

The OS, derived from the duck-billed speculum and the CS, has a total length of 18.5 cm. The design of the instrument took into consideration the need to eliminate sharp edges. The front section of the speculum aims to ensure that, following the insertion of the device into the vagina, any manipulations performed in the cranial vaginal region do not cause the cervical entrance to move farther cranially. The part of the speculum that will provide the initial entrance into the vagina is shaped with a backward inclination to prevent tissue damage and facilitate a smoother transition. Also, another crucial objective at this stage was to ensure that the cervical entrance is positioned within the X area (Fig. 6) once it has been observed.

The speculum is specifically engineered to have a 2 cm diameter in its anterior 10 cm segment, facilitating the introduction of the Forrester ring forceps. Additionally, a 1 cm opening is strategically positioned in the ventral area of the speculum to provide easy removal without any interference with the forceps while it remains inside the vagina. It was hypothesized that an increased aperture size of 1 cm could potentially result in the accumulation of vaginal tissue within the speculum, hence limiting the intended procedures. The presence of a closed lower region and a c-shaped design in the 10 cm part of the speculum effectively prevents the entry of vaginal tissue. The findings of this study demonstrate that the OS effectively maintains the position of the cervical line and aligns it with the vulva, therefore validating the inclusion of these features in the design of the speculum.

In the posterior section of the speculum, the upper aperture increases from 1 cm to 30.00 mm. Simultaneously, the length of the x-axis undergoes continuous expansion, ultimately reaching a final measurement of 45.00 mm. The utilization of forceps has been effectively manipulated by the augmentation of the X and Y axes. The design of the speculum includes a flat base in the posterior region, which serves the purpose of providing less covering within the vaginal canal and facilitating ease of application. The lateral regions of the speculum, similar to the Collin, were designed specifically to minimize the risk of contamination along the inner surface of the instrument during its use.

The current investigation revealed significantly limited efficacy of the CS in spotting the cervical opening without any form of manipulation. It was thought that this was due to the fact that the CS was not designed for use in assisted reproductive techniques for sheep. The proper positioning of the cervical entrance with the newly constructed speculum demonstrates agreement with the aforementioned idea. According to available reports, it has been observed that Allis forceps and Pozzi forceps are frequently used in research conducted using the CS [9,24]. The utilization of Forrester ring forceps has been favored due to the fact that the use of Pozzi forceps may result in minor instances of hemorrhaging, as observed in our investigations [21]. Based on our research findings, the utilization of Pozzi forceps facilitates the extraction of the cervical line in a more efficient manner due to their ability to pierce and pull the cervical entrance area. Conversely, the use of Forrester ring forceps presents challenges in extracting the cervical line without causing active bleeding. The utilization of the OS facilitates the manipulation with the Forrester ring forceps due to the repositioning of the cervical entrance in a cranial direction, resulting in increased ease of maneuverability and a degree of resistance.

In summary, our study determined that the newly developed speculum effectively supported the implementation of non-surgical assisted reproductive procedures in small ruminants. Furthermore, it is believed that the use of the OS holds potential for assisting researchers in their pursuit of advancing non-invasive reproductive techniques in small ruminants.

Data Availability

The data used to support the findings of this study are available from the corresponding author (N.T. Önder) upon request.

Ethical Approval

The Scientific Ethical Committee of Kafkas University in Kars, Türkiye has granted approval for all issues pertaining to the experimental setups and evaluation methodologies under the reference number KAÜ-HADYEK 2023-047.

Acknowledgements

We would like to extend our heartfelt gratitude to Salman Mammadli for his invaluable assistance in rendering the speculum through the

use of the Solidworks software, then producing it via a 3D printer.

Conflict of Interest

The authors declare that they have no conflict of interest.

Author Contribution Section

NTO designed the speculum and the study. NTO performed the experiment. NTO wrote the manuscript. TG, MCK, OS, MCD, CK, SY, YÖ provided assistance during the experiment. NTO performed the statistical analysis.

REFERENCES

1. Birlir S, Pabuccuoğlu S, Atalla H, Alkan S, Özdaş ÖB, Bacinoğlu S, Cirit Ü, Zavar İ, Sönmez MEC, İleri İK: Transfer of *in vitro* produced sheep embryos. *Turk J Vet Anim Sci*, 26 (6): 1421-1426, 2002.
2. Foote RH: The history of artificial insemination: Selected notes and notables. *J Anim Sci*, 80, 1-10, 2010.
3. Semerci A, Çelik AD: Türkiye'de küçükbaş hayvan yetiştiriciliğinin genel durumu. *MKÜ Ziraat Faki Derg*, 21 (2): 182-196, 2016.
4. Herdoğan M, Çay HA, Kahraman D, Inanç ME, Güngör Ş, Ata A: Suni tohumlamanın tarihsel gelişimi ve dönüm noktaları. *Vet Hekim Der Derg*, 94 (1): 84-95, 2023. DOI: 10.33188/vetheder.1159178
5. Oral H, Kuru M: Koyun ve keçilerde klinik ve deneysel reproduktif cerrahi. *Türkiye Klinikleri J Vet Sci Obstet Gynecol-Special Topics*, 2 (1): 83-88, 2016.
6. de Albuquerque Lagares M, Varago FC, Moustacas VS, Gheller VA, Nicolino RR, Borges I, Henry M: Effect of season and frequency of embryo collections on superovulatory response and embryo recovery in Santa Inês hair sheep. *Small Ruminant Res*, 201:106441, 2021. DOI: 10.1016/j.smallrumres.2021.106441
7. Souza-Fabjan JMG, Oliveira MEF, Guimarães MPP, Brandão FZ, Bartlewski PM, Fonseca JF: Non-surgical artificial insemination and embryo recovery as safe tools for genetic preservation in small ruminants. *Animal*, 17:100787, 2023. DOI: 10.1016/j.animal.2023.100787
8. Fonseca JF, Souza-Fabjan JMG, Oliveira MEF, Leite CR, Nascimento-Penido PMP, Brandão FZ, Lehloeny KC: Nonsurgical embryo recovery and transfer in sheep and goats. *Theriogenology*, 86 (1): 144-151 2016. DOI: 10.1016/j.theriogenology.2016.04.025
9. Fonseca JF, Oliveira MEF, Brandão FZ, Batista RI, Garcia AR, Bartlewski PM, Souza-Fabjan JM: Non-surgical embryo transfer in goats and sheep: The Brazilian experience. *Reprod Fertil Dev*, 31 (1): 17-26, 2019. DOI: 10.1071/rd18324
10. Camacho M, Garza D, Gutiérrez-Zamora B, Rodríguez-Ramírez H, Méndez-Zamora G, Kawas JR: Superovulatory response and embryo quality in Boer does following dietary supplementation with different sources of omega-3 and omega-6 fatty acids during the breeding season. *Anim Reprod Sci*, 227:106718, 2021. DOI: 10.1016/j.anireprosci.2021.106718
11. Leethongdee S: Development of trans-cervical artificial insemination in sheep with special reference to anatomy of cervix. *Suranaree J Sci Technol*, 17 (1): 57-69, 2010.
12. Onder NT, Alcay S, Nur Z: Effects of alpha-lipoic acid on ram semen cryopreservation and post-thaw life span. *Andrologia*, 54 (1):e14249, 2022. DOI: 10.1111/and.14249
13. Moore SG, Hasler JF: A 100-year review: Reproductive technologies in dairy science. *J Dairy Sci*, 100 (12): 10314-10331, 2017. DOI: 10.3168/jds.2017-13138
14. Dos Santos VM, Pinto PHN, Balara MFA, Santos JD, Taira AR, do Espírito Santo CG, Gonçalves FM, da Fonseca JF, Brandão FZ: Use of oxytocin to attain cervical dilation for transcervical embryo transfer in sheep. *Reprod Domest Anim*, 55 (10): 1446-1454, 2020. DOI: 10.1111/rda.13795
15. Leethongdee S, Thuangsanthia A, Khalid M: Topical application of cervix with hyaluronan improves fertility in goats inseminated with frozen-thawed semen. *Anim Biosci*, 34 (6): 985-992, 2021. DOI: 10.5713/ajas.20.0284

16. Halbert GW, Dobson H, Walton JS, Buckrell BC: A technique for transcervical intrauterine insemination of ewes. *Theriogenology*, 33 (5): 993-1010, 1990. DOI: 10.1016/0093-691X(90)90061-W
17. Oliveira MEF, Arrais AM, Vergani GB, Novita Esteves S, Schinaider Do Amaral Pereira V, Garcia AR, Bastos R, Melo MRB, Alves BRC, Ferreira Fonseca J: Hormonal-induced cervical relaxation during diestrus in ewes: Cervical transposing feasibility and use of hCG for rescuing disrupted luteal function. *J Appl Anim Welf Sci*, 2022:1-17, 2022. DOI: 10.1080/10888705.2022.2141576
18. Önder NT, Batı YU, Gökdemir T, Kılıç MC, Şahin O, Öğün M, Akyüz E, Kuru M, Kırmızıgül AH, Yıldız S, Öztürkler Y: Oxidative response of sheep to transcervical applications. *Reprod Domest Anim*, 58 (6): 877-881, 2023. DOI: 10.1111/rda.14361
19. Fonseca JF, Zambrini FN, Alvim GP, Peixoto MG, Verneque RS, Viana JH: Embryo production and recovery in goats by non-surgical transcervical technique. *Small Rumin Res*, 111 (1-3): 96-99, 2013. DOI: 10.1016/j.smallrumres.2012.08.007
20. Pereira RJTA, Sohnrey B, Holtz W: Nonsurgical embryo collection in goats treated with prostaglandin F2 α and oxytocin. *J Anim Sci*, 76 (2): 360-363, 1998. DOI: 10.2527/1998.762360x. DOI: 10.2527/1998.762360x
21. Önder NT, Gökdemir T, Kılıç MC, Şahin O, Toker BM, Yıldız S, Öztürkler Y: Does isoxsuprine HCl facilitate the passage of the cervix in sheep?: A case series. *Large Anim Rev*, 29 (2): 89-92, 2023.
22. Kaptan A, Kartal F: The effect of fill rate on mechanical properties of PLA printed samples. *J Sci Technol*, 10 (3): 1919-1927, 2020. DOI: 10.21597/jst.706003
23. Ilyas RA, Sapuan SM, Harussani MM, Hakimi MYAY, Haziq MZM, Atikah MSN, Asyraf MRM, Ishak MR, Razman MR, Nurazzi NM, Norrahim MNF, Abrial H, Asrofi M: Polylactic acid (PLA) biocomposite: Processing, additive manufacturing and advanced applications. *Polymers*, 13 (8): 1326, 2021. DOI: 10.3390/polym13081326
24. Amorim LDS, Torres CAA, Siqueira LGB, Fonseca JFD, Guimarães JD, Carvalho GRD, Alves NG, Oliveira MMNFD: Embryo development and follicular status of Toggenburg does fed urea diet. *R Bras Zootec*, 40, 277-285, 2011. DOI: 10.1590/S1516-35982011000200007