

RESEARCH ARTICLE

Effects of Gossypin on Fracture Healing in Experimental Femur Fractured Mouse Mechano-Bioregulatory Model

Kadri YILDIZ^{1,a (*)} Mehmet Fatih TURALIOGLU^{2,b} Veyssel TAHIROGLU^{3,c} Fatih BOY^{3,d} Serdar YIGIT^{4,e}¹ Orthopedics and Traumatology Department, Faculty of Medicine, Kafkas University, TR-36100 Kars - TURKEY² Orthopedics and Traumatology Clinic, Ministry of Health Yavuz Selim Bone Disease Hospital, TR-61030 Trabzon - TURKEY³ Biochemistry Department, Faculty of Medicine, Kafkas University, TR-36100 Kars - TURKEY⁴ Histology and Embryology Department, Faculty of Medicine, Kafkas University TR-36100 Kars - TURKEYORCID: ^a 0000-0002-8164-7687; ^b 0000-0002-2852-4274; ^c 0000-0003-3516-5561; ^d 0000-0003-0979-0996; ^e 0000-0001-5631-2335

Article ID: KVFD-2021-25516 Received: 04.02.2021 Accepted: 23.07.2021 Published Online: 28.07.2021

Abstract

This paper aimed to research the possible effects of gossypin in a mechano-bio-regulatory mouse model for bone fracture healing. A total of 28 male *Mus musculus* BALB/c mice were randomly selected. Four groups were created. Each group consisted of 7 mice. The Control group was called Group 1. Group 2 was a femur fractured group of mice without any medication. Group 3 was the dose group of 5 mg/kg gossypin to mouse with femur fractures. Group 4 was the dose group of 10 mg/kg gossypin to mouse with femur fractures. An open fracture model was created in the right femur of the animals in Groups 2, 3, and 4. The radiological views for all groups were taken on postoperative 1st day, 6th week, and 12th week. All samples were obtained, collected, and prepared for biomechanical features, histopathological examinations, biochemical tests, and PCR tests. In terms of radiological and histological results, gossypin showed a significant difference depending on the dose in Group 4 to Group 3. Gossypin had sufficient antioxidant and anti-inflammatory effects in mice with femur fracture in bone healing in Groups 3 and 4. Biomechanical tests showed enough hardness levels and high thresholds in braking forces.

Keywords: Femur fracture, Mouse, Gossypin, Antioxidant, Anti-inflammatory

Gossypin'in Fare Mekano-Biyoregülatör Modeli Deneysel Femur Kırıklarında Kırık İyileşmesi Üzerine Etkileri

Öz

Bu çalışma, gossypin'in kemik kırık iyileşmesi için fare mekano-biyoregülatör modelinde olası iyileştirici etkilerini araştırmayı amaçladı. Toplam 28 erkek *Mus musculus* BALB/c faresi rastgele seçildi. Dört grup oluşturuldu. Her grup 7 fare içermektedir. Kontrol grubu Grup 1 olarak adlandırıldı. Grup 2 herhangi bir ilaç uygulaması yapılmayan femur kırıklı fare grubuydu. Grup 3, 5 mg/kg gossypin uygulanan femur kırıklı fare doz grubuydu. Grup 4, 10 mg/kg gossypin uygulanan femur kırıklı fare doz grubuydu. Grup 2, 3 ve 4'teki hayvanların sağ femurlarında açık kırık modeli oluşturuldu. Postoperatif birinci gün, altıncı ve onikinci hafta sonunda tüm gruplar için radyolojik tetkikler yapıldı. Tüm örnekler alındı, toplandı ve biyomekanik testler, histopatolojik incelemeler, biyokimyasal testler, PCR testleri için hazırlandı. Radyolojik ve histolojik sonuçlar açısından gossypin, doza bağlı olarak önemli bir farklılık göstermiştir. Gossypin, kemik iyileşmesinde femur kırığı olan farelerde yeterli antioksidan ve antiinflamatuvar etkilere sahipti. Biyomekanik testler, yeterli kemik sertlik dereceleri ve kırılma kuvvetlerinde yüksek eşik değerleri gösterdi.

Anahtar sözcükler: Femur kırığı, Fare, Gossypin, Antioksidan, Anti-inflamatuvar

INTRODUCTION

Gossypin is a bioflavonoid that is found naturally in plants (Malvaceae, *Hibiscus vitifolius*). It has some protective effects against various diseases that have been declared

in studies. These effects can be listed as antioxidant, anti-inflammatory, and analgesic effects. In an earlier study, gossypin was evaluated to establish analgesic effects in mice ^[1]. In rats, the neuroprotective effects were shown *in-vivo* studies ^[2,3]. In an experimental sepsis model of

How to cite this article?

Yıldız K, Turalioğlu MF, Tahiroğlu V, Boy F, Yigit S: Effects of gossypin on fracture healing in experimental femur fractured mouse mechano-bioregulatory model. *Kafkas Univ Vet Fak Derg*, 27 (4): 445-454, 2021.
DOI: 10.9775/kvfd.2021.25516

(*) Corresponding Author

Tel: +90 474 225 1150 Cellular phone: +90 538 545 0559 Office: Fax: +90 474 225 1161

E-mail: drkadri1980@hotmail.com (K. Yıldız)



This article is licensed under a Creative Commons Attribution-NonCommercial 4.0 International License (CC BY-NC 4.0)

rats, the effects of gossypin against acute lung injury were demonstrated [4]. Similarly, gossypin was found effective in the treatment of rats with gentamicin-induced nephrotoxicity [5]. Similarly in rats, Tanyeli et al. [6] defended that gossypin had protective effects in the renal ischemia. However, gossypin had ameliorative effects in rats with the formation of galactose-induced cataracts [7]. The anti-oxidant effects were shown in a study in beta-amyloid-induced toxicity [8].

As a flavonoid, gossypin had potent antioxidant and free radical scavenging effects on different in-vitro systems. Ganapaty et al. [9] demonstrated in their study as an in-vitro evaluation. Reactive oxygen species (ROS) are products of the normal oxidation process. ROS is counted as singlet oxygen, hydroxyl radical, superoxide anion, free oxygen radicals (FOR), hydroperoxyl radical, and hydrogen peroxide. FORs cause cell damage in the ischemic limb such as nitric oxide (NO) overproduction and their participation in the bloodstream causes. FORs accumulation during fracture healing reaches the maximum level on the 15th day. At the same time, the inflammatory process is on the summit point. The increase of FORs levels negatively affects fracture healing [10]. As known as literature knowledge, gossypin protects many tissues from the effects of FORs [9,11]. On the other hand, gossypin may be important because of the abrogation of osteoclastogenesis in the bone fracture healing process [12].

In rat and mouse fracture models, many studies were performed to study out the healing process in bone fracture healing [10]. Recently, mice and rats have become popular as transgenic models for bone fracture healing studies. These models have the available tools for molecular analysis [9]. In the literature, there are some studies about bone fracture healing in rats and rabbits related to biocompatibility and experimental bone defects [13,14]. But, there is no study about the effects of gossypin in mice with femur fracture as a mechano-bioregulatory model.

In our study, mice were the correct choice as a mechano-bioregulatory model to investigate the effects of gossypin on the bone fracture healing process. This paper aims to search the possible effects of gossypin as a new alternative agent for bone fracture healing because of its antioxidant, anti-inflammatory, analgesic effects. We used radiological, biomechanical, histopathological, and biochemical examination methods to detect the healing effects of gossypin in the experimental femur fracture model of mice.

MATERIAL AND METHODS

Ethical Approval

The study with Kafkas University Animal Experiments Local Ethics Committee approval (dated 25.06.2019, with the decision no: 2019/96) was conducted at the Kafkas University Experimental Animal Production and Research

Center. All steps of experimental procedures in this study were performed in line with the ethics committee protocols.

Experimental Animals and Creating Groups

A total of 28 male *Mus musculus* BALB/c mice (10-12 weeks, 31.7±3.4 g) were used in the study. During the experiment, mice were conserved in light and dark cycle (12 h/12 h; at 20-22°C), and the *ad libitum* feeding standard chow and normal tap water was performed in mice.

Four groups with 7 mice in each were randomly formed. Group 1 was the control group without any surgical or medical treatment. Group 2 was the femur fractured group of mice without any medical administration. Group 3 was the dose group of 5 mg/kg gossypin to mouse with femur fractures. Group 4 was the dose group of 10 mg/kg gossypin to mouse with femur fractures.

Chemicals

Gossypin (Biovision, USA) was dissolved in dimethyl-sulfoxide (DMSO, Amresco, Canada) and administered intraperitoneally. A 4.5 mg gossypin was dissolved with 16 mL DMSO (Dimethyl sulfoxide, Reagent Plus®, ≥99.5%, Sigma Aldrich).

Operative Technique

Anesthesia protocol was performed by intraperitoneal injection of 2% Xylazine (Rompun®, Bayer AG, Leverkusen, Germany) and 10% Ketamine (Ketalar®, Pfizer Inc., NY, USA) which provided approximately 20 min of deep anesthesia in mice. The surgical anesthesia of mice with 3-10 mg/kg Xylazine and 80-100 mg/kg Ketamine by using the intraperitoneal route of administration was performed [15]. The right femurs were scrubbed with a 10% povidone-iodine solution to prepare them for open femur fracture surgery. The dose adjustment for anesthesia and treatment was performed to pharmacological guidelines and studies about gossypin [15,16]. This group was opened with the help of a bistoury, and the all-right femur fracture was created with a bone cutter. A modification of the method by Manigrasso et al. [17] with a 3-point bending, the device was used for the experimental model. Antibiotic prophylaxis from surgery 30 min ago intramuscular 5 mg/kg cefazolin sodium and an additional dose at the 8th h postoperatively antibiotic prophylaxis was terminated. An open fracture model was created in the right femur of the animals with a 3 cm incision in Groups 2, 3, and 4. The medullary femoral channel was carved and reamerized with a 21 gauge needle. 0.8 mm stainless steel wire (TST, Turkey) was inserted into the canal to obtain a reduction of the fracture. All fractured femurs were reduced by intramedullary methods. By bending the wire proximal part was cut and the patella was reduced and the incisions were sutured. The mice were kept in the supine position at 24°C room temperature in the heating blanket. After the operation, 1-2 mL 0.9% NaCl isotonic solution was

Research Article

given to animals intraperitoneally to prevent dehydration. Intramuscular narcotics (Buprenorphine 1 mg/kg) were given for controlling the postoperative pain. Desai et al.^[18] showed that buprenorphine did not affect bone fracture healing.

Postoperative Period

For mice in all groups, X-rays were taken on the 1st day and the end of 6th and 12th weeks after osteotomy and bone formation in the osteotomy area was evaluated by Lane and Sandhu^[19] radiological evaluation system. It is shown in *Table 1*.

Gossypin Application

The basic solution was given by gavage with 18-22 gauge tubes generally in mice from Group 3 and Group 4, with smaller tubes (higher gauge) used for smaller mice with doses. After the operation, gossypin was given to each group for 4 weeks by the doses in the literature. At the end of the study, femur bone tissues in all groups were taken for necessary analyses.

Sample Collection

The mice sacrifice was a continued method of euthanasia, such as cervical dislocation. After the sacrifice blood samples were obtained from all mice for biochemical and PCR tests. Biomechanical tests were performed as soon as the animals were sacrificed. All operated right femurs were cleared from soft tissues and they were stored at -20°C. Tissue sampling was then performed for histo-pathological examinations. The femur bone tissues were placed in a 10% formaldehyde solution for histo-pathological examinations and the other was preserved at -80°C. The samples of right femurs were collected with fixation in 10% formaldehyde

in neutral buffered formalin for 48 h, 10% formic in 0.1 M citrate for decalcification kept in acid for 12 h. After the decalcification process longitudinal sections were taken from the femur. Paraffin blocks of samples were created. 5 µm sections were taken. The deparaffinization and then rehydration procedures were performed. Hematoxylin-Eosin (H&E) staining protocol was used for all sections. And these sections were examined by blinded two histologists by the light microscope (Olympus Bx43). The histopathological images were taken using a digital camera (Olympus DP21). Grading of Femur Bone Fracture Healing [size of chondrocytes (mm²) values, trabecular area (percent) values, and trabecular thickness (µm) values] were made.

Determination of Biomechanical Features

Biomechanical evaluations were made with three points bending machine (Hounsfield H50KM Surrey, UK). Femur samples, after the removal of intramedullary wires, were placed on the tip of the applicator of the machine. Two mm/min constant speed fracture healing site, to form a fracture again force applied. The broken force as Newton/m² was recorded as a unit. After intramedullary wires were removed, femur specimens were placed on the machine towards the end of the force applicator. 2 mm/min constant speed was applied to the fracture healing area to re-form a new fracture. The level for re-fracture force was recorded as a Newton unit. Hardness grade scores were created based on breaking strength (N) and hardness (N/mm).

Histo-pathological Examination

Histo-pathological examination obtained from the fracture line callus area 5 µm thick paraffin sections were prepared. It was stained using the H&E staining protocol for histological examinations. Light microscopy was used for evaluation. Histological evaluation was made according to the histologic evaluation system of Huddleston et al.'s method^[20]. The H&E staining method was used to determine the damage levels. According to this method, some criteria were used: Size of Chondrocytes (SOC) (mm²) is a definition based on measuring the area occupied by fibrocyte cells at the fracture site. The definition of Trabecular Area (TA) (percent) values described the trabecular microstructure formed during callus tissue formation in the union region. The definition of Trabecular Thickness (TT) (µm) values define the measurable thickness of the trabecular microstructure formed during callus tissue formation at the union site. The number of chondrocytes (NOC) definition signed the measurable number of the chondrocytes formed during callus tissue formation at the union site.

Biochemical Tests

Superoxide dismutase (SOD), Glutathione (GSH), and Malondialdehyde (MDA) levels were measured with blood serum samples of mice. The linear GSH, MDA, and SOD concentrations were determined according to the standard

Table 1. Radiological Evaluation System for mechano-bioregulatory femur fracture healing model of mouse

Evaluation	Score
Bone Formation	
Bone formation loss	0
Bone formation (filling of 25% in defect)	1
Bone formation (filling of 50% in defect)	2
Bone formation (filling of 75% in defect)	3
Bone formation (filling of 100% in defect)	4
Bone Union	
Bone non-union	0
Bone union (initiation)	1
Complete radiological bone union	2
Remodeling	
Lack of remodeling	0
Intramedullary canal formation	1
Cortical formation	2

equation as expressed in nmol/mg, nmol/mg, and U/mg, respectively. The values of mean±standard deviation (SD) were obtained. The analytical grade from Sigma-Aldrich (Germany) was used for all measurements.

PCR Tests for TNF- α and IL-1 β

TNF- α and IL-1 β analyses were performed (Step One Plus Real-Time PCR System, Applied Biosystems; Primer Design Ltd., Southampton, UK). The relative expression analyses of TNF- α and IL-1 β were performed using cDNA synthesized from the blood serum of mice. The plates were heated in suitable conditions.

Statistical Analysis

Statistical studies were performed by SPSS 22.0 program (Windows). Using the One-Way ANOVA method for statistical analysis, p values under 0.05 were considered statistically significant. Databases were expressed as values in mean ± standard deviation. Continuous variables used in the study Kolmogorov Since it shows normal distribution according to the Smirnov test one-way comparisons between 4 groups variance analysis (ANOVA) was used. Between groups in binary comparisons, variance homogeneity Sheffe and Tamhane tests were used. Continuous variables with arithmetic mean and the standard deviation was expressed. Less than 0.05 in statistical evaluation p values were considered significant. SPSS (Windows, IL, USA) software package was used. The statistical analyzes for the histological examination, Descriptive statistics for numeric variables median, minimum-maximum values were measured. Due to the sample number being less than 30, normality analysis was not performed and non-parametric test procedures were conducted directly. In this context, Kruskal-Wallis Variance Analysis, which is a nonparametric alternative to One-Way Variance Analysis was used to determine relationships between parameters. Dunn's test was used in post hoc analysis. The statistical results were interpreted in a 95% confidence interval. P values were considered as statistically significant under 0.05.

RESULTS

This experimental study was completed with a total of 28 mice. Radiographic, biomechanical, histopathological, biochemical, molecular results were collected.

Radiographic Results

In the radiological evaluation on the postoperative 1st day, 6th week, and 12th week, all bones in four groups were evaluated according to the radiologic evaluation system of Lane and Sandhu. In the 6th week, average radiologic evaluation scores performed between groups showed significant differences as statistically ($P < 0.05$). Scheffe test was used to determine significance between Groups 3 and 4. It had a higher statistical difference between these dose

groups ($P < 0.05$). Between the other two groups (Group 2 and 3; Group 2 and 4), there was a difference ($P < 0.05$ and $P < 0.05$). They were shown in Table 2 and Fig. 1, Fig. 2, Fig. 3.

Biomechanical Tests and Results

When the maximum braking forces were comparing, the peak values were detected in Group 1. The deep values were detected in Group 2. The braking force levels from the lowest to the highest were put in order. The order was as follows: Group 2 < Group 3 < Group 4 < Group 1. The differences in groups were significant ($P < 0.05$). Hardness grade scores were higher in Group 3 and 4 than Group 2 ($P < 0.001$). The lowest level of Hardness grade scores was detected in Group 2, and the highest level in Group 1. It was shown in Table 3.

Histo-pathological Results

In the histopathological examination of Groups 2, 3, 4;

Groups	Radiology Score (mean±SD)
Group 2 (*ff+*abs. of med.)	6.6±0.43
Group 3 (5 mg/kg gossypin)	8.9±0.69
Group 4 (10 mg/kg gossypin)	9.1±0.48
p	0.036
ANOVA test	p<0.05

*ff: femur fracture, abs. of med.: absence of medication

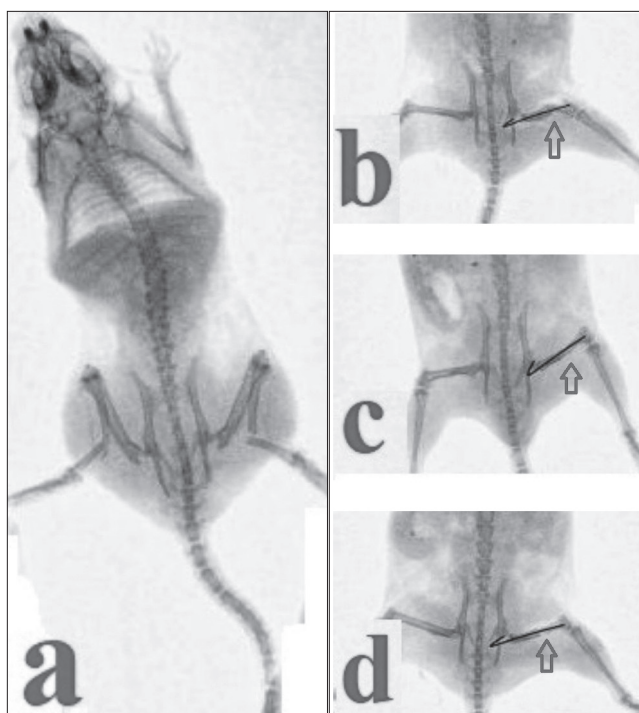


Fig 1. Postoperative 1st day X-rays of right femurs of mice in study groups

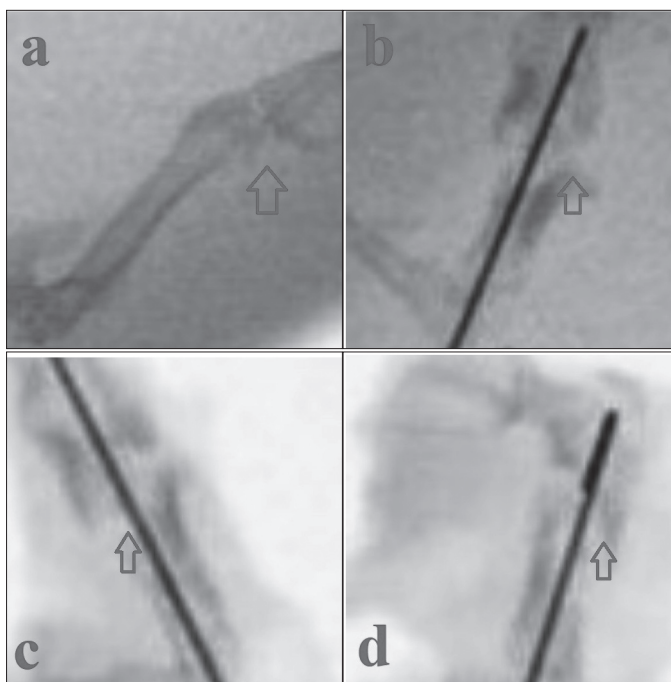


Fig 2. Postoperative 6th week X-rays of right femurs of mice in study groups

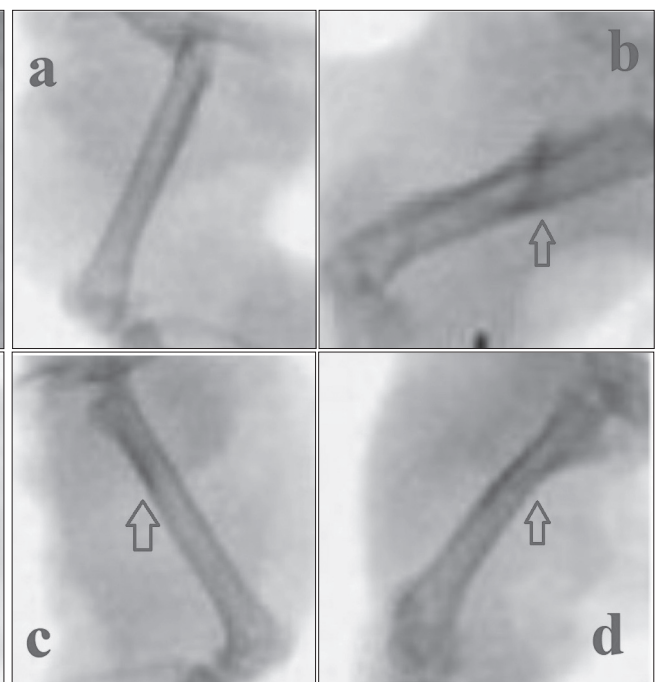


Fig 3. Postoperative 12th week X-rays of right femurs of mice in study groups

Table 3. Biomechanical tests results of mechano-bioregulatory femur fracture healing model of mouse

Group	Count	Braking Force (N)	Hardness (N/mm)
Group 1 (control group)	7	22.1±12.3	51.8±74.8
Group 2 (*ff+*abs. of med.)	7	11.2±8.7	15.7±11.7
Group 3 (5 mg/kg gossypin)	7	18.3±9.6	47.2±19.7
Group 4 (10 mg/kg gossypin)	7	19.2±12.3	49.3±20.1
Significance		P<0.05	P<0.001

*ff: femur fracture, abs. of med.: absence of medication

the fracture lines were rich with osteoblasts, common neo-vascularization images, and mature compact bone islets. In Groups 3 and 4, the predominance of the fracture site hyaline cartilage tissue rich healing tissue, mature compact in areas adjacent to hyaline cartilage bone tissue sites were located. The osteoblastic activity was observed to be more intense in Groups 3, 4 comparing to Group 2. In Group 2, compact bone healing was watched in which osteo-blastic activity is weaker. They were shown in Table 4. In Fig. 4, it is shown that the staining of the groups by the H&E method. Differences and similarities between the groups have been expressed in various symbols.

In the histological examination, groups were found significant differences statistically in the sixth week in terms of scores, in favor of Group 3 and 4 ($P<0.05$). From which group of differences Scheffe test was used to determine if it was caused. The mean scores of Group 3 and Group 4 were higher than Group 1 and Group 2 statistically ($P=0.001$, $P=0.002$, $P=0.21$, $P=0.34$).

Since the sample size was below 28, nonparametric Kruskal-

Wallis Variance analysis was used. The relationship between the SOC value and the groups and whether this relationship was significant or not was examined. According to the test results, there is a significant relationship between the SOC value and the Groups ($0.022<0.05$). "Dunn's Test" was used to examine the parameters of this significant relationship. According to this; there is a significant difference in terms of SOC values between Group 2 and Group 3 in favor of Group 3 ($0.017<0.05$). There is a significant difference in terms of SOC values between Group 2 and Group 4 in favor of Group 4 ($0.012<0.05$). A significant difference was not found in terms of SOC values between Group 3 and Group 4 ($0.608\geq 0.05$).

The relationship between the groups with TA per value and whether this relationship was significant or not was examined. According to the test results, there is a significant relationship between the TA per value and the Groups ($0.003<0.05$). "Dunn's Test" was used to examine the parameters of this significant relationship. According to this; there is a significant difference in terms of TA per values between Group 2 and Group 3 in favor of Group 3

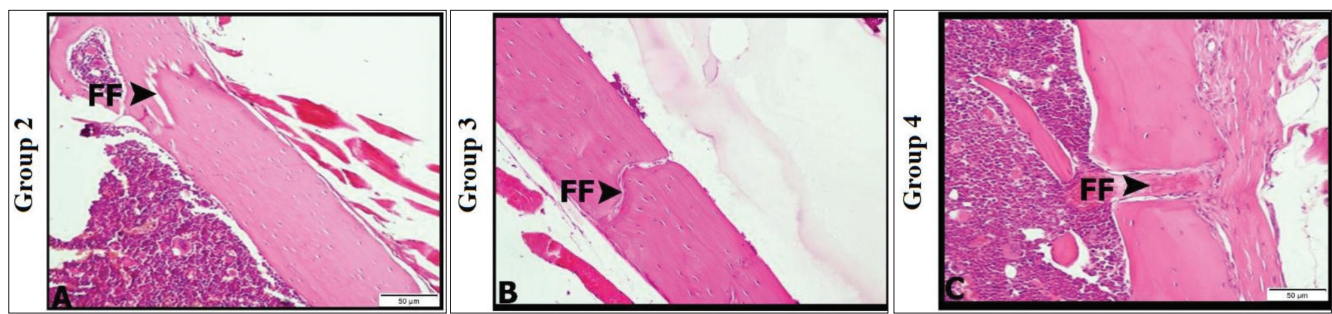


Fig 4. Histological samples from groups on femur fracture healing of mice

Table 4. Histological evaluation score results of mechano-bioregulatory femur fracture healing model of mouse

Groups	6 th -week Histological Score
Group 2 (*ff+*abs. of med.)	6.3±0.47
Group 3 (5 mg/kg gossypin)	7.6±0.53
Group 4 (10 mg/kg gossypin)	8.1±0.23
P	0.001
ANOVA test	P<0.001

*ff: femur fracture, abs. of med.: absence of medication

(0.003<0.05). There is a significant difference in terms of TT values between Group 2 and Group 4 in favor of Group 4 (0.03<0.05). A significant difference was not found in terms of TT values between Group 3 and Group 4 (0.537≥0.05).

Biochemical Test Results

In Group 3 and 4, at both dose groups, GSH had higher levels (P<0.05). GSH levels were lesser in Group 2 than in Group 1 (P<0.05). MDA levels were higher in three groups with femur fractures than in the control group. MDA levels were detected low in Groups 3 and 4 (P<0.05). SOD levels

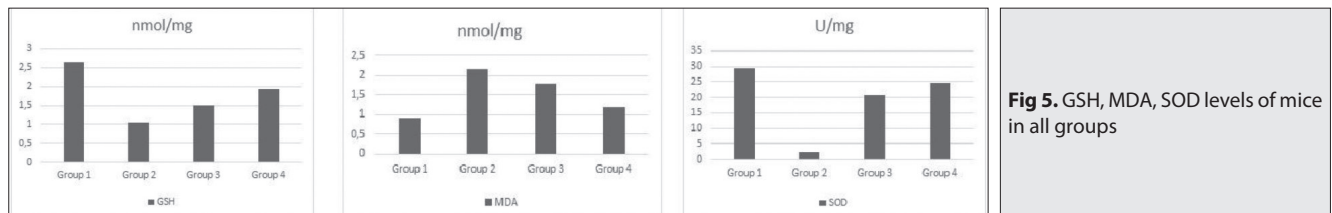


Fig 5. GSH, MDA, SOD levels of mice in all groups

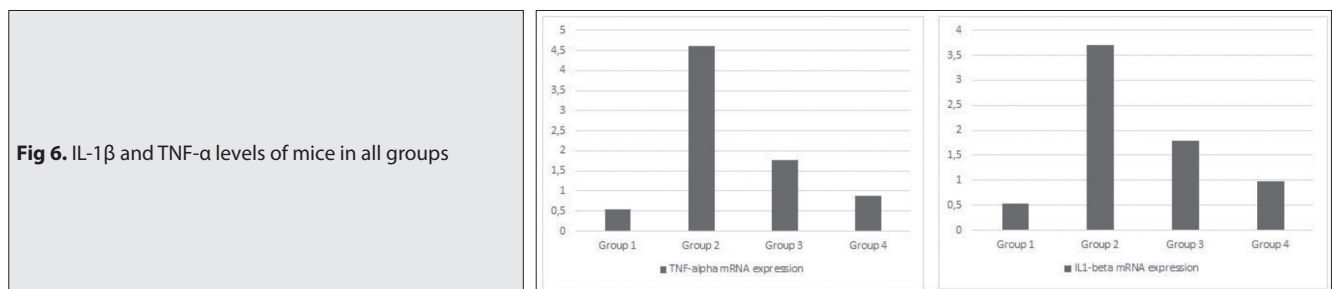


Fig 6. IL-1β and TNF-α levels of mice in all groups

(0.013<0.05). There is a significant difference in terms of TA per values between Group 2 and Group 4 in favor of Group 4 (0.002<0.05). A significant difference was not found in terms of TA per values between Group 3 and Group 4 (0.169≥0.05).

The relationship between the values and the groups with TT per value and whether this relationship was significant or not was examined. According to the test results, there is a significant relationship between the values and the groups (0.004<0.05). “Dunn’s Test” was used to examine the parameters of this significant relationship. According to this; there is a significant difference in terms of TT values between Group 2 and Group 3 in favor of Group 3

were in a dose-dependent manner. SOD activity was lower in Group 1 comparing to the control group (P<0.05). It was shown in Fig. 5.

Results of PCR Tests

TNF-α and IL-1β mRNA expressions were found to increase in Group 2 comparing to Group 1 (P<0.05). In Group 3 and 4, gossypin reduced TNF-α and IL-1β mRNA expressions in comparison to Group 2 (P<0.05). It was shown in Fig. 6.

DISCUSSION

The orthopedic researches to find the optimal model for human bone diseases determined that the reproducible

animal models were an effective choice [21]. Lu et al. [22] researched the tibia fractures in rats. The study was aimed to detect the fracture healing process in non-stabilized and stabilized conditions. 10-14 weeks-old, male rats were used in the study. The ischemia was induced by femoral artery resection in mice. They found three important results: i) ischemic conditions in fractures led to a delayed union or a nonunion, ii) formation of cartilage over bone is not related to this condition, iii) this model was suitable to test new therapeutic regimens in fracture healing [22]. Terjesen [23] studied a rabbit tibia fracture model to evaluate bone healing after external fixation of rabbit tibial osteotomies. The various groups were created according to different periods for removal of external fixation and sacrifice. The optimum time for removal of external fixation was found as 6 weeks [23]. Recently, the small animal models are becoming favorable to make a study in some clinical conditions like vascularization and ischemia on fracture healing. Mouse models, one of the small animals, are special for studying metaphyseal bone fracture healing in osteoporotic conditions [21]. As the number of animal species studied in bone fracture models increases, the chance of testing environmental and internal factors affecting the fracture increases accordingly [24]. The mice have some advantages for the animal bone fracture modeling as listed: 1) easy handling, 2) low husbandry costs, 3) short reproductive cycle, 4) transgenic features, 5) specific analytic tools; monoclonal antibodies, antigens [25]. Also, human and mouse genomes have similar orthologs/homologs genes. This feature makes this animal model is appropriate for the process of human bone fracture healing. However, the bone structure and remodeling process are different from humans [26]. To obtain the most appropriate approach to the physio-pathological process of bone fracture healing in orthopedic practice, we used mice as the most appropriate model.

The mechano-regulatory models, bioregulatory models, and coupled mechano-bioregulatory models were studied in some papers to search the simulation of fracture healing outcomes [27]. Exploring the new models of the bone fracture healing process may help us to find new therapeutic drugs/agents that effective on this complex process. The mesenchymal progenitors and their accumulation in the fracture gap is the first step of the bone fracture healing. And then, the proliferation and differentiation into the osteoblastic cell lineage are the basic processes [28]. In the general view, ischemia, the impaired vascularization, osteoporosis, and complications with soft tissue injuries are real factors for the bone fracture healing process [21]. In the fracturing method, the classifications of the fracture line (metaphyseal or diaphyseal) affect the results of the union in some health problems (ovariectomized/estrogen depleted animal models) [24]. Our mechano-bioregulatory model was in full compliance to research the possible effects of gossypin in the bone fracture healing process of mice as a mechano-bioregulatory model.

In 2014, Erdem et al. [29] performed an experimental study on a rat bone fracture model to investigate the effects of melatonin and caffeic acid phenethyl ester (CAPE) antioxidant molecules against ischemic factors. At the end of the 6th week, two blinded observers evaluated the radiological parameters of rats and the mean in radiological scores. All radiological images were evaluated according to the rating system Lane and Sandhu [19]. Radiological findings of bone fracture union were detected in all experimental groups. The mean radiological scores had significant differences at the end of 6 weeks between groups statistically ($P < 0.05$). To determine the difference the score of the CAPE-ischemia group comparing to the ischemia-fracture group Scheffe test was statistically different significantly higher ($P < 0.05$). Other groups had no statistically significant differences between each other ($P > 0.05$) [29]. In our radiologic evaluation, on the postoperative 1st day, 6th week, and 12th week, all bones in four groups were evaluated according to the radiological evaluation system of Lane and Sandhu [19]. At the end of the 6th week, average radiological evaluation scores performed between groups showed significant differences statistically ($P < 0.05$). Scheffe test was used to determine significance between Groups 3 and 4. It had a higher statistical difference between these dose groups ($P < 0.05$). Between the other two groups (Group 2 and 3; Group 2 and 4), there was a difference ($P < 0.05$ and $P < 0.05$). In terms of radiological and histological results, gossypin showed a significant difference depending on the dose.

To gain an orthopedic approach, the biomechanical evaluation is made by some measurement components as stress, strain, loading, forcing, displacement, ultimate strength, fracture stiffness, and healing time. The three-point bending test (TTPT) is applied to measure biomechanical features of fracture healing [30]. Wang et al. made an overview of current computational healing models in a study. They discussed the limitations, solutions, and potentials of animal bone models. They presented three kinds of animal bone fracture models (mechano-regulatory models, bioregulatory models, and coupled mechano-bioregulatory models). They emphasized the multiscale models and the coupled mechano-bioregulatory models as new investigations on bone fracture healing. All these experimental studies will conduct optimum treatment strategies [27,29]. In our study, all biomechanical tests were started with TTPT. All biomechanical components as stress, strain, loading, forcing, displacement, ultimate strength, fracture stiffness, and healing time were evaluated for mice of all groups. Hardness grade scale was the highest level in groups with gossypin administration. The lowest level was in Group 2 without any gossypin medication. According to biomechanical tests, gossypin yielded significant results depending on the dose. Biomechanical tests in this mechano-bioregulatory model showed that gossypin provided enough hardness levels, and high thresholds in braking forces.

Erdem et al.^[29] used the method of Huddleston et al.^[20] as a histological evaluation system in their rat bone fracture model. At the end of 6 weeks, in terms of scores, a statistically significant difference was found between groups ($P < 0.05$). They performed Scheffe test to determine which group differs from others. The mean in scores of fracture group ($p = 0.002$), melatonin-ischemia group ($P = 0.021$), CAPE-ischemia group ($P = 0.001$) was found statistically higher than the mean score of the ischemia-fracture group. At the fracture line of these groups, there are full images of the osteoblasts and neo-vascularity with the mature bone islets. In the fracture-ischemia group, the fracture site is predominantly full of healing tissues rich in hyaline cartilage tissue and mature compact in areas adjacent to the hyaline cartilage bone tissue areas. Especially, the fracture group and the CAPE-ischemia group had more intense osteoblastic activity. In the fracture-ischemia group, compact bone with weaker osteoblastic activity recovery was observed^[29]. As the result of our histo-pathological studies, there is a significant relationship between the SOC values and groups. There is a significant relationship between the groups with TA per value. There is a significant relationship between the values of the TT and groups. A significant difference was not found between groups in terms of NOC values. There is a significant relationship between the SOC value and groups. There is a significant relationship between the groups with TA per value. There is a significant relationship between the values of the TT and groups. A significant difference was not found between groups in terms of NOC values. At the evaluation of SOC, TA, and TT; gossypin showed a healing effect in a dose-dependent manner. There were no statistical differences between groups in terms of the NOC.

The antioxidant effects of gossypin have been demonstrated in publications published in 1998^[31], 2004^[8], 2007^[9], 2017^[32], and 2020^[11]. In 1998^[31], Jornot et al.^[31] showed potent antioxidant and free radical scavenging effects of gossypin in different *in-vitro* studies. According to Yoon et al.^[8], gossypin inhibited oxidative stress- and A β (25-35)-induced toxicity. Also, it inhibited lipid peroxidation and scavenge DPPH radicals. Gossypin inhibited the toxicity induced by X/XO, in this study^[8]. Ganapaty et al.^[8] demonstrated gossypin and BHT inhibited free radical-mediated deoxyribose damage. Antioxidant activity of gossypin was investigated as good antioxidant activity levels at the tested concentrations. Also, gossypin had enough *in-vitro* lipid peroxidation inhibitory potential^[32]. The oxidative stress-induced hydrogen peroxide (H_2O_2) is used commonly to show the antioxidant activity in cells. In the L929 cells, the oxidative stress levels induced by H_2O_2 were evaluated for gossypin. The antioxidative capacity was decreased, increased levels of MDA, and the lower levels of SOD were determined. The doses groups of 25 ve 50 $\mu\text{g}/\text{mL}$ gossypin increased the antioxidative activity but decreased the levels of MDA. Especially, the levels of SOD in the 50 $\mu\text{g}/\text{mL}$ dose group were higher than in the

H_2O_2 group. These effects may be related to the alterations of ROS (reactive oxygen species) by gossypin in L929 cells. Gossypin's protective effects include two factors: free radical scavenging activities and some signals by the genes related to antioxidant and anti-inflammatory biomolecules^[11]. In our study, Groups 3 and 4, at both dose groups, GSH had higher levels ($P < 0.05$). GSH levels were lesser in Group 2 than in Group 1 ($P < 0.05$). MDA levels were higher in three groups with femur fractures than in the control group. MDA levels were detected low in Groups 3 and 4 ($P < 0.05$). SOD levels were in a dose-dependent manner. SOD activity was lower in Group 1 comparing to the control group ($P < 0.05$). Considering the SOD, MDA, and GSH values, we found that gossypin showed an antioxidant effect depending on the dose. Gossypin had sufficient antioxidant and anti-inflammatory effects in mice with femur fracture in bone healing.

As an injury, bone fracture creates an inflammatory response. It reaches to peak on the first day^[33,34]. At this time, neutrophils reached the inflammatory area. Acute inflammation and hematoma have critical roles in fracture healing^[35,36]. The hematoma followed acute inflammation^[33,37,38]. Suppressed or dysregulated response elicits chronic inflammation that may be detrimental to fracture healing. TNF- α , IL-1 β , IL-6, and CCL2 are pro-inflammatory cytokines and they were secreted by macrophages. The alterations in the levels of pro-inflammatory molecules have major effects. After the bone fracture, TNF- α and IL-1 β reach two times to peaks (at 24 h and 3rd week) following the injury^[39]. They promote bone resorption by some activities of osteoclasts and/or osteoblasts. Chronic inflammation has an imbalance related to the formation and resorption of bone^[40]. TNF1 acts a pro-inflammatory and apoptotic role^[41,42]. Generally, TNF- α suppresses osteoblasts and stimulates osteoclast proliferation and differentiation^[43-45]. On the regulation of bone metabolism, TNF- α has some roles. TNF- α follows a biphasic pattern with its receptors, TNFR1 and TNFR2. By the functions of TNFR1 and TNFR2, TNF- α regulates osteogenic cells. TNFR1 is seen in the bone. The expression of TNFR2 followed the bone injury. TNF- α has some paradoxical effects on osteogenesis and bone formation-related MSCs. By the way, as an acute-phase protein after trauma, TNF- α can initiate blood clotting^[46]. As a pro-inflammatory cytokine, IL1b takes charge in cell proliferation, differentiation, and apoptosis. IL-1 has similar effects with TNF- α . IL-1 gets a role in the callogenesis and angiogenesis with roles of IL-6 in osteoblasts. Even if IL-1 exists, fracture healing is not affected adversely. IL-1 has a biphasic pattern in the expression phase and its source is macrophages, like TNF- α . In a study, TNF- α and IL-1 β inhibit NaBu-induced IAP (intestinal alkaline phosphatase) gene expression. Pro-inflammatory molecules have infamous features with high circulating levels of TNF- α and IL-1 is linked to joint and bone destruction^[47,48]. In our experimental study, the results had compliance with the

Research Article

literature. When looking at IL-1 β and TNF- α levels, gossypin affected the recovery with its anti-inflammatory effects by inhibiting the chronic inflammation procedure.

The new pharmaceutical agents can develop the regimen for the healing process of human bone. Klontzas et al.^[24] searched some keywords as fracture, drugs, bone, and healing in Medline and Scopus databases between 2010 and 2016. 5310 results were found. Investigational drugs for fracture healing can be listed as anti-osteoporotic drugs (Bi-phosphonates), parathyroid hormone (PTH), strontium ranelate, estrogens and selective estrogen receptor modulators (SERMS), sclerostin Ab&DKK-1 Ab, bonemorphogenetic proteins (BMPs), statins, antihypertensive drugs, lithium, proteasome inhibitors, melatonin, botulinum toxin, erythropoietin (EPO), sildenafil, sphingosine 1-phosphate receptor-targeted drugs, G-CSF (Granulocyte Colony Stimulating Factor), FGF (Fibroblast Growth Factor), VEGF (Vascular Endothelial Growth Factor), local vanadium. The TGF- β superfamily members as G-CSF, VEGF, FGF, BMPs, and other substances such as EPO were used to evaluate bone regeneration widely in the preclinical and clinical tests^[49-51].

The drugs used in the treatment of bone fracture healing aim to provide this in three ways as i) osteoblastic activity increasing, (indirectly progenitor cells that will mature to osteoblasts), ii) inhibiting of osteoclastic activity (favoring osteoblastic aspect of the process), or iii) by stimulating the vascularization of tissue. According to the results of our study, besides its antioxidant and anti-inflammatory effects, we can state that gossypin had therapeutic effects on bone fracture healing in the latter two ways, although the exact level of its effect on osteoblastic activity is not known, yet.

The mice have some advantages for animal bone fracture modeling as a mechano-bioregulatory model in full compliance with the human bone fracture healing model. The studies in mechano-bioregulatory models may be performed with mice. We recommended the use of gossypin in the treatment of bone fracture healing with its antioxidant, analgesic, and anti-inflammatory effects with the trinity effects of osteoblastic activity, inhibiting of osteoclastic activity, stimulating the vascularization as bone fracture healer agents.

CONFLICTS OF INTEREST

The authors declare that they have no conflicts of interest.

FINANCIAL SUPPORT

There is no funding source.

AUTHOR CONTRIBUTIONS

KY: conceived and designed the analysis, collected the databases, contributed databases or analysis tools,

performed analysis, wrote the paper, other contribution; MFT: contributed databases or analysis tools, performed the analysis; VT: collected the databases, contributed databases or analysis tools (veterinary, biomechanical examinations), performed analysis, wrote the paper, other contribution; FB: collected the databases, contributed databases or analysis tools (biochemistry), performed analysis, wrote the paper, other contribution; SY: collected the databases, contributed databases or analysis tools (histological examination), performed analysis, wrote the paper, other contribution.

REFERENCES

- 1. Viswanathan S, Sambantham PT, Reddy K, Kameswaran L:** Gossypin-induced analgesia in mice. *Eur J Pharmacol*, 98 (2): 289-291, 1984. DOI: 10.1016/0014-2999(84)90604-6
- 2. Gautam P, Flora SJS:** Oral supplementation of gossypin during lead exposure protects alteration in the heme synthesis pathway and brain oxidative stress in rats. *Nutrition*, 26 (5): 563-570, 2010. DOI: 10.1016/j.nut.2009.06.008
- 3. Chandrashekhara VM, Ganapaty S, Ramkishan A, Narsu ML:** Neuroprotective activity of gossypin from *Hibiscus vitifolius* against global cerebral ischemia model in rats. *Indian J Pharmacol*, 45 (6): 575-580, 2013. DOI: 10.4103/0253-7613.121367
- 4. Cinar I, Sirin B, Aydin P, Toktay E, Cadirci E, Halici I, Halici Z:** Ameliorative effect of gossypin against acute lung injury in an experimental sepsis model of rats. *Life Sci*, 221, 327-334, 2019. DOI: 10.1016/j.lfs.2019.02.039
- 5. Katary M, Salahuddin A:** Ameliorative effect of gossypin against gentamicin-induced nephrotoxicity in rats. *Life Sci*, 176, 75-81, 2017. DOI: 10.1016/j.lfs.2017.03.009
- 6. Tanyeli A, Eraslan E, Güler MC, Kurt N, Akara N:** Gossypin protects against renal ischemia-reperfusion injury in rats. *Kafkas Univ Vet Fak Derg*, 26 (1): 89-96, 2020. DOI: 10.9775/kvfd.2019.22396
- 7. Parmar NS, Ghosh MN:** Effect of gossypin, a flavonoid, on the formation of galactose-induced cataracts in rats. *Exp Eye Res*, 29 (3): 229-232, 1979. DOI: 10.1016/0014-4835(79)90003-4
- 8. Yoon I, Lee KH, Cho J:** Gossypin protects primary cultured rat cortical cells from oxidative stress- and beta-amyloid-induced toxicity. *Arch Pharm Res*, 27 (4): 454-459, 2004. DOI: 10.1007/BF02980089
- 9. Ganapaty S, Chandrashekhara VM, Chitme HR, Lakshmi Narsu M:** Free radical scavenging activity of gossypin and nevoidensin: An *in-vitro* evaluation. *Indian J Pharmacol*, 39 (6): 281-283, 2007. DOI: 10.4103/0253-7613.39147
- 10. Göktürk E, Turgut A, Bayçu C, Günel I, Seber S, Gülbas Z:** Oxygen-free radicals impair fracture healing in rats. *Acta Orthop Scand*, 66, 473-475, 1995. DOI: 10.3109/17453679508995590
- 11. Cinar I:** L929 fibroblast hücrelerinde gossypin'in hidrojen peroksit hasarına karşı koruyucu etkilerinin değerlendirilmesi. *Kafkas J Med Sci*, 10 (1): 15-23, 2020. DOI: 10.5505/kjms.2020.06025
- 12. Kunnumakkara AB, Nair AS, Ahn KS, Pandey MK, Yi Z, Liu M, Aggarwal BB:** Gossypin, a pentahydroxy glucosyl flavone, inhibits the transforming growth factor beta-activated kinase-1-mediated NF-kappaB activation pathway, leading to potentiation of apoptosis, suppression of invasion, and abrogation of osteoclastogenesis. *Blood*, 109 (12): 5112-5121, 2007. DOI: 10.1182/blood-2007-01-067256
- 13. Devenci MZY, Gönenci R, Canpolat İ, Kanat Ö:** *In vivo* biocompatibility and fracture healing of hydroxyapatite-hexagonal boron nitride chitosan-collagen biocomposite coating in rats. *Turk J Vet Anim Sci*, 44 (1): 76-88, 2020. DOI: 10.3906/vet-1906-21
- 14. Uslucan L, Atalay B, Oral CK, Yildirim MS, Cankaya AB:** The histopathological effects of calcium triglyceride bone cement and chitosan on the healing of experimental bone defects. *Turk J Med Sci*, 48 (6): 1268-

1277, 2018. DOI: 10.3906/sag-1706-33

15. Adams S, Pacharinsak C: Mouse anesthesia and analgesia. *Curr Protoc Mouse Biol*, 5, 51-63, 2015. DOI: 10.1002/9780470942390.mo140179

16. Gargiulo S, Greco A, Gramanzini M, Esposito S, Affuso A, Brunetti A, Vesce G: Mice anesthesia, analgesia, and care, part I: Anesthetic considerations in preclinical research. *ILAR J*, 53 (1): E55-E69, 2012. DOI: 10.1093/ilar.53.1.55

17. Manigrasso MB, O'Connor JP: Characterization of a closed femur fracture model in mice. *J Orthop Trauma*, 18 (10): 687-695, 2004. DOI: 10.1097/00005131-200411000-00006

18. Desai SN, Badiger SV, Tokur SB, Naik PA: Safety and efficacy of transdermal buprenorphine versus oral tramadol for the treatment of post-operative pain following surgery for fractured neck of femur: A prospective, randomized clinical study. *Indian J Anaesth*, 61 (3): 225-229, 2017.

19. Lane JM, Sandhu HS: Current approaches to experimental bone grafting. *Orthop Clin North Am*, 18, 213-225, 1987.

20. Huddleston PM, Steckelberg JM, Hanssen AD, Rouse MS, Bolander ME, Patel R: Ciprofloxacin inhibition of experimental fracture healing. *J Bone Joint Surg Am*, 82, 161-173, 2000. DOI: 10.2106/00004623-200002000-00002

21. Haffner-Luntzer M, Hankenson KD, Ignatius A, Pfeifer R, Khader BA, Hildebrand F, van Griensven M, Pape HC, Lehmiche M: Review of Animal Models of Comorbidities in Fracture-Healing Research. *J Orthop Res*, 37 (12): 2491-2498, 2019. DOI: 10.1002/jor.24454

22. Lu C, Miclau T, Hu D, Marcucio RS: Ischemia leads to the delayed union during fracture healing: a mouse model. *J Orthop Res*, 25 (1): 51-61, 2007. DOI: 10.1002/jor.20264

23. Terjesen T: Healing of rabbit tibial fractures using external fixation. Effects of removal of the fixation device. *Acta Orthop Scand*, 55 (2): 192-196, 1984. DOI: 10.3109/17453678408992336

24. Klontzas ME, Kenanidis EI, MacFarlane RJ, Michail T, Potoupnis ME, Heliotis M, Mantalaris A, Tsiroidis E: Investigational drugs for fracture healing: Preclinical & clinical data. *Expert Opin Investig Drugs*, 25 (5): 585-596, 2016. DOI: 10.1517/13543784.2016.1161757

25. Hedrich H: The Laboratory Mouse. 117-656, Elsevier Academic Press. Burlington, MA. 2004.

26. Haffner-Luntzer M, Kovtun A, Rapp AE, Ignatius A: Mouse models in bone fracture healing research. *Curr Mol Biol Rep*, 2, 101-111, 2016. DOI: 10.1007/s40610-016-0037-3

27. Wang M, Yang N, Wang X: A review of computational models of bone fracture healing. *Med Biol Eng Comput*, 55 (11): 1895-1914, 2017. DOI: 10.1007/s11517-017-1701-3

28. Szczęśny G: Fracture healing and its disturbances: A literature review. *Ortop Traumatol Rehabil*, 17 (5): 437-454, 2015. DOI: 10.5604/15093492.1186809

29. Erdem M, Gulabi D, Asci M, Bostan B, Gunes T, Koseoglu R: Melatonin ve kafeik asit fenetil ester'in iskemik şartlarda kırık iyileşmesi üzerine etkisi: Deneysel çalışma. *Acta Orthop Traumatol Turc*, 48 (3): 339-345, 2014. DOI: 10.3944/AOTT.2014.3244

30. Jämsä T, Jalovaara P, Peng Z, Väänänen HK, Tuukkanen J: Comparison of three-point bending test and peripheral quantitative computed tomography analysis in the evaluation of the strength of mouse femur and tibia. *Bone*, 23 (2): 155-161, 1998. DOI: 10.1016/s8756-3282(98)00076-3

31. Jornot L, Petersen H, Junod AF: Hydrogen peroxide-induced DNA damage is independent of nuclear calcium but dependent on redox-active ions. *Biochem J*, 335, 85-94, 1998. DOI: 10.1042/bj3350085

32. Patel K, Kumar V, Verma A, Patel DK: Gossypin: A phytochemical of multispectrum potential. *J Coastal Life Med*, 5 (8): 365-370, 2017. DOI: 10.12980/jclm.5.2017J6-227

33. Kany S, Vollrath JT, Relja B: Cytokines in inflammatory disease. *Int J Mol Sci*, 20 (23):6008, 2019. DOI: 10.3390/ijms20236008

34. Giannoudis PV, Hak D, Sanders D, Donohoe E, Tosounidis T, Bahney C: Inflammation, bone healing, and anti-inflammatory drugs: An update. *J Orthop Trauma*, 29 (Suppl. 12): S6-S9, 2015. DOI: 10.1097/BOT.0000000000000465

35. Loi F, Córdova LA, Pajarinen J, Lin TH, Yao Z, Goodman SB: Inflammation, fracture and bone repair. *Bone*, 86, 119-130, 2016. DOI: 10.1016/j.bone.2016.02.020

36. Glass GE, Chan JK, Freidin A, Feldmann M, Horwood NJ, Nanchahal J: TNF- α promotes fracture repair by augmenting the recruitment and differentiation of muscle-derived stromal cells. *Proc Natl Acad Sci USA*, 108, 1585-1590, 2011. DOI: 10.1073/pnas.1018501108

37. Marsell R, Einhorn TA: The biology of fracture healing. *Injury*, 42, 551-555, 2011. DOI: 10.1016/j.injury.2011.03.031

38. Claes L, Recknagel S, Ignatius A: Fracture healing under healthy and inflammatory conditions. *Nat Rev Rheumatol*, 8, 133-143, 2012. DOI: 10.1038/nrrheum.2012.1

39. Tsiroidis E, Upadhyay N, Giannoudis PV: Molecular aspects of fracture healing: Which are the important molecules? *Injury*, 38, 11-25, 2007. DOI: 10.1016/j.injury.2007.02.006

40. Lacativa PG, Farias ML: Osteoporosis and inflammation. *Arg Bras Endocrinol Metab*, 54, 123-132, 2010. DOI: 10.1590/s0004-27302010000200007

41. Heir R, Stellwagen D: TNF-mediated homeostatic synaptic plasticity: From *in-vitro* to *in vivo* models. *Front Cell Neurosci*, 14:565841, 2020. DOI: 10.3389/fncel.2020.565841

42. Gough P, Myles IA: Tumor necrosis factor receptors: Pleiotropic signaling complexes and their differential effects. *Front Immunol*, 11:585880, 2020. DOI: 10.3389/fimmu.2020.585880

43. Wang T, He C: TNF- α and IL-6: The link between immune and bone system. *Curr Drug Targets*, 21 (3): 213-227, 2020. DOI: 10.2174/1389450120666190821161259

44. De Vries TJ, El Bakkali I, Kamradt T, Schett G, Jansen IDC, D'Amelio P: What are the peripheral blood determinants for increased osteoclast formation in the various inflammatory diseases associated with bone loss? *Front Immunol*, 10:505, 2019. DOI: 10.3389/fimmu.2019.00505

45. Tada M, Inui K, Sugioka Y, Mamoto K, Okano T, Anno S, Koike T: Use of bisphosphonate might be important to improve bone mineral density in patients with rheumatoid arthritis even under tight control: The TOMORROW study. *Rheumatol Int*, 37, 999-1005, 2017. DOI: 10.1007/s00296-017-3720-7

46. Reikeräs O, Borgen P: Activation of markers of inflammation, coagulation, and fibrinolysis in musculoskeletal trauma. *PLoS ONE*, 9:e107881, 2014. DOI: 10.1371/journal.pone.0107881

47. Mountziaris PM, Mikos AG: Modulation of the inflammatory response for enhanced bone tissue regeneration. *Tissue Eng Part B Rev*, 14 (2): 179-186, 2008. DOI: 10.1089/ten.teb.2008.0038

48. Lange J, Sapozhnikova A, Lu C, Hu D, Li X, Miclau T 3rd, Marcucio RS: Action of IL-1beta during fracture healing. *J Orthop Res*, 28 (6): 778-784, 2010. DOI: 10.1002/jor.21061

49. Kawaguchi H, Oka H, Jingushi S, Izumi T, Fukunaga M, Sato K, Matsushita T, Nakamura K, TESK Group: A local application of recombinant human fibroblast growth factor 2 for tibial shaft fractures: A randomized, placebo-controlled trial. *J Bone Miner Res*, 25, 2735-2743, 2010. DOI: 10.1002/jbmr.146

50. Garrison KR, Shemilt I, Donell S, Ryder JJ, Mugford M, Harvey I, Song F, Alt V: Bone morphogenetic protein (BMP) for fracture healing in adults. *Cochrane Database Syst Rev*, 2010 (6): CD006950, 2010. DOI: 10.1002/14651858.CD006950.pub2

51. Ishida K, Matsumoto T, Sasaki K, Mifune Y, Tei K, Kubo S, Matsushita T, Takayama K, Akisue T, Tabata Y, Kurosaka M, Kuroda R: Bone regeneration properties of granulocyte colony-stimulating factor via neovascularization and osteogenesis. *Tissue Eng Part A*, 16, 3271-3284, 2010. DOI: 10.1089/ten.tea.2009.0268