

# Inducible Nitric Oxide Synthase (iNOS) Enzyme Activity and Transcription Level as Well as Ultrastructural Changes in Different Tissues of Grass Carp in Response to *Ichthyophthirius multifiliis*

Yingjie LU<sup>1</sup> Shuwen TAN<sup>1</sup> Bingqing O<sup>1</sup> Xiwen ZHANG<sup>2</sup>  
Ying YANG<sup>1</sup> Shujian HUANG<sup>1</sup>✍ Saeed EL-ASHRAM<sup>1,3,a</sup>✍

<sup>1</sup> College of Life Science and Engineering, Foshan University, 18 Jiangwan Street, Foshan TR-528231 Guangdong Province, CHINA

<sup>2</sup> The University of Georgia, Athens, USA

<sup>3</sup> Kafrelsheikh University, Kafr el-Sheikh, 33516, EGYPT

<sup>a</sup> ORCID: 0000-0003-0389-1980

Article ID: KVFD-2018-21084 Received: 02.10.2018 Accepted: 20.03.2019 Published Online: 24.03.2019

## How to Cite This Article

Lu Y, Tan S, O B, Zhang X, Yang Y, Huang S, El-Ashram S: Inducible nitric oxide synthase (iNOS) enzyme activity and transcription level as well as ultrastructural changes in different tissues of grass carp in response to *Ichthyophthirius multifiliis*. *Kafkas Univ Vet Fak Derg*, 25 (4): 459-466, 2019. DOI: 10.9775/kvfd.2018.21084

## Abstract

This study aims to contribute to this growing area of research by exploring the gene expression and enzyme activity of iNOS, and provide new insights into the ultrastructural changes in the kidneys, spleen, skin and gills infected with *Ichthyophthirius* on grass carp. Furthermore, electron microscopy (EM) findings illustrated the uneven distribution of the macrophages and lymphocytes, and the concentrated and fragmented and/or disappeared cell nuclei in the kidneys, spleen, gills and skin. The extreme ultrastructural changes resulted in the reduction in the number of immune cells and subsequent downregulation of iNOS enzyme activity, especially in the gills and skin of *Ichthyophthirius*-infected grass carp. Our results showed that enzyme activity and gene expression of iNOS were significantly down-regulated in the kidneys and spleen ( $P>0.05$ ), gills and skin ( $P<0.05$ ) compared with the negative control group. The data showed the different levels of damages against *I. multifiliis* infection in the kidneys, spleen, gills and skin. Taken together, expression and activity of inducible nitric oxide synthase could serve as an important indicator to determine the pathological status of the *I. multifiliis*-grass carp.

**Keywords:** *Ichthyophthirius multifiliis*, Gene expression, Enzyme activity *Ctenopharyngodon idella* iNOS, Ultrastructural changes

## *Ichthyophthirius multifiliis*'e Karşı Çim Sazanının Farklı Dokularında İndüklenebilir Nitrik Oksit Sentaz (iNOS) Enzim Aktivitesi, Transkripsiyon Seviyesi ve Ultrastrüktürel Değişiklikler

## Öz

Bu çalışma *Ichthyophthirius* ile enfekte edilmiş Çim sazanının böbrek, dalak, deri ve kuluçkasında meydana gelen ultrastrüktürel değişiklikler ile iNOS enzim aktivitesi ve gen ekspresyonunu araştırmak suretiyle katkıda bulunmayı amaçlamaktadır. Böbrek, dalak, solungaç ve deride elektron mikroskopi bulguları makrofaj ve lenfositlerin dengesiz dağılımı ile konsantrasyon ve parçalanmış ve/veya gözden kaybolmuş çekirdeğin olduğunu göstermiştir. *Ichthyophthirius* ile enfekte Çim sazanının özellikle solungaç ve derisinde aşırı ultrastrüktürel değişiklikler, immun hücrelerin sayısında azalma ve sonrasında iNOS enzim aktivitesinde aşağı yönde ayarlanma ile sonuçlandı. Elde edilen sonuçlar, iNOS enzim aktivitesi ve gen ekspresyonunun negatif kontrol grubu ile karşılaştırıldığında böbrek ve dalakta anlamlı derecede ( $P>0.05$ ), solungaçlarda ve deride ( $P<0.05$ ) aşağı yönde ayarlandığını gösterdi. Elde edilen veriler *I. multifiliis* enfeksiyonuna karşı böbrek, dalak, solungaç ve deride farklı derecelerde hasarların oluştuğunu göstermiştir. *I. multifiliis* ile enfekte Çim sazanında patolojik durumun belirlenmesinde indüklenebilir nitrik oksit sentaz gen ekspresyonu ve enzim aktivitesi bir belirteç olarak kullanılabilir.

**Anahtar sözcükler:** *Ichthyophthirius multifiliis*, Gen ekspresyonu, *Ctenopharyngodon idella* iNOS Enzim aktivitesi, Ultrastrüktürel değişiklikler



## İletişim (Correspondence)



+86-18620403131; Fax: +86-757-85505013



[huangshujian@fosu.edu.cn](mailto:huangshujian@fosu.edu.cn) (S. Huang); [saeed\\_elashram@yahoo.com](mailto:saeed_elashram@yahoo.com) (S. El-Ashram)

## INTRODUCTION

*Ichthyophthirius multifiliis*, ciliated protozoan that causes "Ich" or "white spot disease" is a major burden for fish farmers and aquarists world-wide. The parasite has been detected globally in both cultured and wild fish, and all species of freshwater fish are considered susceptible. Ich has both host life stage, such as trophont and environmental life stages, such as tomont, tomite and theront. *I. multifiliis* causes remarkable economic losses in all freshwater fish, resulting in huge mortalities [1,2]. The grass carp (*Ctenopharyngodon idellus*) is one of the major kinds of freshwater fish cultured in China, belonging to family *Cyprinidae*. Interest in grass carp as a food has emerged throughout the world because of their delicious and unique flavor. Grass carp has become an attractive food source, with good economic potential and high commercial interest in China. In recent years, the production of the grass carp has decreased due to infection of *I. multifiliis*. Our research group has reported the up-regulation of *MHII-DAB* gene in spleen, gills and skin, and cell degeneration and necrosis are observed immune and other related tissues of *Ichthyophthirius*-infected grass carp [3]. Subsequent studies have recorded the marked upregulation of superoxide dismutase (SOD) in the spleen, liver and muscle tissue of *Ichthyophthirius*-infected grass carp with mechanical damages of different tissues as well as mitochondrial damages [4]. Nitric oxide (NO) is a significant biologically active molecule that plays a key part in host defense against microbial infections. NO is formed by the nitric oxide synthase (NOS), which is one of the important immune regulatory factors [5-7]. There are three NOS isoforms, endothelial constitutive NOS (ecNOS), neuronal NOS (nNOS), and inducible NOS (iNOS) [8,9]. iNOS is expressed in many cell types, including macrophages, neutrophils and fibroblasts in response to a range of immunological stimuli, such as cytokines and lipopolysaccharide (LPS). It has dual roles as a critical agent of host defense in infection and as a central mediator of pathogenesis [10,11]. Very little is known about iNOS enzyme activity and gene expression level as well as pathologic and ultrastructural changes in different tissues of the *Ichthyophthirius*-infected grass carp. Therefore, the present study fills a gap in the literature by studying the gene expression and enzyme activity of iNOS, and providing new insights into the ultrastructural changes in the kidneys, spleen, skin and gills of the *Ichthyophthirius*-infected grass carp.

## MATERIAL and METHODS

### Ethics Statement

This study was approved by the Animal Ethics Committee of the College of life science and engineering, Foshan University, Guangdong, China. The College did not issue a number or ID to this animal study, because the studied fish are not an endangered or protected species. Specimen

collection was carried out based upon the protocol issued by the Animal Ethics Committee of the College of life science and engineering. Furthermore, all methods were performed in accordance with the relevant guidelines and regulations

### Parasite

Laboratory cultures of *I. multifiliis* obtained from a fish farm (Guangzhou, Guangdong province, China) which was maintained at 20°C by serial passage in grass carp (*Ctenopharyngodon idella*) [12].

### Fish and Exposure to *Ichthyophthirius* Infection

Grass carp (*C. idellus*), weighing 40±2 g, was obtained from the Holdone Aquaculture Breeding Limited Company. The fish were acclimatized for one week before infection experiments initiated. A total of 100 fish were randomly divided into four groups at a density of 25 fish per each group. Fish were fed once at a level of 1% average fish weight per meal daily with a commercial fish pellet feed, manufactured by the Institute of Hydrobiology, Chinese Academy of Sciences. Three groups were infected by *I. multifiliis*, and the 4<sup>th</sup> group is negative control (uninfected grass carp). Fish were infected with a high dose of live trophont (immersion) in the dark for 8 h. At 4 to 6 days after infection (after some trial runs, we decided to set up the experiments at 4 to 6 days to avoid grass carp death) at 21±2°C, pH 7.0, with dissolved oxygen 6.0-7.8 mg/L, ammonia content (total nitrogen) 0.5-2.0 mg/L and total hardness (CaCO<sub>3</sub>) 85.0-104.5 mg/L, six fish were gently transferred to a small glass aquarium containing a mild anesthetic (MS 222, 20 mg/L). In the laboratory, the fish were killed quickly with an overdose of MS222 (200 mg/L), then the spleen, kidneys, skin and gills of the control and infection groups were collected and divided into small pieces and stored in liquid nitrogen (LN<sub>2</sub>) and fixed in 2.5% glutaraldehyde in the phosphate buffer for total RNA extraction and transmission electron microscope (TEM), respectively.

### Ultrastructural Changes of The Kidneys, Spleen, Skin and Gills

Transmission electron microscopy preparations were obtained by fixing the kidneys, spleen, skin and gills in 2.5% glutaraldehyde in the phosphate buffer, and 2% osmium tetroxide is used for postfixation. After rinsing with phosphate buffer, the specimens were dehydrated in graded ethanol and then embedded in Epon 812 (Epikote resin). Ultrathin sections were sliced with glass knives on a UCT ultramicrotome (Leica Ltd, Germany), stained with uranyl acetate and lead citrate, and examined under a Tecnai 12 electron microscope (FEI, Acht, Netherlands) [12].

### Detection of iNOS Enzyme Activity

The iNOS enzyme activity in the kidneys, spleen, skin and gills of the infected and uninfected control groups was

measured employing the NOS Activity Assay Kit according to manufacturer's instructions (Jiancheng, Nanjin, China) [4].

### Identification of Inducible Nitric Oxide Synthase Gene

Primers for *iNOS* gene were designed within the highly conserved regions of grass carp *iNOS* gene (GenBank accession number HQ589354.1): *iNOS* F (5'-CAC CTT CAA TCC GAC CTT A-3') and *iNOS* R (5'-AAT CAC GAC AGC CGA ACA C-3') [3]. Total RNA was extracted from grass carp kidneys, spleen, skin and gills using the RNAiso Plus reagent (Takara, Dalian, China) according to the manufacture's instruction. cDNA was synthesized using the PrimeScript™ RT reagent Kit with gDNA Eraser (Takara, Dalian, China). Polymerase chain reaction (PCR) amplification was performed using a 2× EasyTaq PCR SuperMix (TransGen Biotech, Beijing, China). PCR was carried out as follows: initial denaturation at 95°C for 5 min; 30 cycles of denaturation at 95°C for 30 s, annealing at 58°C (*iNOS*) for 30 s, and extension at 72°C for 1 min; followed by 10 min at 72°C for the final extension. The amplified PCR products were processed by electrophoresis in 1% agarose gel. The PCR products were purified and ligated into a pMD19-T vector (Takara, Dalian, China), transformed into competent *E. coli* DH5α, and plated on the Amp-LB-agar petri dish, respectively. Positive colonies containing expected size inserts were screened by colony PCR, and sequenced by Sangon (Shanghai, China) [3].

### Quantitative Real Time PCR

Quantitative real-time PCR was performed on ABI PRISM 7500 Fast Real-time PCR System with SYBR-Green as fluorescent dye referring to manufacturer's protocol (Takara, Dalian, China). Grass carp  $\beta_2m$  gene (GenBank accession number AB190816) was used as an internal reference ( $\beta_2m$ F: 5'-GGCTGGCAGTTTCACCTCAC-3',  $\beta_2m$ R: 5'-CCACCCTTTGTCTGGCTTTG-3'). Quantitative primers for *iNOS* gene (*iNOS* F: 5'-CAC CTT CAA TCC GAC CTT A-3'; *iNOS* R: 5'-AAT CAC GAC AGC CGA ACA C-3') was designed according to the sequencing results above [3]. All reactions were performed in triplicates. The qPCR conditions were carried out as follows: 60 s at 95°C, followed by 40 cycles of 15 s at 95°C, 30 s at 58°C, and 40 s at 72°C. The reaction specificity was confirmed by observing a single peak at the expected  $T_m$  on the melting curve. Gene expression in different tissues

was determined as a ratio of target gene vs reference gene and calculated according to the following equation: the relative expression ratio of a target gene ( $R = (E_{reference})^{Ct_{reference}} / (E_{target})^{Ct_{target}}$ ) where  $E$  is the amplification efficiency, and  $Ct$  is the number of PCR cycles needed for the signal to exceed a predetermined threshold value.  $R = (E_{target})^{Ct_{target} - Ct_{reference}}$  [3].

### Statistical Analysis

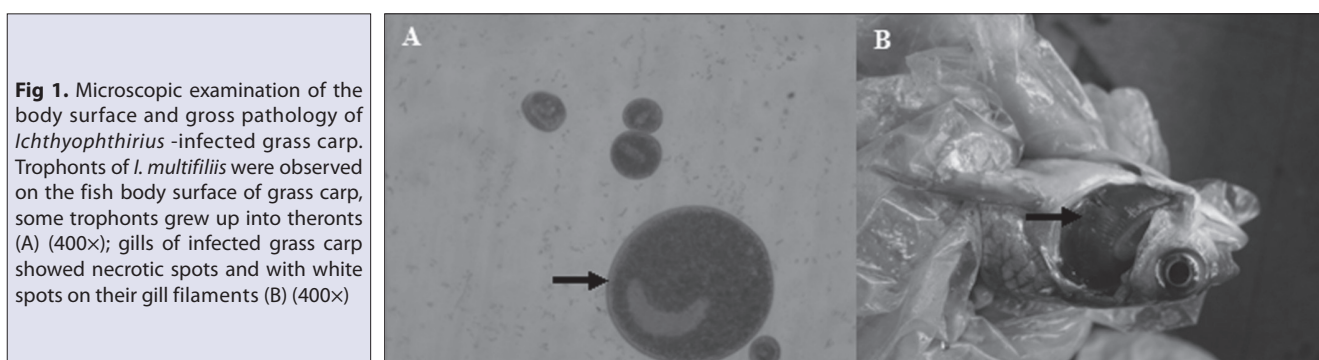
*iNOS* gene expression data were analyzed by one-way analysis of variance (one-way ANOVA), and  $P < 0.05$  was considered significant. All the statistical analyses were performed using SPSS® Version 17.0 software (SPSS Inc., Chicago IL, USA). All the measurements were made in triplicate.

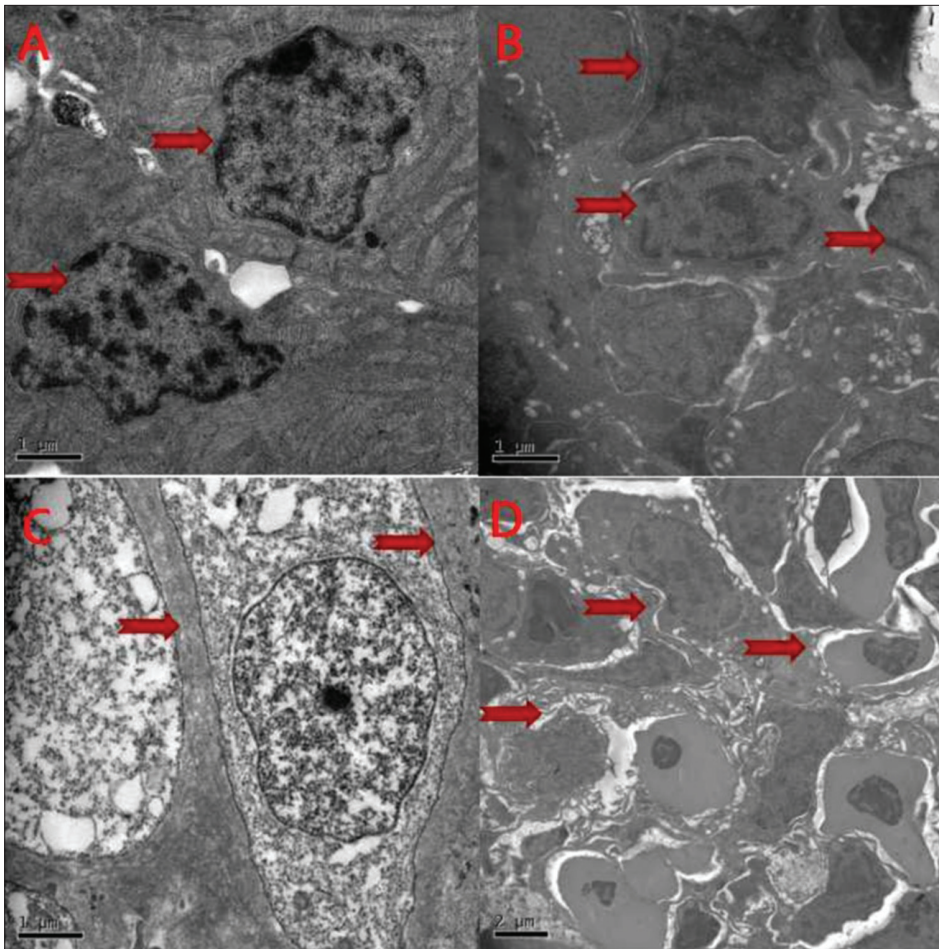
## RESULTS

The trophonts were seen on the fish body surface within 3~5 days of infection with *I. multifiliis*. White spots were observed on the mucus of head and scale under the microscope of affected fish (Fig. 1A). The scale showed the yellowish-white lesions, and the gills appeared necrotic with encysted organisms "white spots" (Fig. 1B).

Kidneys (Fig. 2A), spleen (Fig. 2B), gills (Fig. 2C) and skin (Fig. 2D) of the control group showed normal morphology. Cells of the control group had evident nuclei, nucleopores, and exhibited normal morphology (arrowheads). The reticular fibers in the kidneys and skin were very visible; lymphocytes and their intercellular space in the spleen were observed clearly; and blood and dermal cells in the skin were found, with obvious dermal cell nuclei. However, pathologic and ultrastructural changes of *I. multifiliis* infection in kidneys, spleen, gills and skin showed that the distribution of the macrophages and lymphocytes was uneven, and cell nuclei were concentrated and fragmented and/or disappeared in kidneys, spleen, gills and skin. The reticular fibers were loosely organized and damaged, leaving large spaces in between. The intercellular spaces were loose and irregular with large holes. Many cellular structures had already disappeared (Fig. 3A,B,C,D).

Furthermore, *iNOS* enzyme activity in the kidneys (Fig. 4A) and spleen (Fig. 4B) ( $P < 0.05$ ), and in the gills (Fig. 4C) and





**Fig 2.** Ultrathin sections in kidneys (A) (3000×), spleen (B) (3000×), gills (C) (3000×) and skin(D) (1900×) of the control group

skin (Fig. 4D) ( $P < 0.01$ ) was significantly down-regulated in the *Ichthyophthirius*-infected groups compared to the uninfected control group.

iNOS enzyme activity in the infected group was significantly down-regulated compared to the uninfected control group (Fig. 4). Furthermore, iNOS enzyme activity in the gills and skin were substantially different after *Ichthyophthirius*-infection ( $P < 0.01$ ). Similarly, iNOS enzyme activity in the kidneys and spleen were significant different ( $P < 0.05$ ). The expression of iNOS gene in the kidneys (Fig. 5A) and spleen (Fig. 5B) ( $P < 0.05$ ) and in the gills (Fig. 5C) and skin (Fig. 5D) ( $P < 0.01$ ) was markedly down-regulated after *Ichthyophthirius* infection (Table 1).

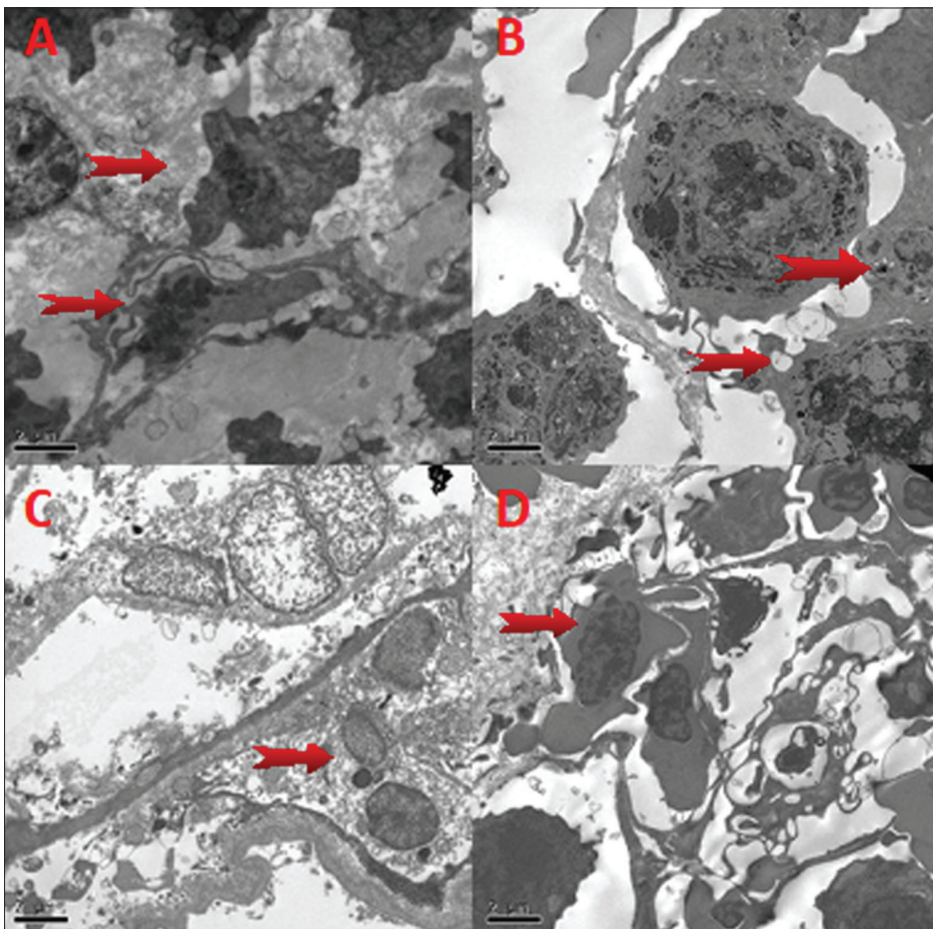
iNOS gene expression in the infected tissues and organs were substantially down-regulated compared to the uninfected control group. In the kidneys and spleen, iNOS gene expression were significantly different ( $P < 0.05$ ). Similarly, iNOS gene expression were highly significantly different in the gills and skin ( $P < 0.01$ ). The results denoted that damages were more obvious in the gills and skin after *Ichthyophthirius* infection in comparison with those in kidneys and spleen.

The expression of iNOS gene in the gills, skin, kidneys, and spleen of *Ichthyophthirius*-infected grass carp was

significantly down-regulated compared with the control groups as shown in Table 1. iNOS gene expression ratio were highly significantly different in the gills and skin ( $P < 0.01$ ), and significantly different in kidneys and spleen after infection ( $P < 0.05$ ).

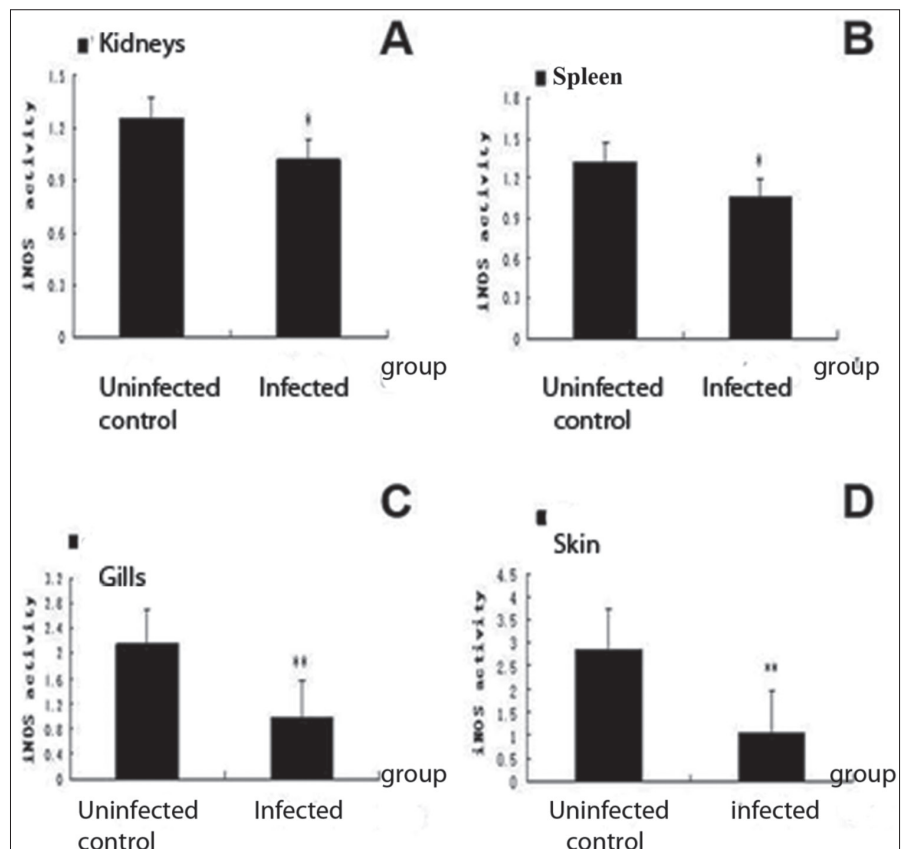
## DISCUSSION

Nitric oxide is a biological messenger and immune-regulation factor. Its immune action was found in human, rats and pigs earlier than in freshwater fish [13,14]. Nitric oxide is generated by nitric oxide synthases and plays a major role in immune-mediated protection against parasitic diseases [15]. The NOS enzyme, the primary source of NO, has three isoforms, including inducible NO synthesis (iNOS), which plays an important role in the parasitic infections [8]. iNOS, an important effector molecule, restricts pathogen growth in infected hosts [16,17]. Our results showed that the enzyme activity and gene expression of iNOS were substantially down-regulated in the kidneys and spleen ( $P > 0.05$ ) and in the gills and skin ( $P < 0.05$ ) compared to that in the negative controls. Similarly, recent evidence shows that the downregulation of iNOS, SOD and  $H_2O_2$  expressions in *Clonorchis*-infected freshwater [18]. However, Gonzalez et al. [19] found that iNOS gene expression was significantly up-regulated in the



**Fig 3.** Pathologic and ultrastructural changes of *Ichthyophthirius* infected tissues. The necrosis and disappearance of lymphocyte and epithelial cell nuclei of the kidneys (A); the uneven distribution the macrophages and lymphocytes, and fragmented and degenerative lymphocyte cell nuclei in spleen (B); the necrotic and degenerative epithelial cells of the gills (C) and skin (D); the uneven distribution of the immune or immune-related cell nuclei and its concentration and disappearance (arrow, 1900 $\times$ )

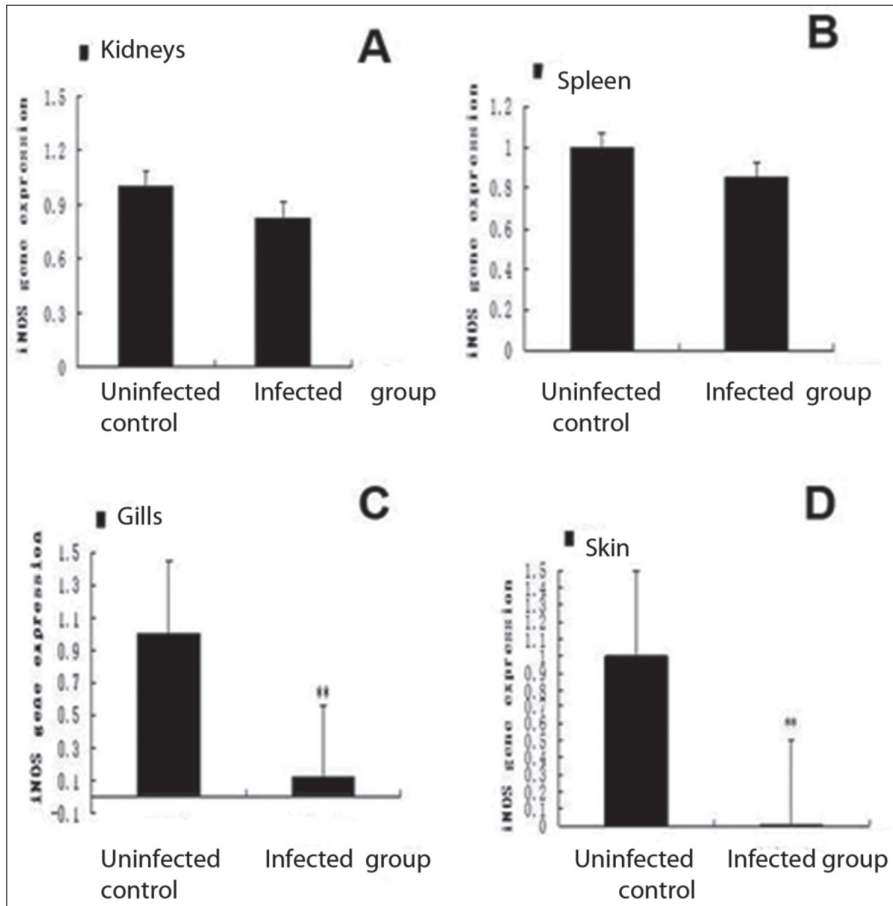
**Fig 4.** iNOS enzyme activity. iNOS enzyme activity in the kidneys (A) and spleen (B), and in the gills (C) and skin (D) are significantly down-regulated in the *Ichthyophthirius*-infected groups compared to the uninfected control group, \* $P < 0.05$ , \*\*  $P < 0.01$



**Table 1.** iNOS gene expression in different tissues

Relative Expression Ratio of iNOS Gene	Kidneys	Spleen	Gills	Skin
Control group	1	1	1	1
Infection group	0.828±0.756*	0.854±0.663*	0.12±0.09**	0.0082±0.0018**

Values are means±standard errors. \* P<0.05, \*\* P<0.01

**Fig 5.** iNOS genes expression. The expression of iNOS gene in the kidneys (A) and spleen (B) and in the gills (C) and skin (D) was markedly down-regulated after infection, \* P<0.05, \*\* P<0.01

blood of infected carp. Similarly, iNOS gene expression was substantially up-regulated in the skin of rainbow trout by immune radiovaccine against *Ichthyophthirius multifiliis*, and in the gills of *Ichthyophthirius*-infected rainbow trout larvae [20,21]. These findings may help us to understand the iNOS expression profile in the naïve and primed fish. Additionally, the low level of iNOS enzyme activity and gene expression in the gills and skin were significant compared with that in the kidneys and spleen of grass carp infected with *I. multifiliis* indicating the gills and skin are the main protective barrier with different immune regulators. Meanwhile, the results of iNOS enzyme activity and gene expression in the skin and gills were related with the active immune cells. Interestingly, the immune cells in the skin and gills were more degenerated and necrotic than in the kidneys and spleen of the *Ichthyophthirius*-infected grass carp. Similarly, previous studies showed that iNOS can be limited to certain organs and stages of infection in mice [22,23]. While Losada et al. [24] reported the obvious increase of iNOS

positive cells in the intestine more than in the spleen and kidneys of the *Enteromyxum*-infected turbot, indicating that the iNOS level delayed the response, and made tissue lesion worse. Therefore, different parasites invaded the different target organs and the gills and skin are the main sites of parasitic invasion [22,25,26]. Low levels of iNOS enzyme activity and gene expression in the spleen and kidneys of the *Ichthyophthirius*-infected grass carp owing to its immune cell damage, which are connected with the iNOS production [27,28]. Gills and skin are the mucosal tissues associated with the immune system of fish. Gills are involved in the immune defense through the mucosa associated lymphoid tissues as a respiratory organ [29-31]. *I. multifiliis* infected grass carp by invading the skin and gill barrier, destroyed the lymphocyte structure and capillary circulation. We also showed that prerequisites for intact gills as sources of gas exchange and nutrition for all the fish body, including the spleen and kidneys. The reduction of immune cells in the absence of nutrients and oxygen

is a reliable conclusion to be drawn [32,33]. On the other hand, our previous studies showed that the disappearance and destruction mitochondria in the spleen and kidneys of the *Ichthyophthirius*-infected grass carp, which may attribute to the loss of nutrients and oxygen caused by *I. multifiliis* without the oxidation injury [4]. Furthermore, NO is also a kind of vasodilator activity, gills and skin are rich in the blood capillary. From our studies, the red cells were destroyed in the gills and skin of the fish [34]. Therefore, this study proved that iNOS enzyme activity and gene expression in the gills and skin were more down-regulated than in the spleen and kidney of the infected group due to the reduction in the number of immune cells via oxygen deficiency. These results are in line with those of previous studies [27,28,35,36]. Expression and activity of inducible nitric oxide synthase could serve as an important indicator to determine the pathological status of the *I. multifiliis*-grass carp. This could perhaps also be useful for better management of the aquaculture conditions.

## ACKNOWLEDGEMENTS

This research was supported by grants from Guangdong educational department preventive veterinary medicine key lab project (Grant No.: 2014KTSPT 037), Start-up Research Grant Program provided by Foshan University, Foshan city, Guangdong province for distinguished researchers, and School of Life Science and Engineering fund (Grant No: KLPREAD201801-02).

## COMPETING FINANCIAL INTERESTS

The authors declare no competing financial and non-financial interests.

## REFERENCES

1. Wang X, Dickerson HW: Surface immobilization antigen of the parasitic ciliate *Ichthyophthirius multifiliis* elicits protective immunity in channel catfish (*Ictalurus punctatus*). *Clin Diagn Lab Immunol*, 9 (1): 176-181, 2002. DOI: 10.1128/CDLI.9.1.176-181.2002
2. Matthews RA: *Ichthyophthirius multifiliis* fouquet and ichthyophthiriosis in freshwater teleosts. *Adv Parasitol*, 59, 159-241, 2005. DOI: 10.1016/S0065-308X(05)59003-1
3. Yu H, Yan QG, Wang ZB, Lu YJ, Xu MJ, Li H, Zhu XQ: MH II-DAB gene expression in grass carp *Ctenopharyngodon idella* (Valenciennes) after infection with the ciliate parasite, *Ichthyophthirius multifiliis*. *J Fish Dis*, 37 (1): 43-50, 2014. DOI: 10.1111/j.1365-2761.2012.01442.x
4. Lu Y J, Wang Z B, Wei J Z, Yu H: Effects of *Ichthyophthirius multifiliis* on mitochondria in liver and kidney tissues of grass carp. *China Anim Husband Vet Med*, (03): 619-623, 2015.
5. El-Ashram S, Al Nasr I, Hu M, Suo X: Host-oriented inherent measures and eukaryotic parasite countermeasures. *J Mol Immunol*, 2:106, 2017.
6. El-Ashram S, Al Nasr I, Huang S, Zhang H, Abouhajer F, Dincel GC, He C: Indispensable biological processes offer exceptional cellular and molecular windows for pharmacological interventions in protozoan parasites. *EC Microbiol*, 9.2: 47-68, 2017.
7. Dickerson HW, Findly RC: Immunity to *Ichthyophthirius* infections in fish: A synopsis. *Dev Comp Immunol*, 43 (2): 290-299, 2014. DOI: 10.1016/j.dci.2013.06.004
8. Ingram GA: Substances involved in the natural resistance of fish to infection - A review. *J Fish Biol*, 16 (1): 23-60, 1980. DOI: 10.1111/j.1095-8649.1980.tb03685.x
9. Yao J, Li C, Zhang J, Liu S, Feng J, Wang R, Li Y, Jiang C, Song L, Chen A, Liu Z: Expression of nitric oxide synthase (NOS) genes in channel catfish is highly regulated and time dependent after bacterial challenges. *Dev Comp Immunol*, 45 (1): 74-86, 2014. DOI: 10.1016/j.dci.2014.02.005
10. Wink DA, Hines HB, Cheng RY, Switzer CH, Flores-Santana W, Vitek MP, Ridnour LA, Colton CA: Nitric oxide and redox mechanisms in the immune response. *J Leukoc Biol*, 89 (6): 873-891, 2011. DOI: 10.1189/jlb.1010550
11. Liu X, Wu G, Shi D, Zhu R, Zeng H, Cao B, Huang M, Liao H: Effects of nitric oxide on notexin-induced muscle inflammatory responses. *Int J Biol Sci*, 11 (2): 156-167, 2015. DOI: 10.7150/ijbs.10283
12. Yu H, Wang ZB, Lu YJ, Tan SW, Yan QG, Li H: Histopathological study of grass carp (*Ctenopharyngodon idella*) experimentally infected with *Ichthyophthirius multifiliis*. *Afr J Microbiol Res*, 6 (14): 3539-3544, 2012.
13. Gordon S, Stefan HK, Medzhitov R: The innate immune response to infection. *Int J Med Microbiol*, 295 (2): 128, 2005. DOI: 10.1086/431126
14. Buchmann K: Evolution of innate immunity: Clues from invertebrates via fish to mammals. *Front Immunol*, 5:459, 2014. DOI: 10.3389/fimmu.2014.00459
15. James SL: Role of nitric oxide in parasitic infections. *Microbiol Rev*, 59 (4): 533-547, 1995.
16. Nathan C, Xie QW: Regulation of biosynthesis of nitric oxide. *J Biol Chem*, 269 (19): 13725-13728, 1994.
17. Scharton-Kersten TM, Yap G, Magram J, Sher A: Inducible nitric oxide is essential for host control of persistent but not acute infection 1261-1273, 1997. DOI: 10.1084/jem.185.7.1261
18. Ren M, He L, Huang Y, Mao Q, Li S, Qu H, Bian M, Liang P, Chen X, Ling J, Chen T, Liang C, Wang X, Li X, Yu X: Molecular characterization of *Clonorchis sinensis* secretory myoglobin: Delineating its role in anti-oxidative survival. *Parasit Vectors*, 7:250, 2014. DOI: 10.1186/1756-3305-7-250
19. Gonzalez SF, Buchmann K, Nielsen ME: Real-time gene expression analysis in carp (*Cyprinus carpio* L.) skin: Inflammatory responses caused by the ectoparasite *Ichthyophthirius multifiliis*. *Fish Shellfish Immunol*, 22 (6): 641-650, 2007. DOI: 10.1016/j.fsi.2006.08.011
20. Heidarieh M, Diallo A, Mood S, Taghinejad V, Akbari M, Monfaredan A: Gene expression analysis in rainbow trout (*Oncorhynchus mykiss*) skin: Immunological responses to radiovaccine against *Ichthyophthirius multifiliis*. *Revue Méd Vét*, 166, 233-242, 2015.
21. Heinecke RD, Buchmann K: Inflammatory response of rainbow trout *Oncorhynchus mykiss* (Walbaum, 1792) larvae against *Ichthyophthirius multifiliis*. *Fish Shellfish Immunol*, 34 (2): 521-528, 2013.
22. Gordon S, Stefan HK, Medzhitov R: The innate immune response to infection. *Int J Med Microbiol*, ASM Press. 640-643, 2004.
23. Jung YJ, LaCourse R, Ryan L, North RJ: Virulent but not avirulent *Mycobacterium tuberculosis* can evade the growth inhibitory action of a T helper Independent, nitric oxide synthase 2-independent defense in mice. *J Exp Med*, 196 (7): 991-998, 2002. DOI: 10.1084/jem.20021186
24. Losada AP, Bermúdez R, Failde LD, Quiroga MI: Quantitative and qualitative evaluation of iNOS expression in turbot (*Psetta maxima*) infected with *Enteromyxum scophthalmi*. *Fish Shellfish Immunol*, 32 (2): 243-248, 2012. DOI: 10.1016/j.fsi.2011.11.007
25. Jia R, Cao LP, Du JL, Wang JH, Liu YJ, Jeney G, Xu P, Yin GJ: Effects of carbon tetrachloride on oxidative stress, inflammatory response and hepatocyte apoptosis in common carp (*Cyprinus carpio*). *Aquat Toxicol*, 152, 11-19, 2014. DOI: 10.1016/j.aquatox.2014.02.014
26. Sigh J, Lindenstrøm T, Buchmann K: The parasitic ciliate *Ichthyophthirius multifiliis* induces expression of immune relevant genes in rainbow trout, *Oncorhynchus mykiss* (Walbaum). *J Fish Dis*, 27 (7): 409-417, 2004. DOI: 10.1111/j.1365-2761.2004.00558.x
27. Liew FY, Wei XQ, Proudfoot L: Cytokines and nitric oxide as effector molecules against parasitic infections. *Philos Trans R Soc Lond B Biol Sci*, 352 (1359): 1311-1315, 1997. DOI: 10.1098/rstb.1997.0115
28. Cedergren J, Forslund T, Sundqvist T, Skogh T: Inducible nitric oxide

synthase is expressed in synovial fluid granulocytes. *Clin Exp Immunol*, 130 (1): 150-155, 2002. DOI: 10.1046/j.1365-2249.2002.01959.x

**29. Pratap HB, Bonga SEW:** Effect of ambient and dietary cadmium on pavement cells, chloride cells, and Na<sup>+</sup>/K<sup>+</sup> -ATPase activity in the gills of the freshwater teleost *Oreochromis mossambicus* at normal and high calcium levels in the ambient water. *Aquat Toxicol*, 26 (1-2): 133-149, 1993. DOI: 10.1016/0166-445X(93)90010-X

**30. Reite OB, Evensen O:** Inflammatory cells of teleostean fish: A review focusing on mast cells/eosinophilic granule cells and rodlet cells. *Fish Shellfish Immunol*, 20 (2): 192-208, 2006. DOI: 10.1016/j.fsi.2005.01.012

**31. Haugarvoll E, Bjerås I, Nowak BF, Hordvik I, Koppang EO:** Identification and characterization of a novel intraepithelial lymphoid tissue in the gills of Atlantic salmon. *J Anat*, 213 (2): 202-209, 2008.

**32. Matthews RA:** *Ichthyophthirius multifiliis* fouquet and *Ichthyophthiriosis*

in freshwater teleosts. *Adv Parasitol*, 59,159-241, 2005. DOI: 10.1016/S0065-308X(05)59003-1

**33. Kiron V:** Fish immune system and its nutritional modulation for preventive health care. *Anim Feed Sci Technol*, 173 (1-2): 111-133, 2012. DOI: 10.1016/j.anifeedsci.2011.12.015

**34. Lu Y, O B Q, Xu W L, Huang J X, Yu H:** Pathological observation of the effects of *Ichthyophthirius multifiliis* on immune-related organs in grass carp. *Anim Husband Vet Med*, 10, 64-66, 2014.

**35. Wu CH, Siva VS, Song YL:** An evolutionarily ancient NO synthase (NOS) in shrimp. *Fish Shellfish Immunol*, 35 (5): 1483-1500, 2013. DOI: 10.1016/j.fsi.2013.08.016

**36. Gómez D, Bartholomew J, Sunyer JO:** Biology and mucosal immunity to myxozoans. *Dev Comp Immunol*, 43 (2): 243-256, 2014. DOI: 10.1016/j.dci.2013.08.014