

## Discrimination of Early Pregnancy and Endometrial Cyst by Ultrasonographic Assessment of Uterine Echotexture in Mares

Abuzer Kafar ZONTURLU<sup>1</sup> Tugra AKKUS<sup>1</sup> Cihan KACAR<sup>2</sup> Omer KORKMAZ<sup>1</sup>  
Semra KAYA<sup>2</sup> Murat Can DEMİR<sup>2</sup> Birten EMRE<sup>1</sup>

<sup>1</sup> Department of Obstetrics and Gynaecology, Faculty of Veterinary Medicine, Harran University, Sanliurfa, TR-63200 Sanliurfa - TURKEY

<sup>2</sup> Department of Obstetrics and Gynaecology, Faculty of Veterinary Medicine, Kafkas University, TR-36100 Kars - TURKEY

Article Code: KVFD-2018-19476 Received: 22.01.2018 Accepted: 01.06.2018 Published Online: 03.06.2018

### How to Cite This Article

Zonturlu AK, Akkus T, Kacar C, Korkmaz O, Kaya S, Demir MC, Emre B: Discrimination of early pregnancy and endometrial cyst by ultrasonographic assessment of uterine echotexture in mares. *Kafkas Univ Vet Fak Derg*, 24 (4): 519-524, 2018. DOI: 10.9775/kvfd.2018.19476

### Abstract

The present study was performed to demonstrate the tissue differentiation of uterine ultrasonographic image by computer assisted analysis programs in mares with endometrial cyst and early pregnancy. A total of 124 thoroughbred Arabian mares were used in the study, with early pregnancy and endometrial cyst. Mares were divided into six groups according to stage of early pregnancy (Group I, n=12 (13<sup>th</sup> day pregnancy); Group II, n=15 (14<sup>th</sup> day pregnancy); Group III, n=29 (15<sup>th</sup> day pregnancy); Group IV, n=17 (16<sup>th</sup> day pregnancy); Group V, n=12 (17<sup>th</sup> day pregnancy) and as endometrial cysts (Group VI, n=39). The mean gray value (MGV), heterogeneity (HET) and contrast (CON) of the uterine images that were recorded during ultrasound scan were measured through computer assisted program. The MGV values of the echotexture parameters were significantly higher in the pregnant mare (55.20±4.95, 58.31±3.88, 56.23±1.88, 54.15±3.47 and 56.08±2.94, respectively) than the endometrial cyst mares (42.71±0.71) (P<0.001). The HET values were significantly higher in the pregnant mare (20.75±1.53, 19.23±1.39, 21.42±0.88, 22.37±1.32 and 22.20±1.09, respectively) than the endometrial cyst mares (15.06±0.44) (P<0.001). CON values were lower in pregnant mare (152.83±7.02, 144.02±8.18, 141.03±4.83, 145.93±4.70 and 154.65±4.86 respectively) than endometrial cyst mare (191.35±3.97) (P<0.001). As a result; it has been concluded that the measurement values of echotexture parameters (MGV, HET, CON) may be important reference criteria when early pregnancy and endometrial cyst are distinguished in mare, which can often cause misconception.

**Keywords:** Early pregnancy, Endometrial cyst, Echotexture, Mare

## Kısırlarda Ultrasonografik Uterus Ekotekstür Değerlendirmesinde Erken Gebe ve Endometriyal Kist Ayırımı

### Öz

Sunulan çalışma kısırlarda erken gebelik ile endometriyal kistli uterusun ultrasonografik görüntüsünün bilgisayar destekli analiz programları ile ayırımı ortaya koymak amacıyla yapıldı. Çalışmada erken gebe ve endometriyal kistli olmak üzere toplam 124 safkan Arap kısırak kullanıldı. Kısırlar erken gebelik dönemlerine (Grup I, n=12 (13 günlük gebelik); Grup II, n=15 (14 günlük gebelik); Grup III, n=29 (15 günlük gebelik); Grup IV, n=17 (16 günlük gebelik); Grup V, n=12 (17 günlük gebelik) ve endometriyal kist (Grup VI, n=39) olmak üzere altı gruba ayrıldı. Ultrasonografik muayene sırasında kaydedilen ve daha sonra bilgisayara aktarılan uterus görüntülerinin ortalama gri değeri (MGV), heterojenitesi (HET) ve kontrastı (CON) ölçüldü. Ekotekstür parametrelerinden MGV değeri gebe kısırlarda (sırasıyla; 55.20±4.95, 58.31±3.88, 56.23±1.88, 54.15±3.47 ve 56.08±2.94), endometriyal kistli kısırlardan (42.71±0.71) daha yüksekti (P<0.001). Diğer ekotekstür parametresi olan HET değerleri gebe kısırda (sırasıyla; 20.75±1.53, 19.23±1.39, 21.42±0.88, 22.37±1.32 ve 22.20±1.09), endometriyal kistli kısırlardan (15.06±0.44) daha yüksekti (P<0.001). CON değerleri ise gebe kısırlarda (sırasıyla; 152.83±7.02, 144.02±8.18, 141.03±4.83, 145.93±4.70 ve 154.65±4.86), endometriyal kistli kısırlardan (191.35±3.97) düşüktü (P<0.001). Sonuç olarak; kısırlarda sıklıkla yanılığa sebep olabilecek erken gebelik ile endometriyal kistin ayırt edilmesinde, ekotekstür parametrelerinin (MGV, HET ve CON) ölçümsel değerlerinin önemli referans kriterleri olabileceği sonucuna varılmıştır.

**Anahtar sözcükler:** Erken gebelik, Endometriyal kist, Ekotekstür, Kısırak

## INTRODUCTION

Real-time B-mode ultrasonography is one of the most

widely used diagnostic methods for monitoring reproduction in farm animals, which was first used in mares<sup>[1]</sup> in 1980 and later in cows<sup>[2,3]</sup>. Ultrasonography is also an important



### İletişim (Correspondence)



+90 532 7951673



cihan3000@hotmail.com

diagnostic tool used routinely in the physiological and pathological detection of early pregnancy, follicular changes in the ovaries and ovarian cysts and reproductive areas such as tumors, cysts, infections in the genital organs [4,5].

Ultrasonographic imaging is based on the ability of tissues to reflect high-frequency sound waves and this reflection depends on tissue density [6,7]. The images are displayed in a two-dimensional, gray scale based on the location and strength of the echoes from the tissue interfaces [8]. A two-dimensional ultrasonographic image is a matrix of square picture elements (pixels) varying in gray scale values ranging from 0 (absolute black) to 255 (absolute white) [6,7,9]. The ultrasonographic image of a tissue varies depending on the histological structure of the tissue and is called echotexture. Computer-assisted analysis (computer algorithm) allows an object to be evaluated objectively and provides determination of visual analysis subjectivities, allowing quantitative assessment of the intensity of each pixel in an image [10]. In recent years, computer-assisted ultrasonographic image analysis techniques have been used in the evaluation of genital organs including testicles [11], ovarian follicles [12], corpus luteum [12-14] and uterus [15]. The echotextural changes in the endometrium are used in the field of reproduction in veterinary medicine [16-18]. Computer assisted image analysis removes individual observation bias by allowing quantitative evaluation. The mean gray value (MGV), heterogeneity (HET) and contrast (CON) of the parameters obtained from the ultrasonographic images define the uterine echogenic image changes [19]. In computer-assisted analysis, images are obtained in three ways; point measurement, linear-time series analysis, and regional surface analysis [6]. When the images obtained in the studies were measured in computer environment, the target tissue was divided into four equal quadrants according to the point measurement and a small circular area was selected from these regions and average numerical data was formed [16,19-24].

In mares, endometrial cysts are fluid-filled formations that can be seen anywhere on the normal or chronically inflamed endometrium [25]. They have glandular (endometrial) or lymphatic structure, depending on their characteristics. Glandular cysts are found in the lamina propria and are typically smaller (1-10 mm) in size and exhibit multifocal distribution in one or more areas of the uterus. Lymphatic cysts are typically larger (>10 mm) and are usually isolated at one or two loci. Ultrasonography or hysteroscopy should be used to identify both types of cysts [26]. These types of cysts in the mare uterus can easily be confused with early or twin pregnancies in ultrasonographic examination and pregnancies may even be accidentally terminated during manipulation of uterine cyst in singleton pregnant mares that are mistaken for twin pregnancy. Furthermore, the inability of the embryonic vesicle to move freely in the uterine horns in the presence of cysts cannot reduce the secretion of prostaglandin F<sub>2α</sub> and reveal the failure of

maternal diagnosis in pregnancy [27], impaired implantation can lead to insufficient blood flow to the conceptus and inadequate availability of nutrients resulting in early loss of embryo [27]. For this reason, early identification of uterine cysts and their discrimination from pregnancy are important in terms of fertility. Despite the fact that literature [25-27] studies conducted in this respect have differentiated early pregnancy (13-17 days) and endometrial cysts with periodic clinical and ultrasonographic examinations, the measurement and discrimination of these images by computer-assisted analysis programs has not been done previously which manifest deficiency in this topic.

This study aimed to analyze the echotexture changes of uterine tissue by computer analysis program and to inform the veterinarians as an adjunct clinical modality in distinguishing early pregnancy in mares from endometrial cysts that can be confused with the former condition.

## **MATERIAL and METHODS**

### **Ethics Statement**

This study was approved by the Animal Ethics Committee of the University of Harran (Number: 2018/001/01-03).

### **Selection of the Animals**

The present study was carried out on the mares brought to the Veterinary Clinics of Faculty of Veterinary Medicine, Harran University, for pregnancy and genital organ examination during breeding season. This area is located at 37°10'N - 39°03'E and 518 m higher from sea level. In this research, a total of 124 thoroughbred Arabian mares clinically healthy, with age interval of 7.6 and 14.69 years were used. Mares with early pregnancy and endometrial cysts are included in the study. Mares were divided into six groups according to stage of early pregnancy as Group I, n=12, (13<sup>th</sup> day pregnancy); Group II, n=15, (14<sup>th</sup> day pregnancy); Group III, n=29, (15<sup>th</sup> day pregnancy); Group IV, n=17, (16<sup>th</sup> day pregnancy); Group V, n=12, (17<sup>th</sup> day pregnancy) and (Group VI, n=39) with endometrial cyst.

### **Ultrasound Examination**

The examination of genital organs or early pregnancy in mares brought to the clinic was performed with Portable B-mode 5 MHz linear probe transrectal ultrasonograph (SonoSite Edge II Vet®, Providian Medical Equipment LLC, Highland Heights, Ohio, United States). During examinations, images of mares with endometrial cyst and early pregnancy were recorded in the memory sticks. Pregnancy and endometrial cyst images were recorded for evaluation during the breeding season and 13-17 days after the natural mating date in these mares (examination-1). Mares included in this study were then taken to the second examination on the 30<sup>th</sup> day, and those found to have embryo and fetal heartbeat were considered pregnant (examination-2). In the evaluation of recorded image

analysis, records of mares with early pregnancy findings and endometrial cyst obtained from the first examination (examination-1) were transferred to the computer. Ultrasonographic settings (depth, gain, focus, brightness) were kept unchanged throughout the entire study while images were taken. All ultrasonographic examinations were performed by the same person.

### Computer-Assisted Image Analysis

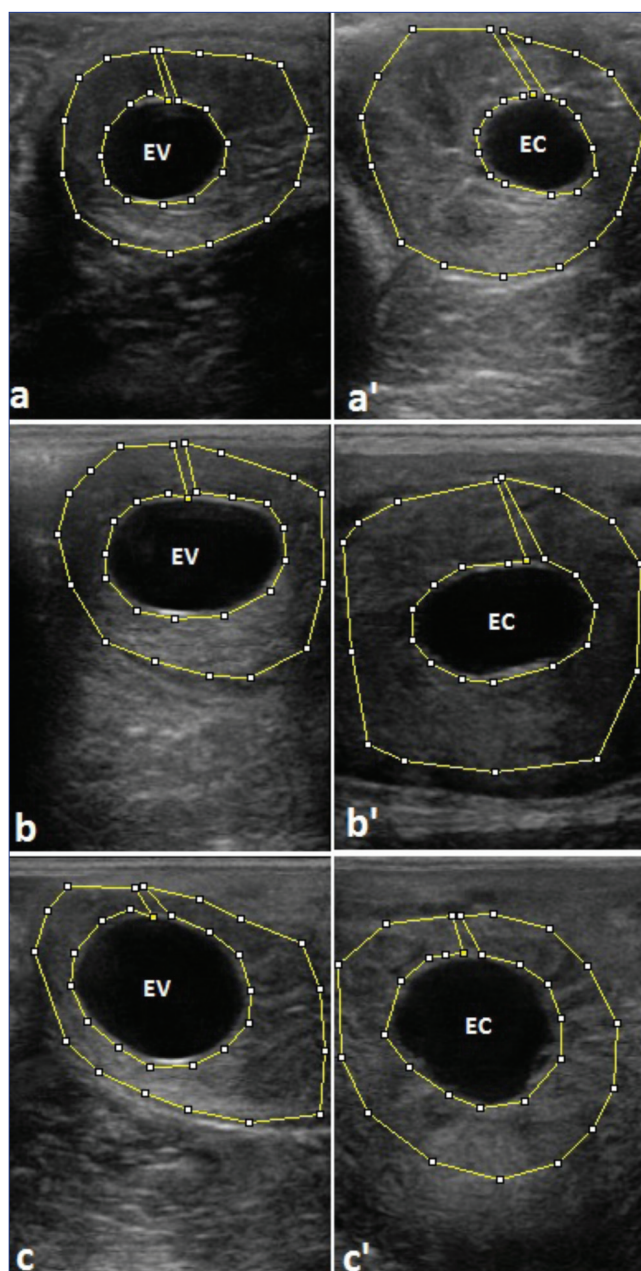
The obtained images were transferred to the computer for evaluation of the digital echotexture. The images were saved as PNG file type with a resolution of 640x480 pixels. Computer analysis was generated using a special software (ImageJ 1.42q; NIH, USA-Image Processing and Analysis Java). The relevant program gives a qualitative value between 0-255. When measurement analysis was performed, polygonal boundaries were created covering every region of the uterus as 'relevant region' by avoiding fluid accumulation in uterus and myometrium, and MG, HET, CON measurements were made (Fig. 1, Fig. 2). Our study was done according to regional surface analysis which was [28] previously performed to determine the echotexture in dog ovaries. Edematous regions of myometrium were avoided during analysis. All uterine tissues were selected in polygonal style and the mean numerical data were obtained. It is thought that this method would give more reliable results compared to the analysis of whole tissue.

### Statistical Analysis

Statistical analyses were performed using the SPSS software version 22. The variables were investigated using visual (histograms, probability plots) and analytical methods (Kolmogorov-Smirnov/Shapiro-Wilk's test) to determine whether they are normally distributed or not. Descriptive analyses were presented using means and standard deviations for normally distributed MG, HET and CON variables. One-way ANOVA was used to compare these parameters among the early pregnancy and endometrial cyst groups. Levene test was used to assess the homogeneity of the variances. An overall P-value of less than 0.05 was considered to show a statistically significant result. When an overall significance was observed, pairwise post-hoc test was performed using Tukey's test. The data in the section of table, graph and results are expressed as mean±standard deviation.

## RESULTS

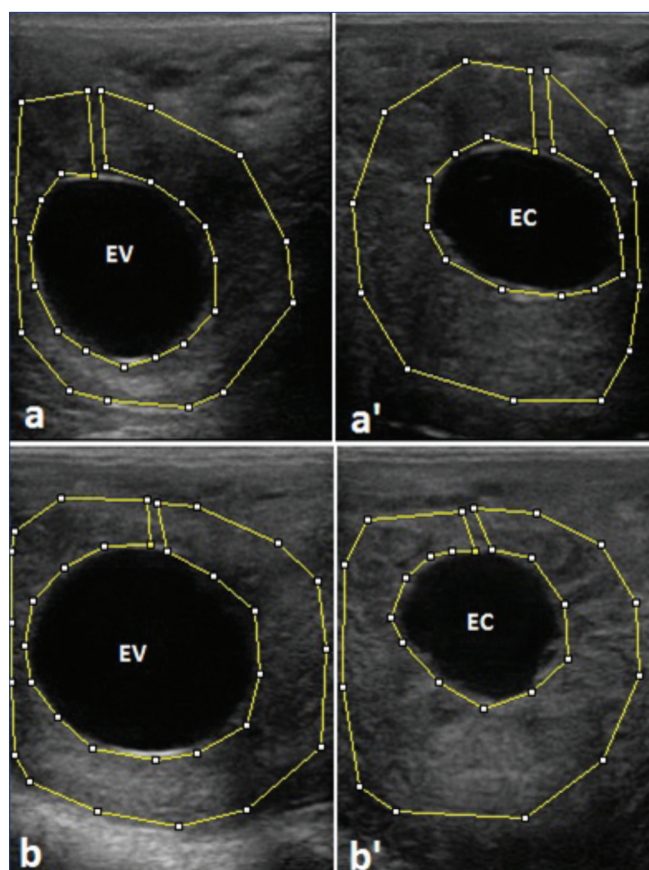
The MG, HET and CON values were analyzed with 95% confidence in evaluating echotexture from images taken from uterine tissue. As a result of the analysis, a significant difference was found between the all group ( $P<0.001$ ) (Table 1). The MG values of the echotexture parameters were significantly different between the endometrial cyst group (Group VI) and the 13 days pregnancy group (Group



**Fig 1.** 13 days pregnancy (a), endometrial cyst (a'), 14 days pregnancy (b), endometrial cyst (b'), 15 days pregnancy (c), endometrial cyst (c'), EV: embryonic vesicle. EC: endometrial cyst

I) ( $P<0.05$ ). This difference was found to be more significant ( $P<0.01$ ) between 14 days (Group II), 16 days (Group IV) and 17 days (Group V) pregnancy and even more significant difference was found in the 15 days pregnancy (Group III) ( $P<0.001$ ). There was no difference when the according to stage of pregnant groups were evaluated among themselves ( $P>0.05$ ) (Fig. 3A). HET was statistically significant between the endometrial cyst group and the 13 days pregnancy group ( $P<0.01$ ). This difference was found to be more significant in 15, 16 and 17 days of pregnancy ( $P<0.001$ ). However, the difference between the 14 days pregnancy and the cyst group was not significant ( $P>0.05$ ). There was no difference when the pregnant groups were





**Fig 2.** 16 days pregnancy (a), endometrial cyst (a'), 17 days pregnancy (b), endometrial cyst (b'), EV: embryonic vesicle. EC: endometrial cyst

evaluated among themselves ( $P < 0.05$ ) (Fig. 3B). The CON value was found statistically significant among all the other pregnant group in the endometrial cyst group ( $P < 0.001$ ). There was no difference when the pregnant groups were evaluated among themselves ( $P > 0.05$ ) (Fig. 3C).

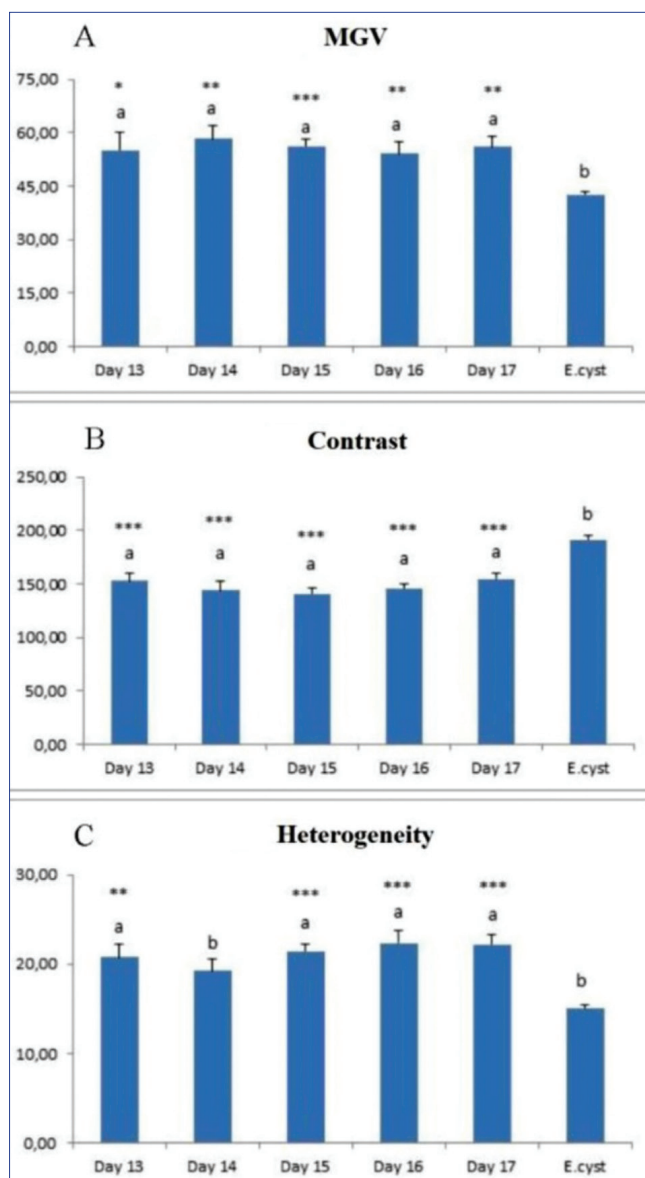
## DISCUSSION

The precise diagnosis of early pregnancy in mares during breeding season is critical for breeders. Although rectal palpation is widely used for diagnosis of pregnancy, it can be confused with endometrial cyst since it is not possible to palpate the embryonic vesicle [29]. It is important to monitor the embryonic vesicle without inner cell mass and embryo in the management of clinical diagnosis of early pregnancy in mares. Although the diagnosis of a product of conception is routinely detected by transrectal ultrasonography between 14-18 days after ovulation in mares, it is not possible to diagnose an abnormal vesicle because ultrasonographic appearance of the inner cell mass or embryo development cannot be obtained at this stage. By transrectal ultrasonography, embryo in the embryonic vesicle can be detected earliest at day 20 ovulation and the embryonic heart beat can be seen between 24-25 days [29]. Examination was done in mares between days 13 and 18 and embryonic heartbeats were observed parallel to the growth of the embryonal sac in the repeated examination. However, there was no change in vesicle size and appearance in the mares with endometrial cyst. In studies conducted on endometrial cysts, the incidence of cysts increased with age; the most commonly affected mares were reported to be over 10 years old [30,31]. The incidence of endometrial cysts in the fertile and subfertile mares has been reported to be between 13 and 22% [32]. In some studies, encountered 55.5% of endometrial cysts in ultrasonographic examinations routinely performed on 310 mares, ranging in age from 8 to 20 years [33]. In another study, a total of 95 cysts were found in 58 of 259 healthy mares, ranging in age from 3 to 22 years. While 73.1% of these cysts belonged to the mares older than 14 years, 29.1% belonged to mares between 7-14 years of age [32]. The number of cystic structure in mares varies from 1 to

**Table 1.** The difference between the average MGV, heterogeneity and contrast values of the uterus of endometrial cystic and early pregnant mares

Groups	N	MGV	Heterogeneity	Contrast
		X±Sx	X±Sx	X±Sx
Group I (13 <sup>th</sup> day pregnancy)	12	55.20±4.95 <sup>a</sup>	20.75±1.53 <sup>a</sup>	152.83±7.02 <sup>a</sup>
Group II (14 <sup>th</sup> day pregnancy)	15	58.31±3.88 <sup>a</sup>	19.23±1.39 <sup>b</sup>	144.02±8.18 <sup>a</sup>
Group III (15 <sup>th</sup> day pregnancy)	29	56.23±1.88 <sup>a</sup>	21.42±0.88 <sup>a</sup>	141.03±4.83 <sup>a</sup>
Group IV (16 <sup>th</sup> day pregnancy)	17	54.15±3.47 <sup>a</sup>	22.37±1.32 <sup>a</sup>	145.93±4.70 <sup>a</sup>
Group V (17 <sup>th</sup> day pregnancy)	12	56.08±2.94 <sup>a</sup>	22.20±1.09 <sup>a</sup>	154.65±4.86 <sup>a</sup>
Group VI (Endometrial cyst)	39	42.71±0.71 <sup>b</sup>	15.06±0.44 <sup>b</sup>	191.35±3.97 <sup>b</sup>
P value (one way ANOVA)		P=0.000 ***	P=0.000 ***	P= 0.000 ***

<sup>a,b</sup>The letters on the table are statistically different. A significant difference was found between the six group averages for the related parameter variables ( $P < 0.001$ ), ANOVA: Analysis of variance. Values in the table mean the mean±SEM



**Fig 3.** Mean gray value (MGV) (3A), heterogeneity (3B) and contrast (3C) in pregnant and endometrial cyst groups. Values in the column values the mean±SEM

**A:** <sup>a,b</sup> The letters on the graph are statistically different. <sup>\*\*\*</sup> Differentiation of endometrial cysts compared to early pregnancy periods, \* P<0.05, \*\* P<0.01, \*\*\* P<0.001; **B:** <sup>a,b</sup> The letters on the graph are statistically different. <sup>\*\*\*</sup> Differentiation of endometrial cysts compared to early pregnancy periods, \*\*\* P<0.001; **C:** <sup>a,b</sup> The letters on the graph are statistically different. <sup>\*\*\*</sup> Differentiation of endometrial cysts compared to early pregnancy periods, \*\* P<0.01, \*\*\* P<0.001

7 per mare with 3 to 48 mm in diameter which increases with age [32,34]. In this study, mares between 5 and 18 years of age were used and both fertility and predisposition to cyst development were achieved, and the prevalence of endometrial cysts (localization to a single uterine region) by ultrasonographic examinations and localization of cysts was found to be consistent with the literature data. While endometrial cysts can be found anywhere within the uterus or cervix, they are more common near the bifurcation area of the horns and in the uterus [35]. In a retrospective study of 55 mares treated for cysts, 33.8% of the cysts were found

endometrium in the uterine tissue, and 16.4% were found in the endometrium in the conjuncional region of the uterine horns [36]. Two other studies conducted on 48 and 259 mares, respectively, reported that the most common location of cysts is the junction of the uterine horns and body of the uterus [30,32]. In our study, the vast majority of cysts were found in the endometrium and only one of them was in the junction of the horns. Twins have also been encountered during the study, but they have not been evaluated.

B-mode ultrasonography computer-assisted image analysis has been used for evaluation of uterus [37] and ovaries [20,23,38-40]. In order to determine the relationship of embryonic fixation with echotexture parameters, a significant increase in uterine echotexture was demonstrated in the MGV measurements on day 21 after mating in cattle [16,41], on day 15-16 in mares [42], on day 16 in goats [19] and in pigs [17]. In the mares [43] and in cows [16], echotextural changes in the endometrial tissue were reported to be associated with peripheral concentrations of ovarian hormones. It has been reported that uterine echotexture values increased during the pre-estrus and pre-ovulation period [41] in the heifers and decreased in the mares [42]. In the goats, computer-assisted analysis measurements for reproductive organs and luteal function were established [19,44,45]. Studies on echotextures in farm animals have been carried out on sexual cycle follow-up, pregnancy, evaluation of genital organs and monitoring ovarian hormones. Increased echotexture parameters in early pregnancy were reported in mares, but endometrial cyst and early pregnancy, which constitute significant problems, have not been evaluated for echotextural changes. In the present study, increased uterus echotexture in early pregnancy was compatible with the previous studies and uterus echotexture was found to be statistically significantly higher in pregnancies between 13-17 days compared to mares with endometrial cysts. This has led to the conclusion that the uterine echotexture may have been increased in pregnancy due to endometrial folding, which begins to increase during early pregnancy and to the effect of the incoming blood flow on vascular permeability [29].

As a result, endometrial cysts that may lead to confusion in mares during early pregnancy can be distinguished from early pregnancy by analyzing their MG, HET and CON of echotexture parameters.

## REFERENCES

1. Palmer E, Driscourt MA: Use of ultrasonic echography in equine gynecology. *Theriogenology*, 13, 203-216, 1980. DOI: 10.1016/0093-691X(80)90082-5
2. Pierson RA, Ginther OJ: Ultrasonography of the bovine ovary. *Theriogenology*, 21, 495-504, 1984. DOI: 10.1016/0093-691X(84)90411-4
3. Reeves JJ, Rantanen NW, Hauser M: Transrectal real-time ultrasound scanning of the cow reproductive tract. *Theriogenology*, 21, 485-494, 1984. DOI: 10.1016/0093-691X(84)90410-2
4. Fissore RA, Edmondson AJ, Pashen RL, Bondurant RH: The use of

- ultrasonography for the study of the bovine reproductive tract. II. Non-pregnant, pregnant and pathological conditions of the uterus. *Anim Reprod Sci*, 12, 167-177, 1986. DOI: 10.1016/0378-4320(86)90037-0
- 5. Pierson RA, Ginther OJ:** Ultrasonographic appearance of the bovine uterus during the estrous cycle. *J Am Vet Med Assoc*, 190, 995-1001, 1987.
- 6. Pierson RA, Adams GP:** Computer-assisted image analysis, diagnostic ultrasonography and ovulation induction: Strange bedfellows. *Theriogenology*, 43, 105-112, 1995. DOI: 10.1016/0093-691X(94)00014-L
- 7. Singh J, Pierson RA, Adams GP:** Ultrasound image attributes of the bovine corpus luteum: Structural and functional correlates. *J Reprod Fertil*, 109, 35-44, 1997. DOI: 10.1530/jrf.0.1090035
- 8. Zagzebski JA:** Physics of diagnostic ultrasound. In, Zagzebski JA (Ed): *Essentials of Ultrasound Physics*. 1-19, Mosby Year Book Inc, St. Louis, 1996.
- 9. Griffin PG, Ginther OJ:** Research application of ultrasonic imaging in reproductive biology. *J Anim Sci*, 70, 953-972, 1992. DOI: 10.2527/1992.703953x
- 10. Singh J, Adams GP, Pierson RA:** Promise of new imaging technologies for assessing ovarian function. *Anim Reprod Sci*, 78, 371-399, 2003. DOI: 10.1016/S0378-4320(03)00100-3
- 11. Gabor G, Sasser RG, Kastelic JP, Mezes M, Falkay G, Bozo S, Csik JV, Barany I, Hidas A, Jr Szasz F, Boros G:** Computer analysis of video and ultrasonographic images for evaluation of bull testes. *Theriogenology*, 50, 223-228, 1998. DOI: 10.1016/S0093-691X(98)00129-0
- 12. Vassena R, Adams GP, Mapletoft RJ, Pierson RA, Singh J:** Ultrasound image characteristics of ovarian follicles in relation to oocyte competence and follicular status in cattle. *Anim Reprod Sci*, 76, 25-41, 2003. DOI: 10.1016/S0378-4320(02)00234-8
- 13. Davies KL, Bartlewski PM, Pierson RA, Rawlings NC:** Computer assisted image analyses of corpora lutea in relation to peripheral concentrations of progesterone: A comparison between breeds of sheep with different ovulation rates. *Anim Reprod Sci*, 96, 165-175, 2006. DOI: 10.1016/j.anireprosci.2005.12.003
- 14. Liu X, Dai Q, Hart EJ, Barrett DMW, Rawlings NC, Pierson RA, Bartlewski PM:** Ultrasonographic characteristics of ovulatory follicles and associated endocrine changes in cyclic ewes treated with medroxyprogesterone acetate (MAP)-releasing intravaginal sponges and equine chorionic gonadotropin (eCG). *Reprod Domest Anim*, 42, 393-401, 2007. DOI: 10.1111/j.1439-0531.2006.00798.x
- 15. Ginther OJ:** How ultrasound technologies have expanded and revolutionized research in reproduction in large animals. *Theriogenology*, 81, 112-125, 2014. DOI: 10.1016/j.theriogenology.2013.09.007
- 16. Schmauder S, Weber F, Kiossis E, Bollwein H:** Cyclic changes in endometrial echotexture of cows using a computer-assisted program for the analysis of first- and second-order grey level statistics of B Mode ultrasound images. *Anim Reprod Sci*, 106, 153-161, 2008. DOI: 10.1016/j.anireprosci.2007.12.022
- 17. Kauffold J, Von Dem Bussche B, Failing K, Wehrend A, Wendt M:** Use of B-mode ultrasound and grey-scale analysis to study uterine echogenicity in the pig. *J Reprod Dev*, 56, 444-448, 2010. DOI: 10.1262/jrd.09-220T
- 18. Kucukaslan I:** Evaluation of endometrial echostructure following Lotagen® administration in cows with chronic endometritis. *PhD Thesis*, Institute of Health Sciences, Ankara University, 2010.
- 19. Cengiz M, Kanca H, Salar S, Bastan A, Kucukaslan I, Alkan H, Karakas K, Yuksel O, Hayirli A:** Endometrial echotexture parameters in Turkish Saanen Goats (Akkeci) during oestrus and early pregnancy. *Anim Reprod Sci*, 146, 27-33, 2014. DOI: 10.1016/j.anireprosci.2014.02.004
- 20. Herzog K, Kiossis E, Bollwein H:** Examination of cyclic changes in bovine luteal echotexture using computer-assisted statistical pattern recognition techniques. *Anim Reprod Sci*, 106, 289-297, 2008. DOI: 10.1016/j.anireprosci.2007.05.004
- 21. Noseir WMB, Sosa GAM:** Treatment of ovarian cysts in Buffaloes with emphasis to echotexture analysis. *J Dairy Vet Anim Res*, 2 (2): 1-7, 2015. DOI: 10.15406/jdvar.2015.02.00030
- 22. Polat B, Cengiz M, Cannazik O, Çolak A, Oruç E, Altun S, Salar S, Baştan A:** Endometrial echotexture variables in postpartum cows with subclinical endometritis. *Anim Reprod Sci*, 155, 50-55, 2015. DOI: 10.1016/j.anireprosci.2015.01.015
- 23. Scully S, Evans ACO, Carter F, Duffy P, Lonergan P, Crowe MA:** Ultrasound monitoring of blood flow and echotexture of the corpus luteum and uterus during early pregnancy of beef heifers. *Theriogenology*, 83, 449-458, 2015. DOI: 10.1016/j.theriogenology.2014.10.009
- 24. Cengiz M, Çolak A, Hayirli A, Cannazik O:** Optical density changes in ultrasonographic images of the endometrium and corpus luteum in pregnant and cyclic cows. *Turk J Vet Anim Sci*, 41, 18-24, 2017. DOI: 10.3906/vet-1604-41
- 25. Kenney RM, Ganjam VK:** Selected pathological changes of the mare uterus and ovary. *J Reprod Fertil Suppl*, 23, 335-339, 1975.
- 26. Ley WB, Higbee RG, Holyoak GR:** Laser ablation of endometrial and lymphatic cysts. *Clin Tec Equine Pract*, 1 (1): 28-31, 2002. DOI: 10.1053/ctep.2002.33174
- 27. McDowell KJ, Sharp DC, Grubaugh W, Thatcher WW, Wilcox CJ:** Restricted conceptus mobility results in failure of pregnancy maintenance in mares. *Biol Reprod*, 39, 340-348, 1988. DOI: 10.1095/biolreprod39.2.340
- 28. Erdoğan G, Küçük N, Kanca H, Aksoy M:** *In vivo* and *in vitro* assessment of ovarian echotexture through computer assisted real time ultrasonography in bitches. *Ankara Üniv Vet Fak Derg*, 64, 171-176, 2017.
- 29. Ginther OJ:** The single embryo. Ultrasonic imaging and reproductive events in the mare. Cross Plains, Wis: Equiservices, 212-213, 1986.
- 30. Bracher V, Mathias S, Allen WR:** Videoendoscopic evaluation of the mare's uterus: II. Findings in subfertile mares. *Equine Vet J*, 24, 279-284, 1992. DOI: 10.1111/j.2042-3306.1992.tb02835.x
- 31. Bilkslager AT, Tate LP, Weinstock D:** Effects of neodymium:yttrium aluminum garnet laser irradiation on endometrium and on endometrial cysts in six mares. *Vet Surg*, 22, 351-356, 1993. DOI: 10.1111/j.1532-950X.1993.tb00411.x
- 32. Tannus RJ, Thun R:** Influence of endometrial cysts on conception rate of mares. *Zentralbl Veterinarmed A*, 42, 275-283, 1995. DOI: 10.1111/j.1439-0442.1995.tb00378.x
- 33. Wilson GL:** Equine hysteroscopy: equipment for diagnostic endoscopy and photography. *Vet Med*, 80, 76-88, 1985.
- 34. Adams GP, Kastelic JP, Bergfeldt DR, Ginther OJ:** Effect of uterine inflammation and ultrasonically-detected uterine pathology on fertility in the mare. *J Reprod Fertil Suppl*, 35, 445-454, 1987.
- 35. Ragon AC:** Diagnosis and management of uterine cysts. *Proceedings American College of Theriogenologists and Society for Theriogenology Mare Reproduction Symposium*. August, Hastings, Neb, 21-26, 1996.
- 36. Griffin RL, Bennett SD:** Nd:YAG laser photoablation of endometrial cysts: A review of 55 cases (2000-2001). *Proceedings AAEP*, Orlando, Fla, 48, 58-60, 2002.
- 37. Bertmann J, Diaz L, Weber F, Stolla R, Bollwein H:** Changes in uterine blood flow and endometrial echostructure during the early pregnancy of cows. *Wiener Tierärzt Monat*, 91, 11, 2004.
- 38. Pierson RA, Ginther OJ:** Ultrasonic evaluation of the preovulatory follicle in the mare. *Theriogenology*, 24, 359-368, 1985. DOI: 10.1016/0093-691X(85)90228-6
- 39. Tom JW, Pierson RA, Adams GP:** Quantitative echotexture analysis of bovine corpora lutea. *Theriogenology*, 49, 1345-1352, 1998. DOI: 10.1016/S0093-691X(98)00081-8
- 40. Siqueira LGB, Torres CAA, Amorim LS, Souza ED, Camargo LSA, Fernandes CAC, Viana JHM:** Interrelationships among morphology, echotexture, and function of the bovine corpus luteum during the estrous cycle. *Anim Reprod Sci*, 115 (1-4): 18-28, 2009. DOI: 10.1016/j.anireprosci.2008.11.009
- 41. Bonafos LD, Kot K, Ginther OJ:** Physical characteristics of the uterus during the bovine estrous cycle and early pregnancy. *Theriogenology*, 43, 713-721, 1995. DOI: 10.1016/0093-691X(95)00014-Y
- 42. Griffin PG, Ginther OJ:** Dynamics of uterine diameter and endometrial morphology during the estrous cycle and early pregnancy in mares. *Anim Reprod Sci*, 25, 133-142, 1991. DOI: 10.1016/0378-4320(91)90038-2
- 43. Ginther OJ:** Tubular genitalia. In, Ginther OJ (Ed): *Ultrasonic Imaging and Animal Reproduction*. 105-128, Equiservices Publishing, Cross Plains, USA, 1988.
- 44. Simoes J, Almeida JC, Baril G, Azevedo J, Fontes P, Mascarenhas R:** Assessment of luteal function by ultrasonographic appearance and measurement of corpora lutea in goats. *Anim Reprod Sci*, 97, 36-46, 2007. DOI: 10.1016/j.anireprosci.2006.01.006
- 45. Arashiro EK, Fonseca JF, Siqueira LGB, Fernandes CA, Brandao FZ, Oba E, Viana JH:** Assessment of luteal function in goats by ultrasonographic image attribute analysis. *Small Ruminant Res*, 94, 176-179, 2010. DOI: 10.1016/j.smallrumres.2010.07.007