

RESEARCH ARTICLE

The Effects of Animal-Related and Environmental Factors on Feline Entropion: A Comprehensive Cohort Study of 272 Eyes

İrem ERGİN¹  Sumeyye SAİNKAPLAN²  Aslı UYGUR²  Oytun Okan ŞENEL^{1(*)} ¹ Ankara University, Faculty of Veterinary Medicine, Surgery Department, TR-06070 Ankara - TÜRKİYE² Ankara University, Graduate School of Health Sciences, TR-06070 Ankara – TÜRKİYE**(*) Corresponding author:**

Oytun Okan ŞENEL

Phone: +90 312 317 0305

Fax: +90 312 316 4472

E-mail: oytunsenel@gmail.com

How to cite this article?

Ergin İ, Sainkaplan S, Uygur A, Şenel

OO: The effects of animal-related and

environmental factors on feline entropion:

A comprehensive cohort study of 272 eyes.

Kafkas Univ Vet Fak Derg, 31 (2): 189-196,

2025.

DOI: 10.9775/kvfd.2024.33011

Article ID: KVFD-2024-33011

Received: 17.09.2024

Accepted: 31.12.2024

Published Online: 02.01.2025

INTRODUCTION

The eyelids comprise an outer dermal surface facing outward, a conjunctival surface facing the eye, and various muscle groups, serving to directly shield the eyes from external elements. They are anatomically specialized with a tarsus, providing a thick structure extending along the orbital septum. Orbicularis oculi, the major muscle in its structure, is responsible for the movement of the eyelids. The medial and lateral attachments of the orbicularis oculi muscle maintain the elliptical shape of the palpebral space and prevent it from becoming circular during contraction. An excessive increase in muscle tone that may occur for different reasons is called blepharospasm and is one of the important factors that can result in entropion^[1].

Entropion is an eyelid deformation characterized by the inward rolling of the lower and/or upper eyelid margin towards the globe of the eye, encompassing either the lateral, medial, or complete extent of the eyelid^[2]. It is more common in dogs and widely reported in

Abstract

This study aims to provide a general perspective on entropion in cats, while offering a detailed assessment of the animal and environmental factors that may play a role in its occurrence. The study encompassed 170 cats diagnosed with entropion from a cohort of 648 cats that were presented with complaints of blepharospasm between 2020 and 2024. The signalment, history, and ophthalmic examinations were recorded. Eyelid deformities were evaluated based on the eye's location, position and the degree of the lid's rotation. A total of 170 cats were diagnosed with entropion in 272 eyes. The prevalence was significantly higher in brachycephalic cats (78.2%). Entropion was found to have a higher prevalence in male cats (90.58%). In the history, it was determined that 64.1% of the cases had been exposed to irritants. Entropions were located laterally (n=58), medially (n=1) and totally (n=213). Lid's rotation was graded as mild in 76 eyes, moderate in 35 eyes, and severe in 161 eyes. Our study findings emphasize that entropion remains a significant concern in brachycephalic cats. Environmental factors that may cause eye irritation and ocular conditions should be considered. The noticeable male predominance observed in the study also raises questions about whether orbicularis muscle laxity might be associated with gender.

Keywords: Brachycephalic, Cat, Environmental factors, Eyelid, Muscle laxity

the veterinary literature^[3]. Nevertheless, it has been contended in previous studies that this conclusion cannot be unequivocally determined solely by examining the number of affected animals in the population and the prevalence of the disease. For instance, observations regarding entropion in cats have mostly been highlighted in comprehensive examinations of eye diseases^[4]. It is noted that there is a considerable paucity of studies concerning the prevalence and incidence of entropion in cats. In these studies, the most affected cat breeds are Domestic Shorthair, Persians, Maine Coon, and British Blues/Shorthair^[3,5,6].

Entropion is categorized into two main groups: primary (conformational) and secondary (spastic) entropion. The formation of primary entropion is influenced by factors such as the length of the palpebral aperture, structure of the skull, orbital morphology, gender, and skin laxity. Conversely, secondary entropion may result from severe and prolonged blepharospasm following painful ocular



conditions such as distichiasis, keratitis, corneal ulcers, and severe irritability conjunctivitis. Additionally, it may occur as a consequence of scar tissue formation following direct trauma to the eyelids or due to alterations in globe position or size (microphthalmos) [3,7,8]. This study aims to provide a general perspective on entropion in cats, while offering a detailed assessment of the animal and environmental factors that may play a role in its occurrence.

MATERIAL AND METHODS

Ethical Statement

The required ethics committee report for the study was obtained from Animal Experiments Local Ethics Committee of Ankara University (Approval No: 2024-08-65.). An "Informed Consent Form" was obtained from the animal owners before examination of animals.

Study Design

The study encompassed 170 cats diagnosed with entropion from a cohort of 648 cats of various breeds, ages, and genders that were presented to the Ankara University Faculty of Veterinary Medicine Animal Hospital Ophthalmology Clinic with complaints of blepharospasm between January 2020 and January 2024. After taking a detailed history and an ophthalmic examination involving direct ophthalmoscopy, slit-lamp biomicroscopy and fluorescein staining were performed on all cats.

Eyelid deformities were evaluated based on the position of the eyelid and the degree of rotation of the lid towards the eye. The evaluation of eyelid position was conducted in terms of the medial canthus, lateral canthus and entire eyelid. The degree of rotation was graded according to the severity of entropion: An inward rotation of approximately 45° on the lid was termed as mild entropion, while a rotation of 90° was classified as moderate entropion, and a rotation of 180° was characterized as severe entropion [9]. Simultaneously, a comprehensive examination of the eye and its surrounding tissues was performed.

Based on the anamnesis taken from the patient owners, it was suggested to eliminate the factors thought to cause eye irritation. In cases where another ocular condition coexisted with entropion, appropriate treatment for the concurrent disease was administered. Throughout the management process, all animals were prescribed Elizabethan collars and hyaluronic acid eye lubricants. In cases of severe corneal ulcers, analgesia was achieved by administering cyclopentolate eye drops two times daily. Owners were instructed to gently massage the folded eyelid downward with their thumb for this purpose. Surgical intervention was conducted in cases where entropion persisted beyond the first week.

General anesthesia was induced with propofol to perform oro-tracheal intubation and maintained with isoflurane via a circle breathing system. Animals were treated surgically with Hotz Celsus procedure used. The edge of the eyelid, which was inwardly folded towards the eye, was repositioned to its normal anatomical position by pulling it downward. After marking the tissue to be excised with forceps, the width of the tissue to be removed was determined, and the skin and a thin strip of the orbicularis muscle were carefully excised with Stevens tenotomy scissors. Single interrupted skin sutures were then used to close the Hotz-Celsus incisions with suture material 5/0 polyglactin 910 (Fig. 1). In all animals, the sutures were removed on the 10th day, and the Elizabethan collar was removed on the 12th day.

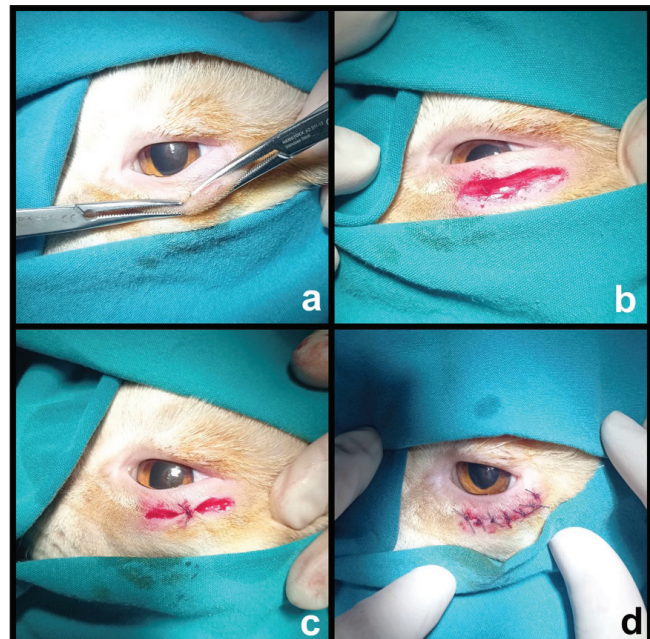


Fig 1. In the Hotz-Celsus procedure, the eyelid was repositioned to its normal anatomical position by pulling it downward. The tissue to be excised was marked with forceps, and the width of the tissue to be removed was determined (a). The skin and a thin strip of the orbicularis muscle were carefully excised using Stevens tenotomy scissors (b). Single interrupted skin sutures were then applied to close the incisions (c, d)

Statistical Analysis

The data were examined using the Pearson chi-square test to assess the statistical significance of differences in entropion incidence rates. A criterion of $P < 0.05$ was used for all statistical comparisons. Data analysis was conducted using SPSS 27 software package.

RESULTS

In the study, 648 cats complaining of blepharospasm were categorized as brachycephalic ($n=253$) and non-brachycephalic, with the latter group including other pedigree cats ($n=38$) and non-purebred cats ($n=357$) (Table 1). Entropion was diagnosed in 26.2% (170/648)

Table 1. Cat breeds presented with complaints of blepharospasm caused by various eye problems.

Cat Breeds		Number of Animals
Brachycephalic breeds	Bombay	1
	British Longhair	18
	British Shorthair	126
	Burmese	1
	Chinchilla Persian	1
	Exotic Shorthair	6
	Persian	26
	Scottish Fold	53
	Scottish Fold Longhair	5
	Scottish Fold Shorthair	14
	Selkirk Rex	2
Non-brachycephalic breeds	<i>Pedigree cats</i>	
	American Shorthair	2
	Turkish Angora	8
	Maine coon	1
	Norwegian Forest	1
	Russian Blue	2
	Siamese	9
	Siberian	1
	Somali	1
	Sphynx	5
	Turkish Van	9
<i>Non-purebreed cats</i>		
Mix	356	
Total		648

Table 2. Distribution of entropion in brachycephalic and non-brachycephalic cat breeds ($P<0.001$)

Cat Breeds	Entropion (+) Group		Entropion (-) Group		Total
	n	%	n	%	n
Brachycephalic	133	52.60	120	47.40	253
Non-Brachycephalic	37	9.40	358	90.60	395
Total	170	26.23	478	73.77	648

of the cats evaluated. Of the 170 cats diagnosed with entropion, 78.2% (133/170) were identified as being of brachycephalic breeds. Upon examination, the incidence rate of entropion in brachycephalic breeds was found to be statistically significantly higher than in non-brachycephalic breeds ($P<0.001$) (Table 2).

Observations revealed that the mean age of entropion cases was 3.12 ± 2.52 years old, with entropion exhibiting a higher prevalence (90.58%) in male cats during gender assessment. It was reported that 1.9% of the cats had been neutered before. Additionally, upon examining a total population of 648 cats presenting with blepharospasm, consisting of 176 males and 472 females, it was notably observed that 87.5% of the male cats were diagnosed with entropion.

All owners reported that their pets exhibited squinting for varying durations before the onset of entropion. In the

history, it was determined that 64.1% of the cases had been exposed to irritants such as perfume, bleach, smoke, and cat litter. Entropion developed in 7 animals affected by viral conjunctivitis (Table 3). In these animals, herpesvirus antigen test was detected positive in the samples taken from the tears. When the duration of complaints reported by animal owners and the potential causative factors influencing the severity of entropion were evaluated, no significant relationship was found.

Entropion evaluation was conducted on 272 eyes of the 170 cats included in the study. The animals had been diagnosed with primary unilateral ($n=70$) or bilateral ($n=100$) eyelid entropion. It was observed in the upper eyelids in 3 cats and in the lower eyelids in all other cats. Entropions were located laterally in 58 eyes, medially in 1 eye and along the totally margin in 213 eyes (Fig. 2). According to the severity of entropion, it was graded as mild in 76 eyes,

Table 3. Distribution of anamnesis and clinical examination findings in brachycephalic and non-brachycephalic cats with entropion. N/A: Complaint period unknown.		
Anamnesis and Clinical Findings	Brachycephalic Breeds (n)	Non-brachycephalic Breeds (n)
History		
Smoke	9	2
Parfume	13	4
Bleach	15	1
Litter	48	17
Idiopathic	39	11
FHV-1	6	1
Others (senil, palpebral deformity, postvaccination)	1	3
Duration		
up to 2 weeks	22	5
2-4 weeks	27	2
more than 4 weeks	25	10
N/A	59	20
Ophthalmological evaluation		
Corneal ulceration	93	7
Corneal necrosis	18	5
Corneal ulceration+necrosis	6	1
Corneal necrosis+eosinophilic keratitis	1	-
Conjunctivitis	55	9
Corneal scar	-	2
Blepharitis	4	-
Eosinophilic keratitis	1	-
Epiphora	45	19
Symblepharon	-	2
Third eyelid protrusion	2	-
Microphthalmia, palpebral deformation	-	2
Eyelid evaluation		
Location	Right: 29	Right: 17
	Left: 20	Left: 6
	Bilateral: 82	Bilateral: 16
Grade	Mild: 60	Mild: 16
	Moderate: 26	Moderate: 9
	Severe: 131	Severe: 30
Position of entropion	Laterally: 45	Laterally: 13
	Medially: 1	Medially: -
Total	188	25
Treatment		
Massage	53	23
Surgery	76	18

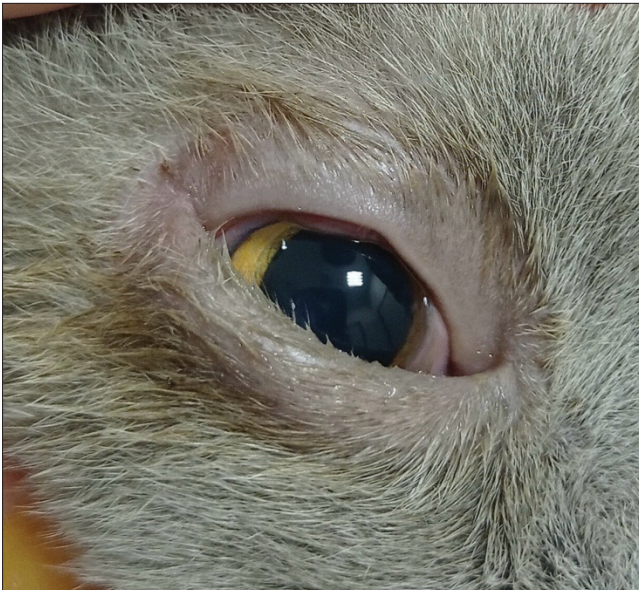

Fig 2. Entropion in the lower eyelid of the right eye in a 1-year-old male Scottish Fold cat. It was located totally

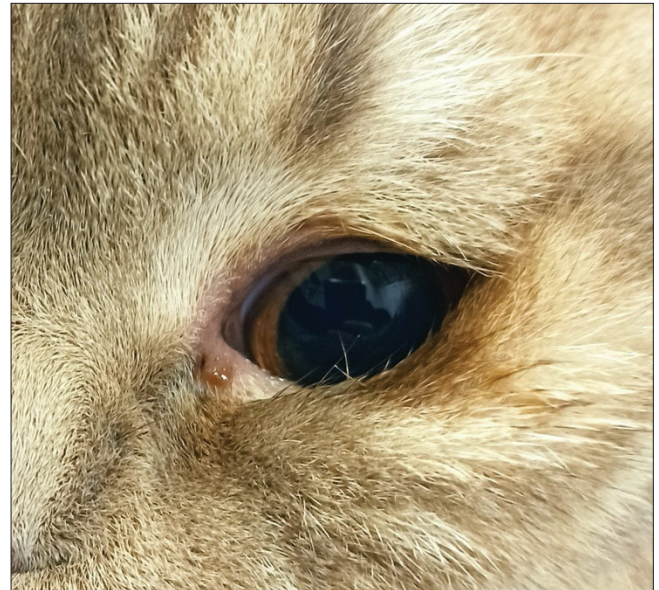

Fig 3. Severe entropion in the lateral lower eyelid with more than 180 degrees of rotation in a 1-year-old male British Shorthair

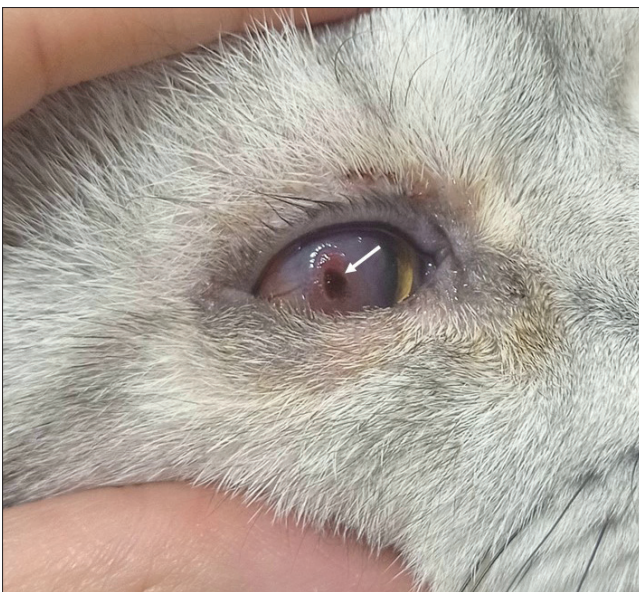

Fig 4. Severe keratitis and corneal ulceration accompanied by entropion were observed in a one-year-old British Shorthair cat. Central corneal necrosis was evident within the lesion (*arrow*)

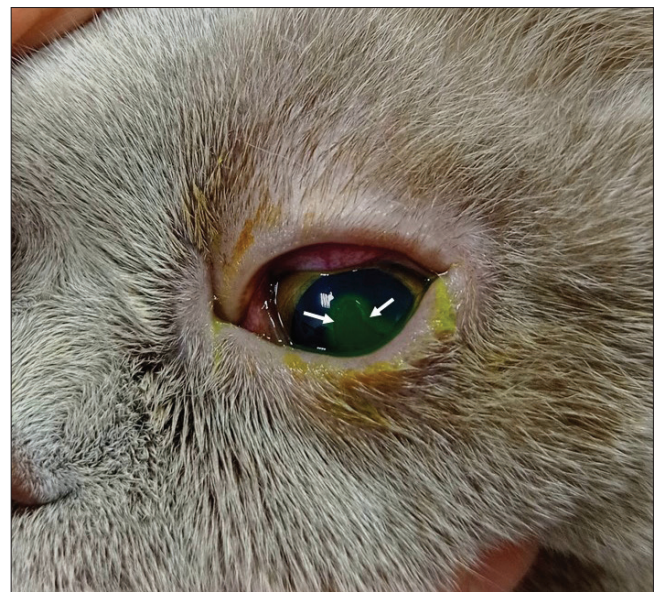

Fig 5. Based on the anamnesis, conjunctivitis secondary to entropion and a large, deep ulcer at the center of the cornea were noted. The ulcerated area tested positive with fluorescein staining (*arrows*)

moderate in 35 eyes, and severe in 161 eyes (*Fig. 3*). In the ophthalmological examination, corneal ulceration was the most common finding, observed in 36.7% of cases. A positive fluorescein test was observed in all of these animals. Conjunctivitis and epiphora were the second most common findings, each occurring in 23.5% of cases (*Fig. 4, Fig. 5*) (*Table 3*). All procedures were carried out by the same clinicians. While no complications occurred in animals that underwent surgical intervention, the average follow-up period was determined as 3 months.

DISCUSSION

Cats are categorized into dolichocephalic, mesocephalic, and brachycephalic breeds based on the shape and structure of their skulls. Brachycephalic cat breeds have various malformations such as stenotic nares, shortening of the nasal bone and severe joint and bone deformities. They are characterized by their rounded, full skull and cheeks. The eyes are large and round, set wide apart ^[10]. Brachycephalic cats have been reported to be more

prone to eye-related problems such as keratitis, corneal ulceration^[11], corneal sequestra^[12,13] and entropion^[6]. Among inherited and hereditary ocular abnormalities, entropion is highly prevalent in brachycephalic breeds^[14]. According to Anagrius, the reason for this condition might be the nasal skin which is extending over the upper edge of the lower eyelid in brachycephalic breeds. The fact that all cases of entropion in their study results were formed in the medial part of the lower eyelid supports this condition^[15]. However, upon reviewing our study results, it was notable that the number of eyes with entropion located just medially was only 1, with the majority being located totally (213/272). The current study findings revealed that the cat breed most affected by entropion is brachycephalic breeds. The observation of entropion being most prevalent in British Shorthair cats within this group suggested a potentially higher susceptibility to entropion in this breed. Although there are numerous entropion studies, it is noteworthy that Scottish Fold cats are rarely mentioned^[3,5]. However, the second brachycephalic breed in which entropion was most commonly observed in the present study was the Scottish Fold. It is evident that the significant brachycephalic cat population in the study material was predisposed to entropion. However, it cannot be attributed solely to a single factor.

Spastic entropion is most commonly observed in cats. In situations that irritate the eye, the animal's persistent squinting due to pain leads to spasms in the orbicularis oculi muscle, resulting in spastic entropion^[7]. When ocular conditions associated with entropion were examined in this study, the most notable were corneal ulceration (34.1%) and conjunctivitis (23.5%). However, it could not be definitively determined whether these spastic components were the cause of entropion or if the trauma to the cornea and conjunctiva was a result of the hairs on the inward-rolling eyelids and the animal's scratching due to irritation. This uncertainty stems from the anamnesis provided by the patient owners, which revealed that these animals had been exposed to eye-irritating substances for varying periods. Therefore, it was not possible to definitively identify the primary factor causing blepharospasm in these cases.

When assessing the impact of age on eyelid structures, particular attention should be drawn to the laxity that occurs in the lower eyelid. As age progresses, there is a decrease in the volume of the tissue surrounding the eyeball. The decrease in tissue volume, combined with the accelerated increase in laxity, ultimately disturbs the equilibrium between the surface of the eyeball and the eyelid, resulting in alterations to the normal anatomical positioning of the lid^[16]. The vertical and horizontal laxity in the lower eyelid results in the preseptal orbicularis oculi muscle overriding the pretarsal orbicularis oculi muscle,

leading to the formation of entropion in the lower eyelid^[17]. This condition, associated with age in animals, is defined as senile entropion. However, upon evaluating the average age of the study group, it was deemed necessary to explore alternative etiologies for the cause of muscle laxity.

When the orbicularis oculi muscle contracts, it narrows the palpebral opening by pulling on the lateral and medial commissures horizontally. The levator palpebrae superioris muscle, Müller's muscle, which is closely associated with it, and the smaller levator anguli oculi medialis muscles raise the upper lid and malaris muscle depresses the lower eyelid to enlarge the eye opening^[1]. In human, the most significant factor in the development of entropion is the difference in tension between the orbicularis oculi and malaris muscles. The malaris muscle spreads as a thin muscle to insert on the ventral orbicularis oculi muscle, and functions to move the lower eyelid downward. Excessive contraction of one muscle group while the other relaxes leads to the onset of entropion^[18]. In this scenario, it is imperative to investigate the factors contributing to tension disparities in the eyelids and surrounding musculature, which can lead to entropion. The study observed that blepharospasm, manifested at varying severities, was a common clinical finding in all cats presenting with entropion. According to Lin, in human, horizontal laxity in the eyelid and laxity in the lower eyelid retractors, which pull the lower edge of the tarsus downward and backward, can cause a deterioration in the normal tension of the eyelids, leading them to turn inward toward the eye. The rotation of the skin and eyelashes, in conjunction with the movement of the eyelids, worsens blepharospasm, thereby aggravating entropion^[19]. Although human and cat eyelid anatomy is not exactly similar, both species' retractor muscles of the upper eyelid, which possess a large surface area, are notably strong. Conversely, the lower eyelid features the weaker and more superficial retractor muscle. Considering this anatomical structure, the area most sensitive to the effects of blepharospasm is the lower eyelid in cats, just like in humans, due to its weaker structure. Indeed, the results of the study reflect this, as entropion occurred in only 3 eyes in the upper eyelid, while nearly all cases were observed in the lower eyelid.

Although muscle laxity appears to be linked to long-term blepharospasm, our study could not establish a direct and significant relationship between the duration and cause of the complaint and the severity of blepharospasm and entropion. This suggests the possibility of an alternative cause that triggers laxity in the orbicularis muscles, which may also influence the severity of entropion. It is noteworthy that 90.58% of the cats in this study were male. Similarly, a study by Bott et al.^[5] found that entropion was most frequently observed in male cats,

though no statistically significant data were obtained. The relationship between hormones and muscles has been extensively studied in both human and veterinary medicine. Numerous studies have demonstrated that androgen receptors within the muscles play a significant role in the volume and functional alterations of various muscle groups. For instance, the pathogenesis of perianal hernias observed in intact male dogs has been attributed to the relaxin hormone secreted by the prostate gland, which induces laxity in the muscles of this area. Research results have shown that hypertrophy, especially in the prostate gland, increases relaxin release, causing local muscle atrophy and deterioration in connective tissue components. Relaxin hormone receptors were identified extensively in muscle samples obtained from dogs with perineal hernia [20]. Similarly, it has been known for years that estrogen and androgen receptors are effective in striated muscle functions. It achieves this effect by protecting myoblasts and suppressing atrophy pathways [21]. Experimental studies have demonstrated that a decrease in the presence of androgen and estrogen receptors leads to a reduction in the number of muscle fibers, particularly in tissues containing type II muscle fibers, and results in tissue atrophy [22,23]. In their clinical study involving patients with entropion, Cabuk et al. [24] proposed that the reduction in muscle fibers and consequent deformation observed in the orbicularis oculi muscles of these patients, which predominantly consist of type II muscle fibers, might be attributed to a decrease in androgen receptors. Estrogen receptors were entirely absent in male patients with blepharospasm, whereas they were present in the control group. Additionally, a decrease in both hormone receptors was observed in female patients with blepharospasm. When entropion was assessed in neutered cats in the present study, no clinical difference could be discerned regarding its localization on the eyelid or its severity. However, the excess male population in the study may suggest a potential association between eyelid deformities in animals and gender, possibly related to androgen hormones. This aspect could serve as an evaluative parameter for future studies.

The primary focus in the treatment of spastic entropion is to reduce or eliminate painful ocular conditions before the permanent surgical corrections [7]. In the study, it was observed that entropion regressed in many cases (44.7%) without surgical intervention by adding eyelid massage to the elimination of environmental irritants and medical treatment of eye conditions.

As a result, the increased popularity of brachycephalic cat breeds has led to a rise in the incidence and prevalence of numerous diseases and deformities specific to these animals. Our study findings emphasize that entropion remains a significant concern in brachycephalic cats.

Potential predisposing factors for entropion have been examined; environmental factors that may cause eye irritation, as well as various ocular conditions, should be considered. The noticeable male predominance observed in the study also raises questions about whether orbicularis muscle laxity might be associated with gender. Further research on this topic is necessary.

DECLARATIONS

Availability of Data and Materials: The data that support the findings of this study are available on request from the corresponding author (O.O. Şenel).

Acknowledgment: Thanks to Prof. Dr. Aytaç Akçay for his help with the statistical analysis.

Funding Support: This research did not receive any specific grant from funding agencies in the public, commercial, or not-for-profit sectors.

Ethical Statement: The required ethics committee report for the study was obtained from Animal Experiments Local Ethics Committee of Ankara University (Approval No: 2024-08-65).

Conflict of Interest: The authors declare that there were no conflicts of interest.

Declaration of Generative Artificial Intelligence (AI): The authors declare that the article, tables and figures were not written/created by AI and AI-assisted Technologies.

Authors' Contributions: İ.E.: Conceptualization, data curation, investigation, methodology, writing-original draft, writing-review and editing, project administration. S.S.: Data curation, investigation, writing-review and editing. A.U.: Data curation, writing-original draft. O.O.Ş.: Conceptualization, writing-review and editing, supervision.

REFERENCES

1. Dyce KM, Sack WO, Wensing CJG: The locomotor apparatus. In, Textbook of Veterinary Anatomy. 4th ed., 32-99, Saunders Elsevier, St. Louis, 2010.
2. Glaze MB, Maggs DJ, Plummer CE: Feline ophthalmology. In, Gelatt KN, Ben-Shlomo G, Gilger BC (Eds): Veterinary Ophthalmology. 6th ed., 1665-1840, John Wiley & Sons, Mississipi, 2021.
3. White JS, Grundon RA, Hardman C, O'Reilly A, Stanley RG: Surgical management and outcome of lower eyelid entropion in 124 cats. *Vet Ophthalmol*, 15 (4): 231-235, 2012. DOI: 10.1111/j.1463-5224.2011.00974.x
4. Williams DL, Kim JY: Feline entropion: A case series of 50 affected animals (2003-2008). *Vet Ophthalmol*, 12 (4): 221-226, 2009. DOI: 10.1111/j.1463-5224.2009.00705.x
5. Bott, MM, Chahory S: Epidemiology and clinical presentation of feline presumed hereditary or breed-related ocular diseases in France: Retrospective study of 129 cats. *J Feline Med Surg*, 24 (12): 1274-1282, 2022. DOI: 10.1177/1098612X221080598
6. Schipper T, Storms G, Janssens G, Schoofs S, Capiou E, Verdonck D, Smets P, Peelman LJ, Broeckx BJG: Genetic aspects of corneal sequestra in a population of Persian, Himalayan and exotic cats. *Animals (Basel)*, 12 (15):2008, 2022. DOI: 10.3390/ani12152008
7. Maggs DJ: Eyelids. In, Maggs DJ, Miller PE, Ofri R (Eds): Slatter's Fundamentals of Veterinary Ophthalmology. 5th ed., 107-134, Saunders Elsevier, St. Louis, 2008.
8. Read RA, Broun HC: Entropion correction in dogs and cats using a combination Hotz-Celsus and lateral eyelid wedge resection: Results

in 311 eyes. *Vet Ophthalmol*, 10 (1): 6-11, 2007. DOI: 10.1111/j.1463-5224.2007.00482.x

9. Stades FC, Woerd A: Canine eyelids: Diseases and surgery. In, Gelatt KN (Ed): *Essentials of Veterinary Ophthalmology*. 6th ed., 163-185, Wiley Blackwell, New Jersey, 2014.

10. WCF: The World Cat Federation. <https://wcf.de/en/#>; Accessed: 27.11.2024.

11. Park J, Kang S, Lee E, Seo K: Prevalence of feline ophthalmic disorders in South Korea: A retrospective study (2009-2021). *J Feline Med Surg*, 25 (2): 1-11, 2023. DOI: 10.1177/1098612X231151478

12. Ergin I, Senel OO, Koc B: Treatment of feline corneal necrosis by conjunctival flap. *Vet Hek Der Derg*, 87 (1): 44-54, 2016.

13. Demir A, Altundag Y: Comparison of the efficacy of the nictitating membrane flap, conjunctival pedicle flap, and platelet-rich fibrin membrane graft techniques in the surgical management of corneal necrosis in cats: A retrospective study (2016-2020). *Kafkas Univ Vet Fak Derg*, 28 (1): 1-10, 2022. DOI: 10.9775/kvfd.2021.26119

14. Glaze MB: Congenital and hereditary ocular abnormalities in cats. *Clin Tech Small Anim Pract*, 20 (2): 74-82, 2005. DOI: 10.1053/j.ctsap.2004.12.011

15. Anagnrius KL, Dimopoulou M, Moe AN, Petterson A, Ljung All I: Facial conformation characteristics in Persian and Exotic Shorthair cats. *J Feline Med Surg*, 23 (12): 1089-1097, 2021. DOI: 10.1177/1098612X21997631

16. Himmel MR, Enzer YR, Hofmann RJ: Entropion-ectropion: The influence of axial globe projection on lower eyelid malposition. *Ophthalm Plast Reconstr Surg*, 25 (1): 7-9, 2009. DOI: 10.1097/IOP.0b013e31819128fd

17. Michels KS, Czyz CN, Cahill KV, Foster JA, Burns JA, Everman KR:

Age-matched, case-controlled comparison of clinical indicators for development of entropion and ectropion. *J Ophthalmol*, 2014: 231487, 2014. DOI: 10.1155/2014/231487

18. Beigi B: Orbicularis oculi muscle stripping and tarsal fixation for recurrent entropion. *Orbit*, 20 (2): 101-105, 2001. DOI: 10.1076/orbi.20.2.101.2629

19. Lin P, Kitaguchi Y, Mupas-Uy J, Sabundayo MS, Takahashi Y, Kakizaki H: Involitional lower eyelid entropion: Causative factors and therapeutic management. *Int Ophthalmol*, 39, 1895-1907, 2019. DOI: 10.1007/s10792-018-1004-1

20. Gill SS, Barstad RD: A review of the surgical management of perineal hernias in dogs. *J Am Anim Hosp Assoc*, 54 (4): 79-187, 2018. DOI: 10.5326/JAAHA-MS-6490

21. Ventura-Clapier R, Piquereau J, Veksler V, Garnier A: Estrogens, estrogen receptors effects on cardiac and skeletal muscle mitochondria. *Front Endocrinol (Lausanne)*, 10:557 2019. DOI: 10.3389/fendo.2019.00557

22. Altuwajri S, Lee DK, Chuang KH, Ting HJ, Yang Z, Xu Q, Tsai MY, Yeh S, Hanchett LA, Chang HC, Chang C: Androgen receptor regulates expression of skeletal muscle-specific proteins and muscle cell types. *Endocrine*, 25 (1): 27-32, 2004. DOI: 10.1385/endo:25:1:27

23. Ikeda K, Horie-Inoue K, Inoue S: Functions of estrogen and estrogen receptor signaling on skeletal muscle. *J Steroid Biochem Mol Biol*, 191:105375, 2019. DOI: 10.1016/j.jsbmb.2019.105375

24. Cabuk KS, Coban G, Cakır GY, Serefoglu ZS, Nacaroglu SA, Karabulut GO, Fazıl K: Histopathological view of benign essential blepharospasm: Orbicularis oculi hormone receptor levels. *Beyoglu Eye J*, 8 (2): 110-114, 2013. DOI: 10.14744/bej.2023.16779