

RESEARCH ARTICLE

Computed Tomography-Based Morphometric Analysis of the Hip Bones (*Ossa coxae*) in Turkish Van Cats

Osman YILMAZ ^{1,a} (*) İsmail DEMİRCİOĞLU ^{2,b}¹ Department of Anatomy, Faculty of Veterinary Medicine, Van Yüzüncü Yıl University, TR-65080 Van - TURKEY² Department of Anatomy, Faculty of Veterinary Medicine, Harran University, TR-63200 Şanlıurfa - TURKEY
ORCID: ^a 0000-0003-2013-9213; ^b 0000-0002-0724-3019

Article ID: KVFD-2020-24449 Received: 13.06.2020 Accepted: 15.10.2020 Published Online: 21.10.2020

Abstract

This study was carried out to determine the osteometric measurement values of the ossa coxae by using three-dimensional (3D) modeling of the images obtained by computed tomography in Van Cats. In the study, 16 adult Van cats, 8 of which are male ones and 8 female ones, were used. Firstly, cats were anesthetized with the ketamine HCl - xylazine HCl combination. Their images were obtained by scanning through 16 cross-sectional CT devices (Somatom Sensation 16; Siemens Medical Solutions, Erlangen, Germany). Then, The scanned images of the ossa coxae in each cat were transformed into the three-dimensional structure by using MIMICS 20.1 (The Materialise Group, Leuven, Belgium) software program. Later, morphometric (12 linear), volumetric, and surface area measurements were calculated and statistical analyses were performed. In the present study, 12 of 14 measurement parameters of the ossa coxae were higher in males than in females. In the osteometric analysis, it was observed that the greatest length of one half (GL), length between the inner edges of the acetabulum (LA), the greatest breadth across the tuber ischiadicum (GBTi), and the smallest breadth across the bodies of the ischia (SBI) measurement values were significantly greater in male cats than in female cats ($P < 0.05$). The volume and surface area values of the ossa coxae in van cats were found as $12.33 \pm 2.14 \text{ cm}^3$ in male cats and $9.81 \pm 0.71 \text{ cm}^3$ in female cats; $94.66 \pm 11.01 \text{ cm}^2$ in male cats and $83.84 \pm 7.73 \text{ cm}^2$ in female cats, respectively. These differences between the measurement values of male and female cats were seen to be statistically significant ($P < 0.05$). As a result, basic morphometric measurement parameters of ossa coxae between both genders in adult Van cats were determined by using CT and 3D modeling programs. It is thought that the data obtained from this study may be useful in determining the sexual dimorphism of these species and also in determining the clinical applications and scientific studies to be carried out in the region.

Keywords: Computed tomography, Morphometry, Ossa coxae, Three-dimensional reconstruction, Van cat

Türk Van Kedilerinde Kalça Kemiklerinin (*Ossa coxae*) Bilgisayarlı Tomografi Tabanlı Morfometrik Analizi

Öz

Bu çalışma Van kedilerinde ossa coxae'nin bilgisayarlı tomografi (BT) ile elde edilen görüntülerinin üç boyutlu (3B) modellemesini yapmak, osteometrik ölçüm değerlerini belirlemek amacıyla yapıldı. Çalışmada 16 adet (8 erkek, 8 dişi) erişkin Van kedisi kullanıldı. Öncelikle ketamin HCl - xylazin HCl kombinasyonu ile anesteziye alınan kediler, 16 kesit çok sıralı BT cihazı (Somatom Sensation 16; Siemens Medical Solutions, Erlangen, Germany) ile taranarak görüntüleri elde edildi. Daha sonra, her kedinin ossa coxae'sine ait tarama görüntüleri MIMICS 20.1 (The Materialise Group, Leuven, Belgium) programı yardımıyla üç boyutlu yapıya dönüştürülerek, morfometrik (12 doğrusal), hacim ve yüzey alanı ölçümleri alındı ve istatistik analizi yapıldı. *Ossa coxae*'ya ait 14 adet ölçüm parametresinden 12 ölçüm parametresinin erkek kedilerde dişilere göre daha yüksek olduğu belirlendi. Osteometrik analiz sonuçlarına bakıldığında, bir yarımın en büyük uzunluğu (GL), acetabulum'un iç kenarlarının uzunluğu (LA), tuber ischiadicum'ların karşidan karşıya maximum genişliği (GBTi) ve corpus ossis ischii'lerin karşidan karşıya minimum genişliği (SBI) ölçüm değerlerinin erkek kedilerde dişi kedilere göre istatistik olarak anlamlı bir şekilde yüksek olduğu gözlemlendi ($P < 0.05$). Erkeklerde ossa coxae'nin hacim değeri $12.33 \pm 2.14 \text{ cm}^3$, dişilerde $9.81 \pm 0.71 \text{ cm}^3$; yüzey alanı ise erkeklerde $94.66 \pm 11.01 \text{ cm}^2$, dişilerde $83.84 \pm 7.73 \text{ cm}^2$ olarak bulundu. Erkek ve dişi kedilerinin ölçüm değerleri arasında görülen bu farklılıkların istatistik olarak önemli düzeyde olduğu görüldü ($P < 0.05$). Sonuç olarak, erişkin Van kedilerinde ossa coxae'nin temel morfometrik ölçüm parametrelerinin cinsiyetler arasındaki farklılıkları BT ve 3B modelleme programı kullanılarak tespit edildi. Çalışmadan elde edilen bilgilerin, türe ait seksüel dimorfizmin belirlenmesinin yanı sıra bölge ile ilgili yapılacak olan klinik uygulamalara ve bilimsel çalışmalara fayda sağlayacağı düşünülmektedir.

Anahtar sözcükler: Bilgisayarlı tomografi, Morfometri, Ossa coxae, Üç boyutlu rekonstrüksiyon, Van kedisi

How to cite this article?

Yılmaz O, Demircioğlu İ: Computed tomography-based morphometric analysis of the hip bones (*Ossa coxae*) in Turkish Van Cats. *Kafkas Univ Vet Fak Derg*, 27 (1): 7-14, 2021.
DOI: 10.9775/kvfd.2020.24449

(*) Corresponding Author

Tel: +90 432 225 1128 /21537 Fax: +90 432 225 1127

E-mail: osman_40_5@hotmail.com (O. Yılmaz)



This article is licensed under a Creative Commons Attribution-NonCommercial 4.0 International License (CC BY-NC 4.0)

INTRODUCTION

Hip bone or os coxae consists of three bones; os pubis, os ilium, and os ischii. The corpus of these three bones creates a hollow which is called the acetabulum and enables the femur to make a joint with the caput ossis femoris. The pelvis, which is formed by the ossa coxae, on sides right and left, and the symphysis pelvina, occurred by the joining of these bones at the ventral, and also the sacrum and the first few caudal vertebrae (coccygeal) from the dorsal. The cavity surrounded by the bones of the pelvis is the cavum pelvis^[1,2].

When comparing ossa coxae in cats to dogs, some slight differences can be seen. For example; in cats, the ilia get slightly away toward the cranial and the wings of these bones are relatively smaller and shallower, which makes a large passage shaped cone from cavum abdominis to cavum pelvis. The ischial tubers being closer to each other has led to the pelvic being in a more rectangle shape and exit to be more narrow. However, in both species, the axis of the pelvic channel is flat and in general, this enables cats and dogs to give an easier birth^[3]. In addition, pelvic bones and joints they create (articulatio sacroiliaca, articulatio coxae, symphysis pelvina), have more movement space and ability to create versatility in animals such as cats and dogs. It also has tasks such as to provide posture and locomotion of the skeleton, the birth, act of squat or lifting legs during urination in a more comfortable way, scratching the head, neck, and thorax area by means of the hind leg, to transmit the movement starting from hind leg to body, to help determining the movement and posture peculiar to breeds, protecting the organs inside and to enable functions being operated^[4,5].

Today, thanks to available computer-supported technological developments in medical imagining methods and computed tomography (CT) and three-dimensional modeling, significant changes have occurred in treatments and diagnosis of various illnesses and especially in anatomy education^[6]. Computed tomography and three-dimensional reconstruction programs, especially in small animals such as cats and dogs are often used as a standard imaging method in imaging complex anatomical structures such as pelvic and obtaining various morphometric measurements^[7,8], in scanning, treating, and diagnosing various pathological structures such as rectum cancer, colon cancer, prostate in the pelvic cavity, lower urinary tract disorders, glandula bulbourethralis cyst, cervix and ovary carcinomas^[9,10], in studies in the anthropology fields^[11].

Van cat, an endemic cat breed, which lives in the Van region and is named after here is an important part of living culture in the region. It is an important cultural wealth source of the region. In recent years, they have attracted people owing to their physical appearances and especially being included in the endangered species^[5,12]. There are

very few studies about the osteological properties of these animals^[5,13,14]. This study has been carried out to obtain morphometric measurements by making three-dimensional modeling by computed tomography of the ossa coxae in Van cat, to reveal the sexual dimorphism of these measurements and to provide an anatomical reference data in terms of pelvic morphology.

MATERIAL AND METHODS

In the study, a totally, 8 female and 8 male Van cats between the ages of 3 and 8 were used. The cats were obtained from the Van Cat Research and Application Center, Van Yuzuncu Yil University, Turkey. *Ad libitum* drinking water and standard cat forage were given to the cats before the study day. The study was accepted by Van Yuzuncu Yil University Local Ethical Committee of Animal Experiments (decree no: 2020/02 - 27.02.2020).

Van cats involved in the study were not given any food one day before the study by numbering them. A combination of ketamine (15 mg/kg, IM, Ketazol® 10% injectable) and xylazine (1-2 mg/kg, IM, Alfazyne® 2% injectable) was used for cat anesthesia on the examination day.

Available 16 cross-sectional multislice computed tomography (CT) devices (Somatom Sensation 16; Siemens Medical Solutions, Erlangen, Germany) at the Radiology Department of Medicine Faculty at Van Yuzuncu Yil University were used for examination of cats. Cats were symmetrically placed in prone position to be "head first" on "the disposable" quilt laid out in the gantry. CT device parameters used during imagining were given in *Table 1*. CT application dose parameters and performed scanning were carried out based on standard protocols and literature^[15,16]. Obtained images were stored in the DICOM form.

Later, reconstructions of these images were made by conveying them into three-dimensional modeling program MIMICS 20.1 (The Materialise Group, Leuven, Belgium). Osteometric measurements for 12 different parameters from ossa coxae whose modeling were made were obtained. Measurement points stated in the literature were used as a base for morphometric measurements^[17].

Parameter	Value
KV/Effective mAs/Rotation time (sec) values	120/120/0.75
Gantry rotation period	420 ms
Physical detector collimation	16×0.6 mm
Section thickness	0.5 mm
Final section collimation	32×0.63 mm
Feed/rotation	6 mm
Kernel	U90u
Increment	0.5 mm
Resolution	512×512 pixels

Table 2. Measurement points and abbreviations of the ossa coxae in Van cats

Parameter	Abbreviation	Definition
1	GL	Greatest length of one half. Distance between the Tuber coxae and the tuber ischiadicum in one half (mm)
2	LA	Length between the outer edges of the acetabulum: Distance between the front outer edge and the back outer edge of the acetabulum (mm)
3	LAR	Length between the inner edges of the acetabulum: Distance between the front inner edge and the back inner edge of the acetabulum (mm)
4	LS	Length of the pelvic symphysis: Distance between the cranial end and the caudal end of the pelvic symphysis (mm)
5	SH	Smallest height of the shaft of ilium (mm)
6	SB	Smallest breadth of the shaft of ilium (mm)
7	LFo1	Inner length of the foramen obturatum (mm)
8	LFo2	Inner breadth of the foramen obturatum (mm)
9	GBTc	Greatest breadth across the tuber coxae (mm)
10	GBA	Greatest breadth across the acetabula (mm)
11	GBTi	Greatest breadth across the tuber ischiadicum (mm)
12	SBI	Smallest breadth across the bodies of the ischia (mm)
13	Volume	Volume of the ossa coxae (cm ³)
14	Surface area	Surface area of the ossa coxae (cm ²)

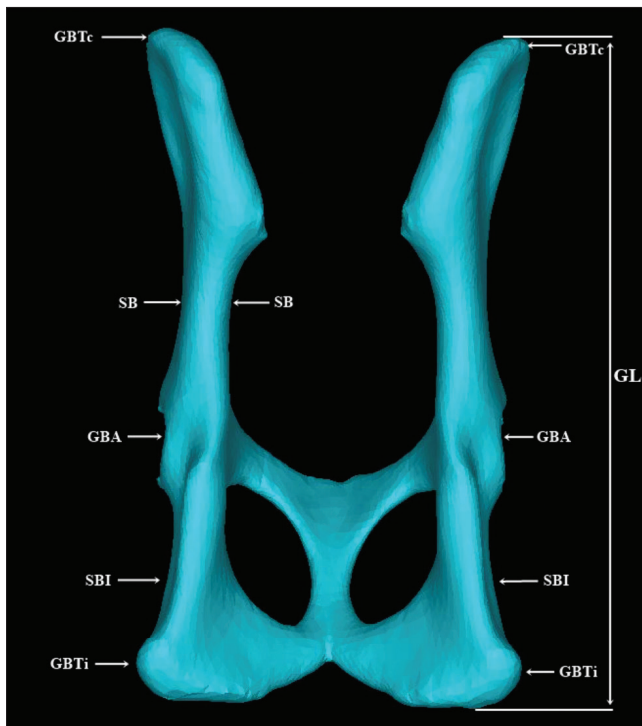


Fig 1. Measurement points on facies dorsalis of ossa coxae. GL: Greatest length of one half; GBTc: Greatest breadth across the tuber coxae; SB: Smallest breadth of the shaft of ilium; GBA: Greatest breadth across the acetabula; SBI: Smallest breadth across the bodies of the ischia; GBTi: Greatest breadth across the tuber ischiadicum

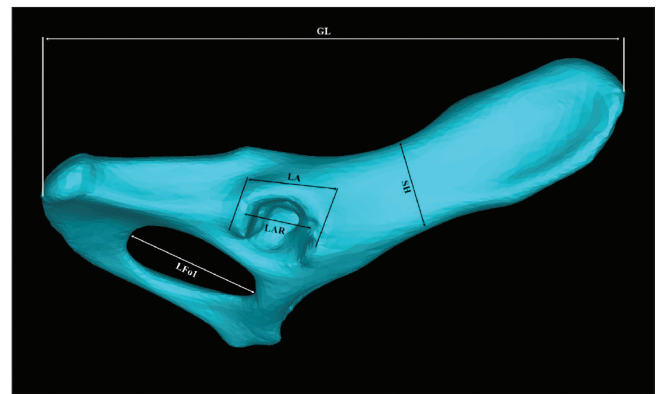


Fig 2. Measurement points on facies lateralis of os coxae. GL: Greatest length of one half; SH: Smallest height of the shaft of ilium; LA: Length between the outer edges of the acetabulum; LAR: Length between the inner edges of the acetabulum; LFo1: Inner length of the foramen obturatum

After morphometric measurements were completed, the surface area and volume value of ossa coxae were calculated. Definition and abbreviations of measured osteometric parameters in *Table 2*, their regions on ossa coxae in *Fig. 1, 2*, and *3* have been presented. *Nomina Anatomica Veterinaria* ^[18] as the terminology has been used

in the study. In addition, for the weight measurements of the cat that have been used in the study, digital scales (TESS[®], RP-LCD, Çomak Scales, İstanbul) has been used.

Shapiro-Wilk test ($n < 50$) was used to examine whether the mean values of the ossa coxae were distributed in three-dimensional modeling and morphometric properties in Van cats by using computerized tomography images, and nonparametric tests were applied because the measurement values of the variables were not normally distributed. Descriptive statistics for measurement values in our study have been expressed as mean, standard deviation, minimum, and maximum. Mann-Whitney U test has been used in the comparisons for genders according to measurements. Spearman coefficient of correlation has been calculated to determine the relation among measurements on the condition that they are different

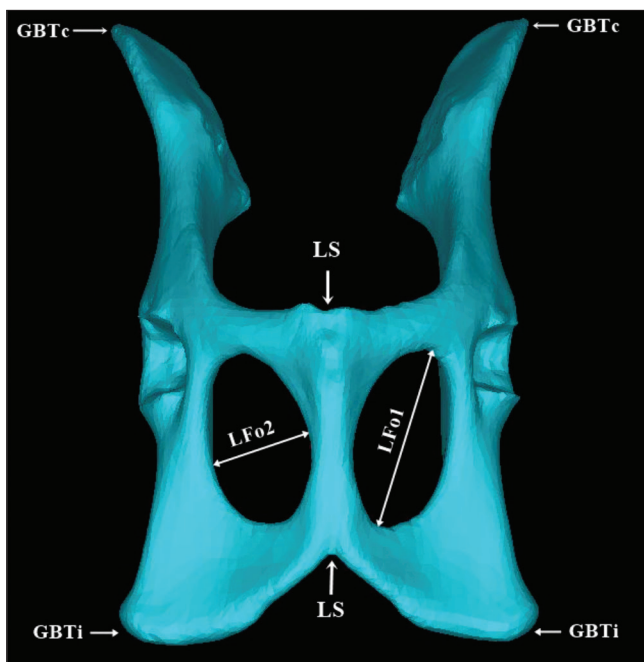


Fig 3. Measurement points on facies ventralis of ossa coxae. GBTC: Greatest breadth across the tuber coxae; GBTi: Greatest breadth across the tuber ischiadicum; LS: Length of the pelvic symphysis; LFo2: Inner breadth of the foramen obturatum

Table 3. Descriptive statistics of the measurements of the ossa coxae in Van cats by gender

Parameter	Gender	Mean	Std. Dev.	Min.	Max.	*P.
Age	Female	5.000	2.000	3.000	8.000	1.000
	Male	5.000	2.000	3.000	8.000	
Body Weight (W)	Female	6.284	0.280	5.810	6.630	0.027
	Male	7.075	0.702	6.300	8.050	
GL	Female	76.638	1.542	74.390	78.590	0.021
	Male	80.398	3.473	75.670	85.820	
LA	Female	10.868	0.472	10.110	11.430	0.009
	Male	11.968	0.781	10.780	13.110	
LAR	Female	9.570	0.247	9.150	9.830	0.172
	Male	9.914	0.672	8.840	11.100	
LS	Female	29.380	2.250	25.690	32.780	0.115
	Male	31.731	2.416	29.290	36.020	
SH	Female	11.628	0.390	10.920	12.030	0.248
	Male	12.255	1.074	10.560	13.610	
SB	Female	4.779	0.481	4.280	5.570	0.208
	Male	4.437	0.626	3.730	5.250	
LFo1	Female	19.763	0.882	18.470	20.860	0.999
	Male	20.009	1.295	18.140	22.630	
LFo2	Female	13.749	1.285	12.070	15.630	0.916
	Male	13.705	0.869	12.760	15.120	
GBTC	Female	41.361	3.448	36.860	47.790	0.248
	Male	43.537	3.150	38.850	47.700	
GBA	Female	38.644	1.395	36.490	40.850	0.074
	Male	40.409	1.952	37.530	43.620	
GBTi	Female	43.471	1.638	41.540	47.020	0.016
	Male	46.055	2.580	43.370	50.630	
SBI	Female	34.457	1.796	31.130	36.350	0.012
	Male	37.245	2.238	34.790	41.810	

* P<0.05; Mann-Whitney U Test

Table 4. Descriptive statistics of the volume and surface area measurements of the ossa coxae in Van cats by gender

Parameter	Gender	Mean	Std. Dev.	Min.	Max	*P.
Volume	Female	9.806	0.707	8.835	10.891	0.005
	Male	12.327	2.138	9.701	15.854	
Surface area	Female	83.840	7.727	76.196	99.072	0.036
	Male	94.660	11.007	70.639	105.588	

* P<0.05; Mann-Whitney U Test

Table 5. Correlation between ossa coxae measurements in Van cats by gender

↓	→	Age	Weight	GL	LA	LAR	LS	SH	SB	LFo1	LFo2	GBTc	GBA	GBTi	SBI
Age	r		0.390	0.049	-0.537	-0.295	0.488	0.098	-0.146	0.390	0.439	0.732*	0.146	-0.390	0.098
Weight	r	0.957**		0.619	0.238	-0.024	0.619	0.476	0.452	0.762*	0.571	0.095	0.452	-0.762*	-0.286
GL	r	0.878**	0.850**		0.095	0.084	0.452	0.119	-0.095	0.286	0.000	-0.190	0.071	-0.214	-0.405
LA	r	0.878**	0.826*	0.952**		0.311	0.095	0.619	0.381	0.357	0.238	-0.524	0.024	-0.119	-0.524
LAR	r	0.565	0.554	0.719*	0.731*		-0.611	0.587	0.431	-0.443	0.431	-0.719*	0.000	0.575	-0.371
LS	r	0.781*	0.826*	0.619	0.619	0.048		0.143	-0.214	0.857**	0.143	0.619	0.310	-0.762*	-0.143
SH	r	0.761*	0.783*	0.467	0.395	0.000	0.826*		0.571	0.333	0.762*	-0.190	0.333	-0.143	-0.381
SB	r	0.439	0.287	0.357	0.262	-0.228	0.476	0.539		0.119	0.500	-0.310	0.429	-0.333	0.167
LFo1	r	0.878**	0.850**	0.952**	0.857**	0.647	0.619	0.587	0.381		0.452	0.405	0.405	-0.857**	-0.333
LFo2	r	-0.195	0.036	-0.190	-0.190	-0.216	0.214	0.048	-0.571	-0.119		0.048	0.524	-0.262	-0.429
GBTc	r	0.390	0.311	0.071	0.095	-0.503	0.690	0.695	0.738*	0.119	-0.119		0.333	-0.500	0.429
GBA	r	0.878**	0.814*	0.762*	0.762*	0.347	0.810*	0.671	0.619	0.714*	-0.286	0.595		-0.476	0.071
GBTi	r	0.488	0.419	0.238	0.190	-0.263	0.571	0.731*	0.833*	0.238	-0.429	0.786*	0.571		-0.143
SBI	r	0.439	0.323	0.286	0.214	-0.204	0.452	0.575	0.929**	0.262	-0.619	0.714*	0.595	0.952**	

** P<0.01; * P<0.05; r: Spearman's rho Nonparametric Correlations Coefficients ↓: MALE. →: FEMALE

for genders. Statistical significance levels were considered as 1% and 5%. The SPSS (IBM SPSS for Windows, Ver.23) statistic packaged software has been used for calculations.

RESULTS

Osteometric measurements from 14 parameters as well as surface area and volume of ossa coxae were taken in our study. Male and female group average of obtained morphometric measurement values and differences between genders have been detected by carrying out statistical analysis. Later, considerable differences (P<0.05) between these measurement values have statistically been reported. These evaluated measurement values have been presented in Table 3, Table 4, Table 5 and Fig. 4.

Descriptive statistics of osteometric measurement values of the ossa coxae according to gender were given in Table 3. Accordingly, it was observed that GL, LA, GBTi, and SBI measurement values were statistically significantly higher in male cats compared to female cats (P<0.05)

Distribution of the ossa coxae morphometric measurements by gender has been given in Fig. 4. According to the graph in the figure, while GL, LA, LAR, LS, SH, LFo1, GBTc, GBA, GBTi, and SBI measurement values for male cats

are higher; SB and LFo2 measurement values for female cats are larger.

Surface area and volume measurements of the ossa coxae of male and female Van cats have been separately performed and descriptive statistics of these measurement values have been given in Table 4. The volume of the ossa coxae in male cats was found to be $12.33 \pm 2.14 \text{ cm}^3$ whereas, in female cats, it was measured as $9.81 \pm 0.71 \text{ cm}^3$. The surface area of the ossa coxae was measured to be $94.66 \pm 11.01 \text{ cm}^2$ in male cats and $83.84 \pm 7.73 \text{ cm}^2$ in female cats. It was determined that these differences between the measurement values of male and female Van cats were statistically significant (P<0.05).

In Table 5, the relationship between ossa coxae's morphometric measurement values by gender was studied. Accordingly, a significant positive relationship in male cats was observed between age and body weight with GL, LA, LS, SH, LFo1, and GBA measurement values; between LA with LAR, LFo1, and GBA measurement values; between LS with SH and GBA measurement values, between SH and GBTi measurement values; between the SB with GBTc, GBTi, and SBI measurement values; between LFo1 and GBA measurement values; between GBTc with GBTi and SBI measurement values; between GBTi and SBI

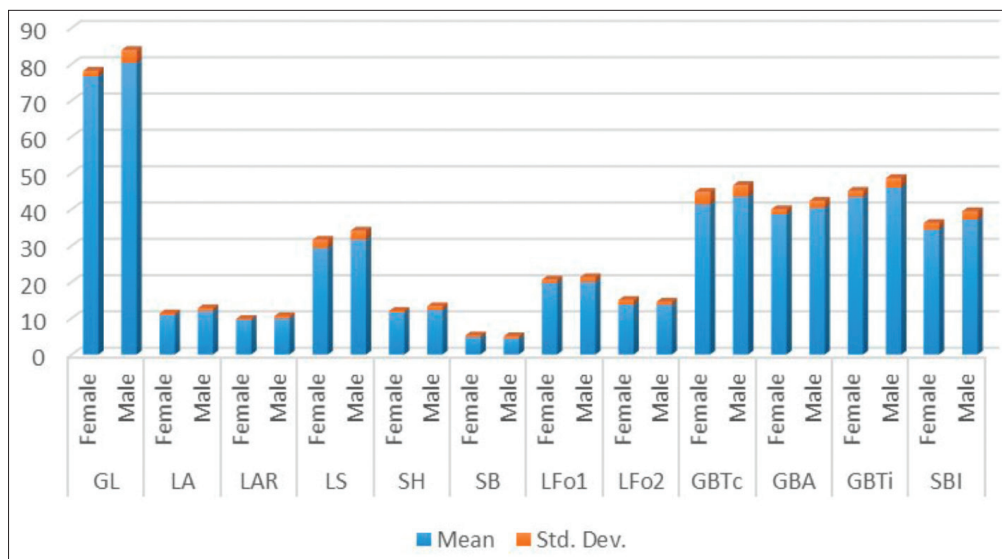


Fig 4. Distribution of the ossa coxae morphometric measurements by gender

measurement values ($P < 0.05$). In female cats, a significant positive relationship was determined between age and GBTC measurement values, between body weight and LFo1 measurement values; between LFo1 with body weight and LS measurement values; between LFo2 and SH measurement values ($P < 0.05$). However, a negative significant correlation was found between GBTI and body weight measurement values at 76.2%; between GBTC and LAR measurement values at 71.9%; between GBTI with body weight, LS, and LFo1 measurement values at 76.2%, 76.2%, and 85.7% ($P < 0.05$).

DISCUSSION

Morphometric analysis on animal bones is a common method in determining differences between genders, studying different breed among animal species, revealing morphological variations in a species, and also presents significant data for various science fields such as forensic, developmental, and evolutionary sciences^[19]. A number of studies have been carried out in humans^[11,20,21] and veterinary medicine field^[5,19,22-27] in order to reveal differences of measurements between genders obtained from ossa coxae.

Computed tomography and three-dimensional reconstruction programs are often used in screening complex anatomical structures such as pelvic in small animals like dog and cat, obtaining various morphometric values, in the diagnosis of diseased or pathological structures in the region, and in evaluating treatment options for these structures^[5,7,9]. In this study, morphometric, volumetric, surface area measurement values of the ossa coxae have been determined and differences of these values between genders have been revealed by using CT and three-dimensional modeling in adult Van cat.

In the morphological and radiological studies carried out on osteometric properties of pelvic in cats, it has been found that measurement parameters of pelvic are mostly larger in male cats compared to female cats, but pelvic angles are higher in female cats^[5,19,24,28]. In our study, in parallel with this information, obtained 12 measurement parameters out of 14 as well as volumetric measurement value and surface area of the ossa coxae have been found to be higher in male cats than female ones. Distribution of these measurement parameters by genders and descriptive statistics have been given in *Fig. 4* and *Table 3*. It was observed that GL, LA, GBTI, and SBI measurement values among measurement parameters were statistically significantly higher in male cats than female ones ($P < 0.05$). Accordingly, we can conclude that the ossa coxae in Van cats are bigger in male cats than female ones.

In a study on pelvic osteometric measurements of Retriever dogs performed by Nganvongpanit et al.^[27], it has been found that GL, GBTC, GBTI, LS, LFo1, and LFo2 measurement values in the male are 161.50 mm, 88.44 mm, 105.22 mm, 47.15 mm, 29.13 mm, 23.97 mm respectively whereas in females they are 145.93 mm, 80.05 mm, 98.93 mm, 42.33 mm, 27.11 mm, 23.47. In another study on pelvic morphometric measurements of domestic cats performed by Pitakarnnop et al.^[19], it has been reported that these measurement values in the male are 79.46 mm, 42.97 mm, 37.23 mm, 16.70 mm, 18.01 mm, 14.54 mm respectively whereas in females they are 74.61 mm, 39.73 mm, 39.58 mm, 18.21 mm, 18.41 mm, 14.12 mm. In the study conducted, these values in male Van cats have been detected as 80.40 mm, 43.54 mm, 46.06 mm, 31.73 mm, 20.01 mm, 13.71 mm; 76.64 mm, 41.36 mm, 43.47 mm, 29.38 mm, 19.76 mm, 13.75 mm. That, in general, there are slight differences between these values is thought to have resulted from species, age, height, breed, and body weight properties.

The age and body weight are of great importance in terms of pelvic growth or evaluating osteometric measurement parameters. In the studies carried out, it has been reported that there is a mostly positive correlation between age and body weight of male-female animals and morphometric measurements of pelvic in general [5,23,28,29]. In the study we have performed, a significant positive relationship has been observed between age and body weight with GL, LA, LS, SH, LFo1, and GBA measurement values in male cats ($P<0.05$). A significant positive relationship in female cats has been seen between age and GBTC measurement values; between body weight and LFo1 measurement values; whereas, a negative significant relationship has been found between body weight and GBTI measurement values at 76.2%. ($P<0.05$). In addition, the correlation between other measurement values of the ossa coxae in male and female Van cat has been given in *Table 5*. It is thought that together with pelvic angle measurements taken by Yilmaz et al. [5] in Van cats, osteometric measurements and correlations taken in these studies may be useful in future characterization studies including determination of external body measurements and body condition score in these cats.

In recent years thanks to technological improvements such as CT in the medical imaging field, images of desired thickness can be taken under anesthesia without causing any vital damage to the living creature, and from these images, anatomical studies can be done in the relevant structure by using various three-dimensional reconstruction programs [5,20]. Measurement values such as osteometric, volumetric, and surface area of pelvic and complex anatomical structures around it can be easily calculated using CT and various developed three-dimensional modeling programs and so diagnosis and treatment of various pathological condition activities can be evaluated by obtaining quantitative data of relevant anatomical structure [7,21,29]. In the study we conducted, the volume and surface area of the ossa coxae were calculated via a 3D modeling program (MIMICS 20.1-The Materialise Group, Leuven, Belgium) using CT images in Van cats. In Van cats, the volume value of the ossa coxae in males was determined $12.33\pm 2.14\text{ cm}^3$, in females $9.81\pm 0.71\text{ cm}^3$; the surface area was determined $94.66\pm 11.01\text{ cm}^2$ in males and $83.84\pm 7.73\text{ cm}^2$ in females. It was found that these differences observed between measurement values of male and female Van cats are statistically at a significant level ($P<0.05$).

As a result, statistical differences of measurement parameters of the ossa coxae in Van cats between genders were found by using computed tomography and a three-dimensional modeling program. In addition, in this study, basic morphometric data were obtained that would benefit veterinarians and studies in zooarchaeology in the fields of surgery, clinical, gynecological, diagnostic imaging, and treatment, especially in anatomy education.

CONFLICT OF INTEREST

The authors report no conflicts of interest. The authors alone are responsible for the content and writing of paper.

AUTHOR CONTRIBUTIONS

OY and İD planned, designed, and supervised the research procedure. OY and İD performed the anatomical analysis. OY carried out the statistical analysis. OY and İD performed the imaging stage and the CT parameters. The manuscript was written by OY and İD. OY contributed to the language editing of the final manuscript. All authors have interpreted the data, revised the manuscript for contents, and approved the final version.

REFERENCES

- Bahadır A, Yıldız H:** Veteriner Anatomi: Hareket Sistemi & İç Organlar. Ezgi Bookselling, Bursa, Turkey, 2008.
- Dursun N:** Veteriner Anatomi I. Medisan Publisher, Ankara, Turkey, 2002.
- Dyce KM, Sack WO, Wensing CJG:** Textbook of Veterinary Anatomy. 4th ed., 490-500, Saunders Elsevier Inc, Missouri, United States, 2010.
- Liebich HG, König HE, Maierl J:** Arka bacaklar (membri pelvini). In, Kürtül İ, Türkmenoğlu İ (Eds): Veteriner Anatomi (Evcil Memeli Hayvanlar). 6th ed., 223-288, Medipres, Malatya, Turkey, 2015.
- Yılmaz O, Soyguder Z, Yavuz A, Dundar I:** Three-dimensional computed tomographic examination of pelvic cavity in Van cats and its morphometric investigation. *Anat Histol Embryol*, 49 (1): 60-66, 2020. DOI: 10.1111/ahe.12484
- Brenton H, Hernandez J, Bello F, Strutton P, Purkayastha S, Firth T, Darzi A:** Using multimedia and web 3D to enhance anatomy teaching. *Comput Educ*, 49, 32-53, 2007. DOI: 10.1016/j.compedu.2005.06.005
- Ohlerth S, Scharf G:** Computed tomography in small animals-basic principles and state of the art applications. *Vet J*, 173, 254-271, 2007. DOI: 10.1016/j.tvjl.2005.12.014
- Holubar SD, Hassinger JP, Dozois EJ, Camp JC, Farley DR, Fidler JL, Pawlina W, Robb RA:** Virtual pelvic anatomy and surgery simulator: An innovative tool for teaching pelvic surgical anatomy. *Stud Health Technol Inform*, 142, 122-124, 2009. DOI: 10.3233/978-1-58603-964-6-122
- Dimitrov R:** Application of the computed tomography as a method of anatomical study of the thoracic and pelvic cavities in cat and dog. *Trakia J Sci*, 7 (4): 76-83, 2009.
- Wisner ER, Zwingenberger AL:** Atlas of Small Animal CT and MRI. Willey-Blackwell Publishing, USA, 2015.
- Berge C, Goularas D:** A new reconstruction of sts 14 pelvis (*Australopithecus africanus*) from computed tomography and three-dimensional modeling techniques. *J Hum Evol*, 58 (3): 262-272, 2010. DOI: 10.1016/j.jhevol.2009.11.006
- Odabasioglu F, Ates CT:** Van Cats. Selcuk University Printing Office, Konya, Turkey, 2000.
- Yılmaz O:** Three-dimensional investigation by computed tomography of the forelimb skeleton in Van cats. *PhD thesis*, Van Yuzuncu Yil University, Institute of Health Sciences, Faculty of Veterinary, Department of Anatomy, Van, Turkey, 2018.
- Yılmaz O, Soyguder Z, Yavuz A:** Van kedilerinde clavicula ve scapula'nın bilgisayarlı tomografi görüntülerinin üç boyutlu olarak incelenmesi. *Van Vet J*, 31 (1): 34-41, 2020. DOI: 10.36483/vanvetj.644080
- Prokop M:** General principles of MDCT. *Eur J Radiol*, 45 (Suppl. 1): S4-S10, 2003. DOI: 10.1016/S0720-048X(02)00358-3
- Kalra MK, Maher MM, Toth TL, Hamberg LM, Blake MA, Shepard J, Saini S:** Strategies for CT radiation dose optimization. *Radiology*, 230,

619-628, 2004. DOI: 10.1148/radiol.2303021726

17. Von Den Driesch A: A Guide to the Measurement of Animal Bones from Archaeological Sites. Peabody Museum of Archaeology and Ethnology, Harvard University, Cambridge, Massachusetts, 1976.

18. Nomina Anatomica Veterinaria: International Committee on Veterinary Gross Anatomical Nomenclature (ICVGAN). 6th ed., Published by the Editorial Committee, Hannover, 2017.

19. Pitakarnnop T, Buddhacha K, Euppayo T, Kriangwanich W, Nganvongpanit K: Feline (*Felis catus*) skull and pelvic morphology and morphometry: Gender-related difference? *Anat Histol Embryol*, 46 (3): 294-303, 2017. DOI: 10.1111/ahe.12269

20. Correia H, Balseiro S, Areia MD: Sexual dimorphism in the human pelvis: Testing a new hypothesis. *Homo*, 56 (2): 153-160, 2005. DOI: 10.1016/j.jchb.2005.05.003

21. Lee UY, Kim IB, Kwak DS: Sex determination using discriminant analysis of upper and lower extremity bones: New approach using the volume and surface area of digital model. *Forensic Sci Int*, 253, 135.e1-135.e4, 2015. DOI: 10.1016/j.forsciint.2015.05.017

22. Sajjarengpong K, Adirekthaworn A, Srisuwattnasagul K, Sukjumlong S, Darawiroj D: Differences seen in the pelvic bone parameters of male and female dogs. *Thai J Vet Med*, 33, 55-61, 2003.

23. Nahkur E, Ernits E, Jalakas M, Järv E: Morphological characteristics

of pelvis of Estonian Holstein and Estonian Native Breed cows from the perspective of calving. *Anat Histol Embryol*, 40 (5): 379-388, 2011. DOI: 10.1111/j.1439-0264.2011.01082.x

24. Monteiro CLB, Campos AIM, Madeira VLH, Silva HVR, Freire LMP, Pinto JN, de Souza LP, da Silva LDM: Pelvic differences between brachycephalic and mesaticephalic cats and indirect pelvimetry assessment. *Vet Rec*, 172 (1): 16, 2013. DOI: 10.1136/vr.100859

25. Özkadif S, Eken E, Kalaycı İ: A three-dimensional reconstructive study of pelvic cavity in the New Zealand rabbit (*Oryctolagus cuniculus*). *Sci World J*, 2014: 489854, 2014. DOI: 10.1155/2014/489854

26. Jurgelēnas E: Osteometric analysis of the pelvic bones and sacrum of the red fox and raccoon dog. *Vet Med Zoot*, 70, 42-47, 2015.

27. Nganvongpanit K, Pitakarnnop T, Buddhachat K, Phatsara M: Gender-related differences in pelvic morphometrics of the Retriever dog breed. *Anat Histol Embryol*, 46, 51-57, 2017. DOI: 10.1111/ahe.12232

28. Celimli N, Seyrek Intas D, Yilmazbas G, Seyrek Intas K, Keskin A, Kumru IH, Kramer M: Radiographic pelvimetry and evaluation of radiographic findings of the pelvis in cats with dystocia. *Tierarztl Prax*, 36, 277-284, 2008. DOI: 10.1055/S-0038-1622688

29. Dobak TP, Voorhout G, Vernooij JCM, Boroffka SAEB: Computed tomographic pelvimetry in English bulldogs. *Theriogenology*, 118, 144-149, 2018. DOI: 10.1016/j.theriogenology.2018.05.025