

Evaluation of the Protective Effect of Chlorogenic Acid and *Rhabdosciadium anatolyi* Against Cyclophosphamide-Induced Ovarian Toxicity in the Rat with Histopathological and Immunohistochemical Findings

İsmet ALKIŞ^{1,a} Suat EKİN^{2,b} Serkan YILDIRIM^{3,c} Ahmet BAKIR^{2,d} Gizem ESER^{3,e} Mehmet FIRAT^{4,f}

¹ Department of Obstetrics and Gynecology, Faculty of Medicine, Van Yuzuncu Yil University, TR-65080 Van - TURKEY

² Department of Chemistry, Division of Biochemistry, Faculty of Science, Van Yuzuncu Yil University, TR-65080 Van - TURKEY

³ Department of Pathology, Faculty of Veterinary Medicine, Ataturk University, TR-25240 Erzurum - TURKEY

⁴ Department of Biology, Van Yüzüncü Yil University, TR-65080 Van - TURKEY

ORCIDs: ^a 0000-0002-5674-4610; ^b 0000-0002-6502-5028; ^c 0000-0003-2457-3367; ^d 0000-0003-0797-285X; ^e 0000-0002-8330-3095

^f 0000-0001-5814-614X

Article ID: KVFD-2020-24305 Received: 12.04.2020 Accepted: 19.08.2020 Published Online: 21.08.2020

How to Cite This Article

Alkiş İ, Ekin S, Yıldırım S, Bakır A, Eser G, Fırat M: Evaluation of the protective effect of chlorogenic acid and *Rhabdosciadium anatolyi* against cyclophosphamide-induced ovarian toxicity in the rat with histopathological and immunohistochemical findings. *Kafkas Univ Vet Fak Derg*, 26 (6): 757-763, 2020. DOI: 10.9775/kvfd.2020.24305

Abstract

Cyclophosphamide (CD) has a range of adverse effects on ovarian tissue in humans. It is widely an anticancer drug and used in autoimmune disorders. Also, CD produces reactive oxygen species. In the current study, we evaluated possible protective roles of *Rhabdosciadium anatolyi* (RA) and chlorogenic acid (CA) on histopathological alterations and immunohistochemical assessment of 8-OHdG in the ovarian tissues of female rats given cyclophosphamide. Female Wistar albino rats were divided into six experimental groups, each consisted of eight rats: control group, CD (200 mg/kg) with i.p. for the first day as single dose, CA (100 mg/kg), RA (300 mg/kg) for each day, RA (300 mg/kg) + CD (200 mg/kg) and CA(100 mg/kg) + CD (200 mg/kg) groups. The rats were administered treatments lasted 7 days for all groups. CA and RA treatment is associated with positive the ovary action CD-induced ovotoxicity in rats. CA and RA could ameliorate the histopathological and immunohistochemical finding restoring which may show moderate levels of primordial follicle, primary, secondary, tertiary and graafian follicles were observed degeneration in germinative cells. Therefore, our results suggest that chlorogenic acid and *Rhabdosciadium anatolyi* might be a protective effect for CD-induced ovotoxicity.

Keywords: Cyclophosphamide, *Rhabdosciadium anatolyi*, Chlorogenic acid, 8-OHdG

Klorojenik Asit ve *Rhabdosciadium anatolyi*'nin Siklofosfamid İle Ratlarda Oluşturulan Ovaryum Toksisitesine Karşı Koruyucu Etkisinin Histopatolojik ve İmmunohistokimyasal Bulgularla Değerlendirilmesi

Öz

Siklofosfamid (CD), insanlarda ovaryum dokusu üzerinde bir dizi yan etkilere sahiptir. Yaygın bir şekilde antikanser ilacı olarak ve otoimmün hastalıklarda kullanılır. Ayrıca, CD, reaktif oksijen türleri üretir. Bu çalışmada, siklofosfamid verilen dişi ratların over dokularında, *Rhabdosciadium anatolyi* (RA) ve klorojenik asidin (CA) histopatolojik değişiklikler ve immünohistokimyasal olarak belirlenen 8-OHdG üzerine olası koruyucu rolleri değerlendirildi. Dişi Wistar albino ratlar, her grupta sekiz olacak şekilde, altı deney grubuna ayrıldı: kontrol grubu, i.p olarak ilk gün için tek doz CD (200 mg/kg), CA (100 mg/kg) ve RA (300 mg/kg) için her gün, RA (300 mg/kg) + CD (200 mg/kg) ve CA (100 mg/kg) + CD (200 mg/kg) grupları. Ratlara tüm gruplar için işlemler 7 gün süreyle uygulandı. CA ve RA uygulaması, ratlarda CD'nin neden olduğu ovotoksitesite, over üzerine olumlu etkisi olması ile ilişkilidir. Germitif hücrelerinde gözlenen dejenerasyonu, aynı zamanda orta düzeyde görülen primordial follikül, primer, sekonder, tersiyer ve graf folliküllerin histopatolojik ve immünohistokimyasal bulgularının düzelmesini CA ve RA sağlayabilir. Bu nedenle sonuçlarımız, CD'nin neden olduğu ovotoksitesiteye karşı klorojenik asit ve rabdosciadium anatolyi'nin koruyucu bir etki oluşturabileceğini düşündürmektedir.

Anahtar sözcükler: Siklofosfamid, *Rhabdosciadium anatolyi*, Klorojenik asit, 8-OHdG



Correspondence



+90 532 4420963



ismetalkis@hotmail.com

INTRODUCTION

Cyclophosphamide (CD) is one of the well-known alkylating agents, which is commonly used to treat chronic and acute leukemias, multiple myeloma, lymphoma, retinoblastoma, neuroblastoma, breast and ovarian cancers [1]. CD endures bioconversion by hepatic microsomal P₄₅₀ oxidases that produce two metabolites; acrolein and phosphoramidate mustard, which forms covalent bonds with DNA via enzymatic activation that leads to cell death. When enzymatically activated, these cytotoxic metabolites form covalent bonds with DNA and proteins and cause cell death [2]. Although, CD affords employment of it in various applications, the clinical usage of CD is usually restricted due to its side effects and toxicities that include nausea, bone marrow suppression, vomiting, alopecia, nephrotoxicity, hepatotoxicity, ovotoxicity, urotoxicity, immunotoxicity, cardiotoxicity, mutagenicity, teratogenicity, and carcinogenicity [3].

Recent *in vivo* studies regarding chemotherapy-induced destruction of dormant follicles [4] have revealed that chemotherapeutic agents such as cyclophosphamide and cisplatin activate the onset of dormant follicle growth, concurrent with apoptosis of large follicles [5]. As a result of this, destruction of ovarian follicles disrupts ovarian functions and leads to permanent ovarian insufficiency [6]. Cyclophosphamide is mostly linked to the highest risk of female infertility, which is usually assigned to ovarian toxicity and is strongly associated with the cumulative doses of CD. Reproductive functions are deteriorated by rapid depletion of the oocyte reserve that mediates through apoptotic cell death and ovarian atrophy by the disappearance of resting primordial follicles [7].

Phenolic compounds have the aptitude to suppress lipid peroxidation, avoid DNA oxidative damage, and scavenge free radicals. Free radicals cause a decrease in the immune system antioxidants, cause changes in the gene expression, and induce abnormal proteins that lead to degenerative diseases and aging [8]. Chlorogenic acid (CA), which is a kind of phenolic antioxidant, has a certain number of R-OH radicals, that can generate hydrogen free radicals with antioxidant activity, and neutralize free radical activity such as superoxide anion, thus protects tissue cells from oxidative damage [9]. CA has potential activity on lipid peroxidation, for instance 8-hydroxydeoxyguanosine is configured via this inhibitor. It is known that several phenolic compounds have an inhibitory effect on the mutagenesis and carcinogenesis of polycyclic aromatic hydrocarbons [10].

Medicinal plants help us in taking a role of therapeutic alternatives. The enhanced number of these plants and their extracts were proven to have beneficial therapeutic effects, as well as antioxidants, anticancer, anti-inflammatory antimicrobial and immunomodulatory effects [11]. Medicinal

herbs have been used to treat different diseases in Turkish traditional medicine. *Rhabdosciadium anatolyi*, also known as endemic taxa of the family Apiaceae, is a flavoring herb widely found in Turkey. *Rhabdosciadium anatolyi* Lyskov & Kljuykov is a wild edible plant with a wide distribution in Hakkari province which is in The Eastern Anatolia Region of Turkey.

Rhabdosciadium anatolyi is particularly located on the wet rocky northern slope near the snowfield of Hakkari [12]. The flowers of this plant are used as an additive spice for pleasant taste in the herbal cheese of Van, salads and yoghurt.

This study was designed to investigate the possible protective roles of *Rhabdosciadium anatolyi* and chlorogenic acid on the effects induced by a single dose of cyclophosphamide on ovarian tissue of Wistar female rats by detecting histopathological alterations and immunohistochemical assessment of 8-OHdG.

MATERIAL and METHODS

Plant Material

Rhabdosciadium Anatoly Lyskov & Kljuykov (Apiaceae) flowers were collected from Yüsekova district, Hakkari province (37°22'41" N, 44°10'08" E, 2356 m 18 July 2018) and dried under the shade. *Rhabdosciadium anatolyi* was identified by Dr. Mehmet Firat. The specimen was stored in Van Yuzuncu Yil University herbarium, Department of Botany, VANF 30400.

Plant Material and Extract Preparation

Rhabdosciadium anatolyi dried flower of plant 35 g were prepared in 350 mL of ethanol (75%) as an extraction solvent for 48 h at room temperature and the resulting extract were filtered through a filter paper. After the evaporation of the solvent under a reduced vacuum at temperatures below 40°C, the filtrate was then dried in an incubator. Dried powder of flower extracts was then prepared in physiologic saline (0.9%), daily.

Experimental Section

- Experimental Animals

In this study, forty-eight female Wistar-albino rats (aged 8 weeks, weighing 200±50 g) were used. Rats were supplied by Van Yuzuncu Yil University, Faculty of Medicine, Experimental Animal Research Center. The rats were housed in clean cages at normal temperature (22±2°C) and normal daily lighting with a 12 h light-dark cycle and supplied with drinking water and food *ad libitum*. Experimental protocols were carried out following the general principles of the animal ethics committee of Van Yuzuncu Yil University (YUHAD-YEK, Date: 25.10.2018; Decision number: 2018-10).

- Experimental Design

The rats were randomly divided into six equal sized groups (eight rats in each group). Group 1: considered as normal control (given 0.9% isotonic saline solution) for 7 consecutive days, calculated according to the body weight. Group 2: cyclophosphamide (CD) was administered (CD 200 mg/kg) intraperitoneally (i.p.) only the first day as a single dose. Group 3: Chlorogenic acid (CA) (100 mg/kg) administered (by an intragastric tube for each day). Group 4: *Rhabdosciadium anatolyi* (RA) administered by an intragastric tube (RA 300mg/kg) every day throughout the experimental period. Group 5: RA (300 mg/kg) were administered orally daily and a single injection of i.p 200 mg/kg CD for the first day. Group 6 rats (CA+CD) were treated with CA (100 mg/kg) for each day and 200 mg/kg CD for the first day as a single dose. The treatment course has lasted 7 days for all groups. At the end of the experimental period, all female Wistar-albino rats were anesthetized and sacrificed; and the ovaries were removed for histopathological and immunohistochemical examinations.

- Histopathological Examination of the Ovaries

Ovarian tissues obtained for histopathological assessment were fixed in 10% (v/v) formalin solution for 48 h before being processed for histopathological analysis and then washed in tap water for 10 h.

With a routine tissue follow up, tissues were passed through alcohol and xylene series, and embedded into paraffin blocks. A 4 µm thick slices were taken from each block, and samples were prepared on slides. Preparations planned for histopathological examination were stained with hematoxylin and eosin and examined using light microscopy (Leica DM 1000, Germany). They were evaluated as none (-), mild (+), moderate (++) and severe (+++) according to the lesions based on histopathological findings.

- Immunohistochemical Examination of 8-hydroxy-2'-deoxyguanosine (8-OHdG)

All sections that were transferred to adherent (poly-L-lysine) slides for immunoperoxidase staining were passed through xylol and alcohol series, deparaffinized and dehydrated. They were washed with phosphate buffer solution (PBS, pH 7.2) for 5 min and stored in 3% H₂O₂ for 10 min, and endogenous peroxidase were inactivated. To prevent the masking of antigen in the nucleus, the sections were heated in an antigen retrieval (citrate buffer, pH 6.1) solution, 5 min each for four times in a microwave (500 watt) oven and then removed from the microwave oven and allowed to cool to room temperature for 30 min. After the incubation (37°C, 60 min), the excess block solution that remained on the tissue sections was removed, and 8-OHdG catalog no. ab183394 Abcam, UK, and PBS for control group) were added prior to the final rinse. Immunohistochemistry procedures were followed according to the manufacturers' (Abcam HRP/DAB Detection

IHC kit) instructions. DAP chromogen was added to the sections, and sections were kept for 5-10 min to take in the chromogenic substance. Sections were kept in Mayer's hematoxylin for background staining for 1-2 min and then washed in tap water. After passing alcohol and xylol series, entellan was dropped on the sections and slides were closed with coverslips and examined under light microscopy (Leica DM 1000). The sections were evaluated as no (-), mild (+), moderate (++) and severe (+++) according to their immunopositivity.

Statistical Analysis

The Differences between groups were analyzed using one-way analysis of variance (ANOVA), Duncan test. The statistical analysis was carried out with SPSS®, version 23.0 statistical software (SPSS Inc. Chicago Ill, USA). Statistical significance was considered to be P<0.05.

RESULTS

Ovarian samples were evaluated for follicle counts, damage scores. Primordial, primary secondary and Graafian follicle counts were significantly increased in the control, chlorogenic acid and *Rhabdosciadium anatolyi* groups.

Histopathological Findings

The ovaries observed in the control group were in normal histological appearance (Fig. 1-B). In the CD group, necrosis in many of the luteal cells, severe hyperemia and hemorrhage in the vessels, degeneration in germinative cells, very few primordial follicles dominated by luteal structures were observed, while secondary and Graafian follicle structures were not found (Fig. 1-B). When graafian, primary, secondary, and tertiary follicles were examined in terms of counts, a statistically significant difference (P<0.05) was detected compared to the control group. In the CA group, it was observed that the primordial, graafian, primary, secondary, tertiary follicles and luteal structures had normal histological appearance (Fig. 1-C). In histopathological examination of ovarian tissues in RA group, it was observed that the primordial, Graafian, primary, secondary, tertiary follicles and luteal structures were in normal histological appearance (Fig. 1-D). In the CD+RA group, moderate levels of primordial, primary, secondary, tertiary and Graafian follicles and degeneration in germinative cells (Fig. 1-E), and CD+RA group a statistically significant difference (P<0.05) observed compared to the control group. While there was no significant difference in terms of follicle counts compared to the 6th group, it was found that the count of follicles in this group was higher. Furthermore, CD+CA treated rats showed moderate level in primordial, a small number of primary, secondary, tertiary and Graafian follicles were identified and degeneration in germinative cells (Fig. 1-F). CD+CA group a statistically significant (P<0.05) was determined when compared to the control group (Table 1).

Table 1. Scores of histopathological and immunohistochemical findings

Parameters	Control	CD	CA	RA	CD+RA	CD+CA
Primordial follicle counts	+++	+	+++	+++	+++	+++
Primer-secondary follicle counts	+++	+	+++	+++	++	+
Graafian follicle counts	+++	-	+++	+++	+	+
Degeneration and necrosis in the ovarian cells	-	+++	-	-	+	+
8-hydroxy-2'-deoxyguanosine	-	+++	-	-	+	+

(-) No change, (+) Mild change, (++) Moderate change, (+++) Severe change

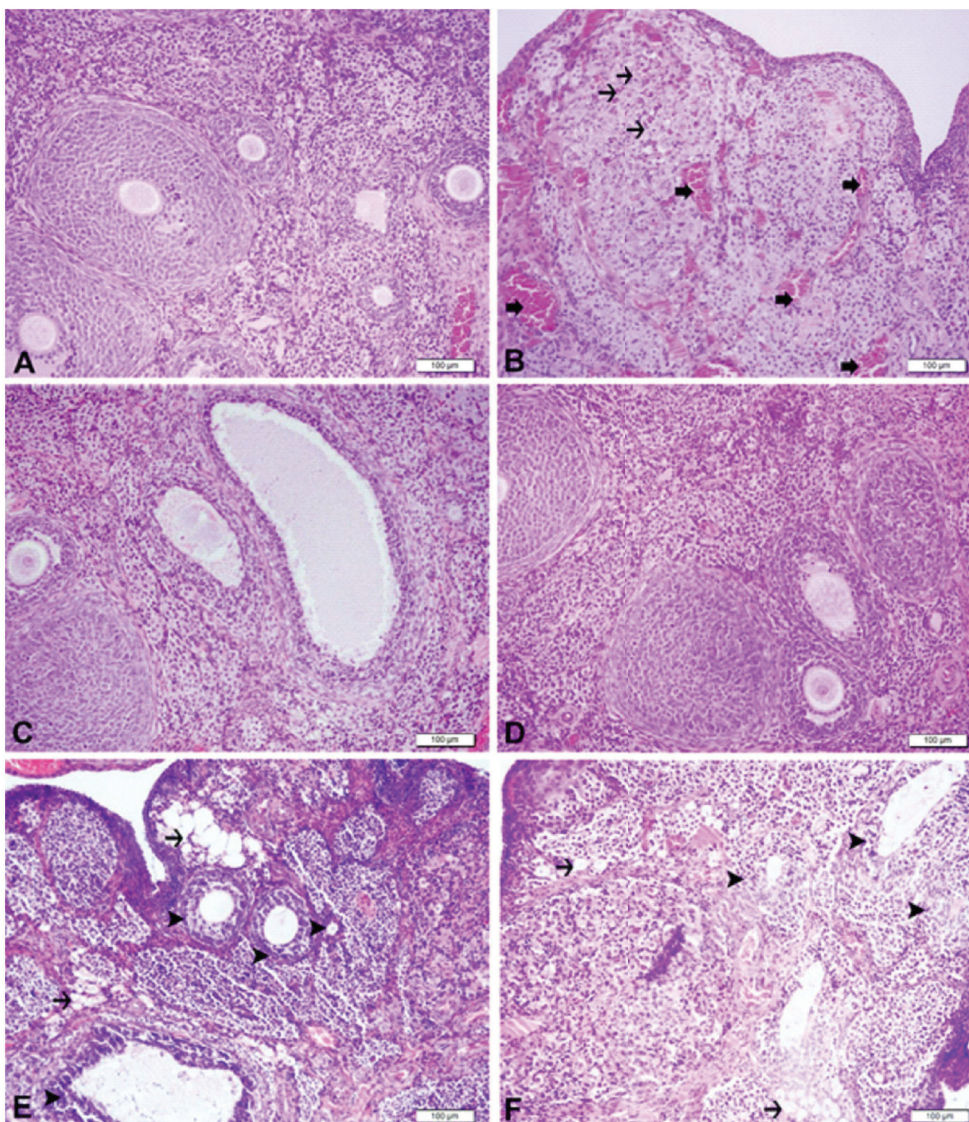


Fig 1. The ovarian tissue, Control group, normal histological appearance (A), CD-treated group, severe level of necrosis in the luteal cell (*thin arrows*), hyperemia and haemorrhage in the vessels (*thick arrows*), degeneration in germinative cells, very few primordial follicles dominated by luteal structures (B), CA group, normal histological appearance (C), RA group, normal histological architecture (D), CD+RA group, moderate level in primordial follicle, primary, secondary, tertiary and graafian follicles (*arrow heads*), and degeneration in germinative cells (*arrows*) (E), CD+CA, moderate level in primordial follicle, a small number of primary, secondary, tertiary and graafian follicles (*arrow heads*), degeneration in germinative cells (*arrows*) (F), H&E, Bar: 100 μ m

Immunohistochemical Results

In the control group, no 8-OHdG expression were determined, as result of immunohistochemical analysis of ovarian tissues (Fig. 2-A). In the CD group, cytoplasmic 8-OHdG expression in the granulosa cells, germinative cells, luteal cells were observed at severe levels in the follicles (Fig. 2-B). Associated to the control group, a statistically significant difference ($P < 0.05$) was seen. In the CA group

was 8-OHdG expression were not observed (Fig. 2-C). In the RA group, 8-OHdG expressions were observed to be negative (Fig. 2-D). Mild expression of 8-OHdG in the CD+RA (Fig. 2-E), and CD+CA group were observed (Fig. 2-F).

The histopathological and immunohistochemical results in the ovarian tissues were evaluated and the findings scores are shown in Table 1.

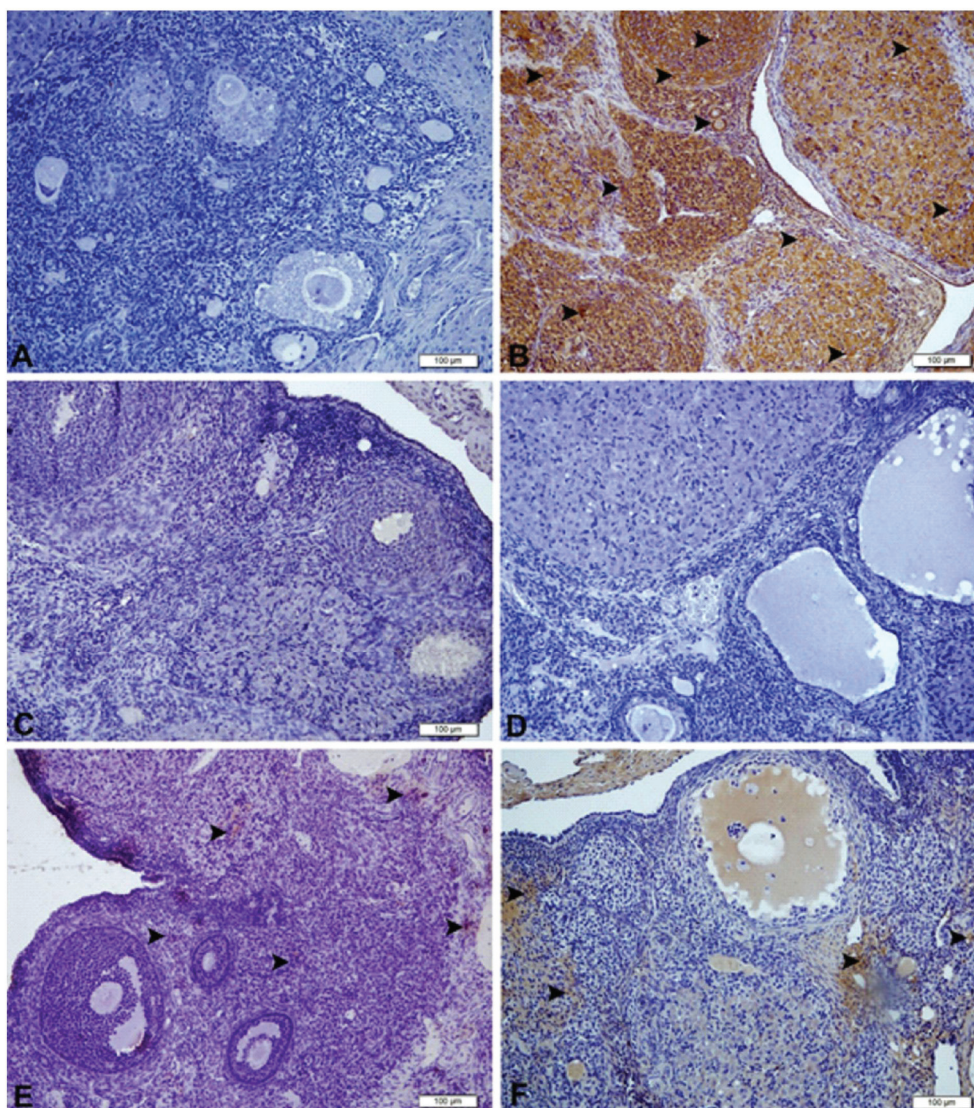


Fig 2. The ovarian tissue, Control group, negative expression of 8-OHdG (A), CD group, cytoplasmic expression of 8-OHdG in the granulosa cells, germinative cells, luteal cells at severe levels follicles (B), CA group, negative expression of 8-OHdG (C), RA group, negative 8-OHdG expression (D), CD+RA group, mild level expression of 8-OHdG (E), CD+CA, mild level expression of 8-OHdG (F), IHC-P, Bar: 100 µm

DISCUSSION

This study was performed to assess the protective roles of *Rhabdosciadium anatolyi* (RA) and chlorogenic acid (CA) cyclophosphamide induced on histopathological alterations. Moreover, current study assayed the possible role of RA flower extracts and CA on immunohistochemical expression of 8-OHdG in ovarian tissue samples in Wistar female albino rats with induced by single dose cyclophosphamide (CD). The usage of high dose CD in cancer treatment is restricted owing to its severe toxicity caused mainly by oxidative stress. The toxic metabolites formed after CD administration are phosphoramidate mustard and acrolein. The toxic effect of CD is related to acrolein which is an active metabolite^[13]. Acrolein reduces the physiological antioxidant defense, and rises production of reactive oxygen species (ROS) by activating of xanthine oxidase^[14].

Himmelstein et al.^[15] examined reduced number of follicles in ovarian tissues obtained from patients treated by CD.

Alkylating substances such as cyclophosphamide have been reported to inhibit the growth of follicles, destroying small oocytes. Another study by Ataya et al.^[16] determined that the mean follicular diameter and number of granulosa cells in each ovary at 16 h and 24 h after CD injection were statistically significantly lower than that of the control group ($P < 0.05$ and $P < 0.01$). Moreover, significant reductions ($P < 0.01$) of primordial and maturing follicles as well as corpora lutea have been observed in cyclophosphamide-treated mice compared to control. In conclusion, granulosa cells appear to be important targets for toxicity in the ovaries of rats treated with cyclophosphamide.

We observed necrosis in many luteal cells, severe hyperemia and hemorrhage in the vessels, degeneration in germinative cells, very few primordial follicles dominated by luteal structures in the rats given single dose CD (CD 200 mg/kg) alone.

In this study, the observation of the significant decrease in primordial follicles and number of follicles in ovarian tissues of rats treated with CD were consistent with those of

other authors^[15,16]. Sections of the ovarian tissue obtained from CD (200 mg/kg) + RA (300 mg/kg treated) and CD (200 mg/kg) + CA (100 mg/kg) treated groups have shown near to normal count of primordial follicles.

Primordial follicle counts have been shown to be unfavorably effected in highly concentrated amount of phosphoramidate mustard, a toxic metabolite of CD, both *in vivo* and *in vitro* studies. It also destroys rapidly dividing granulosa cells of antral and secondary follicles *in vivo* in mice and, in rats the ovarian stromal cells *in vivo*^[17].

Many patients are known to be adversely effected by chemotherapy, via follicular reduction that leads to ovarian failure and infertility. Consequently, chemotherapy destroys proliferation of ovarian follicles throughout treatment, possibly due to the damage triggered by dividing granulosa cells. It has long been suggested that chemotherapeutic agents induce apoptosis of primordial follicles and thus cause ovarian failure. Chemotherapy may lead to vascular damage of certain areas of the ovarian cortex, resulting in depletion of primordial follicles^[17].

Immunohistochemical staining of 8-OHdG in the control group, CA and RA groups (Fig. 2-A, Fig. 2-C,D) 8-OHdG expression was not detected. Following CD administration, in the CD group, cytoplasmic expression of 8-OHdG in the granulosa cells, germinative cells, and luteal cells was observed at severe levels in the follicles (Fig. 2-B). It was observed that the CD group a statistically important difference compared to the control group ($P < 0.05$) was found. In the present study, immunohistochemical analysis clearly demonstrates that the CD+RA and CD+CA groups had mild level expression of 8-OHdG (Fig. 2-E,F).

Oxidative stress can be defined as an imbalance between the oxidant and antioxidant resulting from the excessive production of ROS and the ability of antioxidant systems to easily detoxify the ROS or repair the resulting damage^[18]. ROS may attack the polyunsaturated fatty acid in the biological membranes and cause free radical chain reactions, which leads to increased lipid peroxidation^[19]. Cellular antioxidant system plays an important role in protecting against CD-induced oxidative stress and it's related to toxic manifestations. The recent reports have showed that oxidative stress mediated impairment of tissues redox balance after exposure to CD produces biochemical and physiological disturbances^[4].

In this study, we report that the presence of cyclophosphamide affects granulosa cells of ovarian follicles and impairs the follicles by increasing ovarian cytoplasmic 8-OHdG expression in the granulosa cells, germinative cells and luteal cells.

In the groups in which chlorogenic acid and RA were administered simultaneously with CD, immunohistochemical 8-OHdG expression were significantly reduced

compared to the CD group. It was found that Chlorogenic acid and RA may have protective roles against CD-induced ovotoxicity and oxidative damage in rats.

With RA and CA treatments, these irregular histopathological results of ovarian tissue have decreased and the ovarian tissue was protected from ovarian toxicity and oxidative stress. The histopathological observations indicated that RA and CA were able to protect the ovarian tissue. Polyphenols can be obtained at high levels in many kinds of foods. These results emphasized the influence of this polyphenol CA and RA flowers for health, possibly preventing toxicity associated with CD. The protective mechanisms of CA are associated with oxidative DNA damage marker 8-OHdG which leads to ovotoxicity. Therefore, CA has the potential to provide cellular protection against CD-induced ovotoxicity.

To our knowledge, there is no published information about CA and RA flowers ethanol extract that protects against histopathological alterations and immunohistochemically 8-OHdG in ovarian tissue samples in Wistar female albino rats with induced ovotoxicity by single dose (200 mg/kg) cyclophosphamide.

In the current study, the histopathological results were confirmed by immunohistochemical studies, which showed that treatment with RA flower extract (300 mg/kg) and CA (100 mg/kg) reduced the necrosis in many luteal cells, severe hyperemia and haemorrhage in the vessels, degeneration in germinative cells, follicles dominated by luteal structures, and primordial follicles and against free radical production by CD-induced ovotoxicity. We found that CA and RA prevent cell damage due to by increased oxidative stress caused by CD. We suggest that CA and RA administered with chemotherapy would reduce side effects of chemotherapy complications on the ovary.

CONFLICT OF INTEREST

The authors declare no conflicts of interest regarding the present study

STATEMENT OF AUTHOR CONTRIBUTIONS

The sampling collection were made by IA and AB. Histopathological and immunohistochemical examination was performed by SY and GE. The study was designed by IA and SE. MF and AB carried out *Rhabdosciadium Anatoly* flowers collection and identification in the the study. All authors read and approved the final version of the article.

REFERENCES

1. Mansour HH, El-Kiki SM, Hasan HF: Protective effect of N-acetylcysteine on cyclophosphamide-induced cardiotoxicity in rats. *Environ Toxicol Pharmacol*, 40 (2): 417-422, 2015. DOI: 10.1016/j.etap.2015.07.013
2. Mahipal P, Pawar RS: Nephroprotective effect of *Murraya koenigii* on cyclophosphamide induced nephrotoxicity in rats. *Asian Pac J Trop Med*, 10 (8): 808-812, 2017. DOI: 10.1016/j.apjtm.2017.08.005

- 3. Basu A, Bhattacharjee A, Samanta A, Bhattacharya S:** Prevention of cyclophosphamide-induced hepatotoxicity and genotoxicity: Effect of an L-cysteine based oxovanadium (IV) complex on oxidative stress and DNA damage. *Environ Toxicol Pharmacol*, 40 (3): 747-757, 2015. DOI: 10.1016/j.etap.2015.08.035
- 4. Kalich-Philosoph L, Roness H, Carmely A, Fishel-Bartal M, Ligumsky H, Paglin S, Wolf I, Kanety H, Sredni B, Meirou D:** Cyclophosphamide triggers follicle activation and "burnout"; AS101 prevents follicle loss and preserves fertility. *Sci Transl Med*, 5(185):185ra62, 2013. DOI: 10.1126/scitranslmed.3005402
- 5. Roness H, Kashi O, Meirou D:** Prevention of chemotherapy-induced ovarian damage. *Fertil Steril*, 105 (1): 20-29, 2016. DOI: 10.1016/j.fertnstert.2015.11.043
- 6. Gürgen SG, Erdoğan D, Elmas Ç, Kaplanoğlu GT, Özer Ç:** Chemoprotective effect of ascorbic acid, α -tocopherol, and selenium on cyclophosphamide-induced toxicity in the rat ovary. *Nutrition*, 29 (5): 777-784, 2013. DOI: 10.1016/j.nut.2012.11.004
- 7. Yener NA, Sinanoglu O, Ilter E, Celik A, Sezgin G, Midi A, Devci U, Aksungar F:** Effects of spirulina on cyclophosphamide-induced ovarian toxicity in rats: Biochemical and histomorphometric evaluation of the ovary. *Biochem Res Int*, 2013:764262, 2013. DOI: 10.1155/2013/764262
- 8. Bhatt L, Sebastian B, Joshi V:** Mangiferin protects rat myocardial tissue against cyclophosphamide induced cardiotoxicity. *J Ayurveda Integr Med*, 8 (2): 62-67, 2017. DOI: 10.1016/j.jaim.2017.04.006
- 9. Miao M, Cao L, Li R, Fang X, Miao Y:** Protective effect of chlorogenic acid on the focal cerebral ischemia reperfusion rat models. *Saudi Pharm J*, 25 (4): 556-563, 2017. DOI: 10.1016/j.jsps.2017.04.023
- 10. Tajik N, Tajik M, Mack I, Enck P:** The potential effects of chlorogenic acid, the main phenolic components in coffee, on health: A comprehensive review of the literature. *Eur J Nutr*, 56 (7): 2215-2244, 2017. DOI: 10.1007/s00394-017-1379-1
- 11. Avci H, Epikmen ET, İpek E, Tunca R, Birincioglu SS, Akşit H, Sekkin S, Akkoç AN, Boyacıoğlu M:** Protective effects of silymarin and curcumin on cyclophosphamide-induced cardiotoxicity. *Exp Toxicol Pathol*, 69 (5): 317-327, 2017. DOI: 10.1016/j.etp.2017.02.002
- 12. Lyskov D, Kljuykov E, Guner ED, Samigullin T:** Molecular phylogeny of the genus *Rhabdosciadium* (Apiaceae) with description of a new species *R. anatolyi* from Hakkâri province, eastern Turkey. *Phytotaxa*, 331 (2): 253-262, 2017. DOI: 10.11646/phytotaxa.331.2.9
- 13. Gunes S, Sahinturk V, Karasati P, Sahin IK, Ayhanci A:** Cardioprotective effect of selenium against cyclophosphamide-induced cardiotoxicity in rats. *Biol Trace Elem Res*, 177 (1): 107-114, 2017. DOI: 10.1007/s12011-016-0858-1
- 14. Fouad AA, Qutub HO, Al-Melhim WN:** Punicalagin alleviates hepatotoxicity in rats challenged with cyclophosphamide. *Environ Toxicol Pharmacol*, 45, 158-162, 2016. DOI: 10.1016/j.etap.2016.05.031
- 15. Himelstein-Braw R, Peters H, Faber M:** Morphological study of the ovaries of leukaemic children. *Br J Cancer*, 38 (1): 82-87, 1978. DOI: 10.1038/bjc.1978.166
- 16. Ataya KM, Valeriote FA, Ramahi-Ataya AJ:** Effect of cyclophosphamide on the immature rat ovary. *Cancer Res*, 49 (7): 1660-1664, 1989.
- 17. Lande Y, Fisch B, Tsur A, Farhi J, Prag-Rosenberg R, Ben-Haroush A, Kessler-Icekson G, Zahalka MA, Ludeman SM, Abir R:** Short-term exposure of human ovarian follicles to cyclophosphamide metabolites seems to promote follicular activation in vitro. *Reprod Biomed Online*, 34 (1): 104-114, 2017. DOI: 10.1016/j.rbmo.2016.10.005
- 18. Şengül E, Gelen V, Gedikli S, Özkanlar S, Gür C, Çelebi F, Çınar A:** The protective effect of quercetin on cyclophosphamide-Induced lung toxicity in rats. *Biomed Pharmacother*, 92, 303-307, 2017. DOI: 10.1016/j.biopha.2017.05.047
- 19. Yerlikaya FH, Toker A, Yener Y:** Effects of acrylamide treatment on oxidant and antioxidant levels in rats. *Kafkas Univ Vet Fak Derg*, 19 (4): 607-612, 2013. DOI: 10.9775/kvfd.2012.8518