

Clinical and Radiological Outcomes of Locking Compression Plate System in Dogs with Diaphyseal Fractures: 32 Cases ^{[1][2][3]}

Özlem ŞENGÖZ ŞİRİN *  Ümit KAYA ** Burhanettin OLCAY **

[1] This research was supported by the Scientific and Technological Research Council of Turkey, TÜBİTAK/TOVAG-1060766

[2] This study derived from the thesis of the first author

[3] This study was previously presented at a scientific meeting of 2nd TSAVA "Anadolom" Continuing Education Congress, Istanbul TURKEY, 2007 and the summary of the study was pressed in abstracts book

* Department of Surgery, Faculty of Veterinary Medicine, Mehmet Akif Ersoy University, TR-15030 Burdur - TURKEY

** Department of Surgery, Faculty of Veterinary Medicine, Ankara University, TR-06110 Diskapi, Ankara - TURKEY

Makale Kodu (Article Code): KVFD-2012-7405

Summary

The aim of this study was to introduce the clinical and radiological results of long bone fractures in dogs each applied the new implant system called Locking Compression Plate (LCP). In the study 32 dogs with different breed age and sex treated using LCP system had diaphyseal zone long bone fractures. The study incorporated eight cases of each humeral, radial, femoral and tibial fractures. Analysis preoperative taking radiographs of fractures classified according to Unger system. Appropriate titanium plates and screws regarding to LCP system used for each cases surgery. Applied plate sizes, screw numbers and plate-screw density recorded immediate postoperative. Each case was evaluated clinically and radiologically on the 10th, 25th postoperative days, and the 2nd, 3rd months. By the way, postoperatively on days 10 and 25 lameness and pain on the affected limb was also scored and recorded. Most often encountered complications as osteomyelitis, delayed union, malunion and nonunion findings were not recorded. Twenty seven cases of 32 healed with primary bone healing while others healed with little callus formation.

Keywords: Fracture healing, Dog, Long bone fractures, Locking compression plate, Radiology

Köpeklerde Diyafizer Kırıkların Kilitli Kompresyon Plak Sistemiyle Sağaltımının Klinik ve Radyolojik Sonuçları: 32 Olgu

Özet

Bu çalışmada amaç, yeni bir implant sistemi olan Kilitli Kompresyon Plak (LCP) uygulamalarının, köpek uzun kemik kırıklarındaki klinik ve radyolojik sonuçlarının ortaya konmasıdır. Çalışmada 32 adet değişik ırk, yaş ve cinsiyetteki köpekte diyafizer bölge uzun kemik kırıkları LCP sistem kullanılarak sağaltıldı. Çalışmaya 8'er adet humerus, radius-ulna, femur ve tibia kırığı dahil edildi. Preoperatif alınan radyografiler incelenerek kırıklar Unger sistemine göre sınıflandırıldı. Operasyonlarda her bir olguya uygun boyutlarda LCP sistem setlerine ait titanyum plak ve vidalar kullanıldı. Kullanılan plak boyutu, vida sayısı ve plak-vida dansitesi kaydedildi. Her olgu klinik ve radyolojik olarak 10. ve 25. günler ile 2. ve 3. aylarda değerlendirildi. Ayrıca postoperatif 10. ve 25. günlerde ilgili ekstremitedeki topallık ve ağrı duyumu skorlanarak kaydedildi. Literatür verilere göre sık karşılaşılan kırık komplikasyonları olan osteomyelitis, gecikmeli kaynama, hatalı kaynama, kaynama yokluğu bulgularına rastlanmadı. Çalışmadaki 32 olgudan 27'sinde primer kemik kaynamasıyla geri kalanlarda ise hafif kallus oluşumuyla iyileşmenin sağlandığı görüldü.

Anahtar sözcükler: Kırık iyileşmesi, Köpek, Uzun kemik kırığı, Kilitli kompresyon plak, Radyoloji

INTRODUCTION

Development of the locked compression plates (LCP) was the result of a combined work of clinicians, researchers and industry. For the first time in 1998, Prof. Dr. Michael Wagner ¹ tried to use threaded screws along with standard

screws in combination ². Clinical usage of LCP began in March 2000, and it was first used in veterinary medicine in 2005. The development of a combination hole united the two techniques in a plate. The LCP allowed for the



İletişim (Correspondence)



+90 248 2132106



sengozozlem@gmail.com

combination of conventional compression plating and fixation with an internal fixator³. The combination of two entirely different technologies in a single implant is a logical, practical and simple solution. LCP does not press to the bone unlike conventional plates and thus do not need to be contoured exactly to the bone⁴. LCP can be applied as a compression plate by using the conventional holes, as a locking internal fixator by using threaded holes, or as a combination/hybrid plate, which incorporates both types of holes^{1,4}. Four different screws can be used with the LCP: the standard cortical screw, the standard cancellous screw, the self-tapping locking screw and the self-drilling locking screw⁵. The screws can be either monocortical (unicortical), so they only penetrate one cortex of the bone, or bicortical in that they penetrate both bone cortices⁴. Locked screws can be fixed when used perpendicular to the plate, however, the insertion angle could be used up to 5° with high stability. This construct inhibits the toggle or tilt motion between the plate and screws. This construction is four times stronger than a conventional system, where motion is possible between the screw and plate. Locking plate technology allows the surgeon to use one implant system, in different modes, for the treatment of fractures having variable fracture types, bone quality and concurrent soft tissue trauma. Since they depend on the screw purchase in bone locking internal fixators, these are more advantageous in comminuted and osteoporotic fractures⁶.

Conventional plating systems provide stability due to the friction between the bone and plate as the screws are tightened⁷. The LCP can be used in a similar fashion using conventional screws. It can also be used as an internal fixator using locking screws⁸. Locked plates are also ideal for minimally-invasive fracture repair⁷. The shape and the cross-sectional geometry are similar to the limited-contact dynamic compression plate (LC-DCP), with tapered ends to allow sub-muscular insertion⁸. When using LCP like a conventional LC-DC Plate, the implant must be shaped accurately. The friction allows for load transfer from one main fragment to the other. In case a LCP is used as an internal fixator, the exact adaptation of the implant to the bony surface is not mandatory. Load transfer occurs by locking. Once the fracture fragments are properly aligned, tightening of the screws into the conical threaded plate holes does not lead to a secondary displacement and therefore no compression of the soft tissue in the interface plate-bone occurs⁵. The LCP combi hole reflects the clinical desire for integration of two treatment technologies into one implant system, without compromising the mechanical properties of the two-plate anchorage technologies². Because of the specific design of the plate hole (Combi™), the locked compression plate can be used as a standard plate with standard screws and as an internal fixator using locking screws^{5,8}. The internal fixator can also be utilized as a neutralizing or bridging implant⁸. These plates are designed with a threaded interface between the screw head and the screw hole to provide angular stability and to avoid bone-implant contact^{1,9}.

When plating with conventional techniques, the surgeon decides on the degree of tightening by the "finger tightening" technique¹⁰. Torque Limiting Attachment (TLA) in LCP instrumentation eliminates this situation and prevents over-tightening, especially in locked screws^{11,12}. The maximum tightening limit of the screw is 1.5 Nm when using 3.5 mm, 4.5 Nm when using 4.5 mm or 5.0 mm LCP systems with TLA¹¹. The LCP system is commonly used for fracture repair in human fracture patients¹³. Experience with the LCP system in veterinary fracture repair is limited^{3,8,12,14}.

The purpose of this study, was to investigate the healing of diaphyseal long bone fractures clinically and radiographically, in dogs operated with LCP.

MATERIAL and METHODS

This study included 32 dogs of different breeds, age, genders and body weights. The dogs were admitted to the Ankara University, Faculty of Veterinary Medicine, Department of Surgery, for long bone fractures (humerus, radius-ulna, femur, tibia-fibula), which were diagnosed clinically and radiologically. The cases were classified using the fracture classification system of Unger et al.¹⁵. The routine soft tissue and orthopaedic surgery instruments, 3.5 mm and 4.5 mm LCP instruments¹¹ were used.

All the animals received 0.2 mg/kg (0.4 mL/10 kg) subcutaneous (SC) single dose of Meloxicam (Maxicam®, 5 mg/50 ml, Sanovel) as analgesic and cefazolin sodium (Sefazol®, 500 mg IV, Mustafa Nevzat) 22 mg/kg intravenously for antibiotherapy approximately 30 min prior to surgery. 0.5 mg/kg diazepam (maximum 25 mg) (Diazem ampule® IM/IV, 10 mg/2 mL, Deva) was used to induce anaesthesia, followed by propofol (Propofol injectable emulsion® IV, 200 mg/20mL, Abbott) for endotracheal intubation. Epidural 1.5 mg/kg bupivacain (Marcain® %0.5, 20 mL, Astra Zeneca) was administered after induction for tibial and femoral fractures. The maintenance of the anesthesia was provided by 2%-3% isoflurane (Forane solution®, 100 mL, Abbott) through spontaneous ventilation. The operation site was prepared for the relevant technique approach (craniolateral approach for femoral, humeral and radial fractures, medial approach for tibial fractures). Medial approach in tibial fractures was performed avoiding any damage to the neurovascular band. After draping the surgical incision site, the plates and screws were selected using the AO/ASIF System. In addition, various strengths of TLAs (1.5 Nm for 3.5 mm LCP implants or 4.5 Nm for 4.5 mm LCP implants), designed to place LCP implants were used to fix the screws to the plate. All cases received SC amoxicillin-clavulanic acid (Synulox®, 40 mL injectable vial, Pfizer) postoperatively for five days, and SC meloxicam (Maxicam®, 5 mg/50 mL, Sanovel) for three days. No other medication other than the NSAIDs was used to control postoperative pain. Immediately after the operations cranio-caudal (CrCd) and mediolateral (ML) radiographs were

taken to control the reduction of fracture site. Following the operation, soft bandage was used to protect the operation wound and to restrict the mobility of the affected extremity. The bandage was removed on postoperative 10th day to check the operation wound. Following the first control of the patients, the bandages were not repeated and the

owners were directed to limit their pets movements. The clinical healing process was followed up by radiological examination and bearing weight of limb when walking on leash. Data recorded was signalment (age, breed, gender, body weight) and cause of fracture, type of fracture, plate size, lameness and pain score in 10th and 25th days ([Table 1](#)).

Table 1. Summary of clinical data for 32 dogs with diaphyseal long bone fractures treated with locking compression plate system

Tablo 1. Kilitli kompresyon plak sistemiyle tedavi edilen diyafizer uzun kemik kırığı bulunan 32 köpeğe ait klinik verilerin özeti

Case No	Age (Month)	Breed	Gender	Cause of Fracture	Body Weight (kg)	Type of Fracture	Plate Size	Lameness 10 th Day	Lameness 25 th Day	Pain 10 th Day	Pain 25 th Day
1	12	Anatolian Shepherd Dog	♂	Direct trauma	45	32 A3	4.5	1	0	2	1
2	11	Cross	♂	Direct trauma	27	42 A2	3.5	1	0	2	1
3	18	English Setter	♂	Crushed by car	30	32 B2	4.5	1	0	3	2
4	12	Siberian Husky	♂	Unknown trauma	26	22 B2	3.5	1	0	3	2
5	30	Labrador Retriever	♀	Crushed by car	35	42 C1	3.5	1	0	2	1
6	72	German Shepherd Dog	♀	Crushed by car	32	42 A3	3.5	1	0	2	1
7	5	Cross	♂	Unknown trauma	15	32 A3	3.5	1	0	2	1
8	12	Labrador Retriever	♂	Crushed by car	40	32 A3	4.5	1	0	2	1
9	12	Cross	♀	Direct trauma	22	22 B1	3.5	1	0	2	1
10	10	Anatolian Shepherd Dog	♂	Crushed by car	33	22 A2	3.5	1	0	2	1
11	18	Siberian Husky	♀	Crushed by car	22	22 A2	3.5	1	0	2	1
12	12	Siberian Husky	♂	Unknown trauma	24	42 A3	3.5	1	0	3	2
13	24	Anatolian Shepherd Dog	♂	Direct trauma	35	42 C1	4.5	1	0	2	1
14	10	Cross	♂	Crushed by car	20	22 A2	3.5	1	0	2	1
15	24	Cross	♀	Crushed by car	30	32 B2	4.5	1	0	2	1
16	36	Cross	♀	Crushed by car	18	42 A2	3.5	1	0	2	1
17	9	Labrador Retriever	♂	Crushed by car	20	42 B2	3.5	1	0	2	1
18	11	Anatolian Shepherd Dog	♀	Crushed by car	32	12 A3	4.5	1	0	2	1
19	18	Anatolian Shepherd Dog	♂	Unknown trauma	41	22 A2	4.5	1	0	2	1
20	24	Anatolian Shepherd Dog	♂	Direct trauma	35	42 C1	4.5	1	0	2	1
21	12	German Shepherd Dog	♀	Crushed by car	18	12 A2	3.5	1	0	2	1
22	24	Cross	♂	High rise trauma	22	22 A2	3.5	1	0	2	1
23	48	Cross	♂	Unknown trauma	21	22 A2	3.5	2	0	3	1
24	18	Cross	♀	Crushed by car	23	12 A3	3.5	1	0	2	1
25	11	Cross	♂	Crushed by car	20	32 C1	3.5	1	0	2	1
26	9	German Shepherd Dog	♀	Crushed by car	28	32 A3	4.5	1	0	2	1
27	18	Cross	♂	Direct trauma	21	42 A3	3.5	1	0	2	1
28	36	Cross	♀	Crushed by car	23	12 A3	3.5	1	0	2	1
29	24	German Shepherd Dog	♂	Unknown trauma	25	12 A2	3.5	1	0	2	1
30	8	Cross	♂	Crushed by car	20	12 A2	3.5	1	0	2	1
31	48	Cross	♀	Crushed by car	19	12 A3	3.5	1	0	2	1
32	12	Anatolian Shepherd Dog	♀	Unknown trauma	47	12 A2	4.5	1	0	2	1

The cases were observed for lameness using a 10 m extension collar, and were graded by the "Score system for assessing the lameness in dogs undergoing fracture operation" reported by Bergmann et al.¹⁶. This assessment was graded as: 0 (stands and walks normally), 1 (stands normally, slight lameness when walking), 2 (stands normally, obvious lameness when walking), 3 (stands abnormally, slight to obvious lameness when walking) and 4 (non weight bearing lameness). The perception of pain in the affected extremity was assessed by palpation, using the scoring system reported by Cross et al.¹⁷. This evaluation was graded as: 1 (no pain response on manipulation of limb), 2 (mild-allows manipulation of limb through normal range of motion, but acknowledges pain by turning head or pulling away), 3 (moderate-will not allow manipulation through normal range of motion; acknowledges pain as score 2) and 4 (severe-will not allow manipulation of limb). The healing process was assessed radiologically using the following criteria; loss of sharp fracture edges¹⁰, loss of fracture line¹⁸, cortical continuity^{10,19}, presence of callus^{19,20}, presence or absence of primary and secondary reduction loss¹⁵, delayed union, lack of union²¹, and osteomyelitis²².

RESULTS

Of the 32 cases included in the study, 3% were English Setter, 9% were Labrador Retriever, 9% were Siberian Husky, 13% were German Shepherd, 22% were Anatolian Sheep Dog and 44% were Cross-breed dogs. 41% of the cases were female and 59% male, their ages varied between 5 months and 6 years (mean 20.2 months). The body weights were between 15 kg and 47 kg (mean 27.2). All cases were

also grouped by cause of fracture. According to the history information obtained from the patient owners, the reasons for fractures were listed as follows: 3% high rise syndrome, 22% cause unknown, 19% direct trauma and 56% traffic accident. The fractures were classified according to the location and direction of the fracture. The percentages were: 25% diaphyseal simple transversal, 6% diaphyseal simple oblique, 22% diaphyseal reducible wedge, 3% distal diaphyseal multifragmentary, 3% diaphyseal, simple, ulnar fracture, 9% diaphyseal, transversal, 19% distal diaphyseal, simple, 13% diaphyseal, oblique.

None of the cases presented neurological defects. There were no anesthetic complications. Choice of implant size was made in relation to dog's body size and anatomical region (Table 1). Except for two cases axial alignment was restored successfully. These two cases (11 and 32) had an anatomic loss of reduction.

With the radiological examinations performed on the postoperative 10th day, disappearance of the sharp ends of the fracture fragments were noted (Fig. 1). In addition, cases 11 (Fig. 2) and 32 had anatomic loss of reduction, and in cases 1, 21 (Fig. 3) and 22, early callus formation was observed. There were no complications with wound healing. In the postoperative 10th days, according to physical examinations except for case 23, lameness score was reported as 1, whereas case 23 presented a lameness score of 2. Pain score was 3 in four cases (3, 4, 12, 23) and 2 in others.

The 25th day radiographic examinations showed the disappearance of the fracture line in all cases and callus formation in cases 1, 11, 21, 22 and 32. Cases 11 and 32

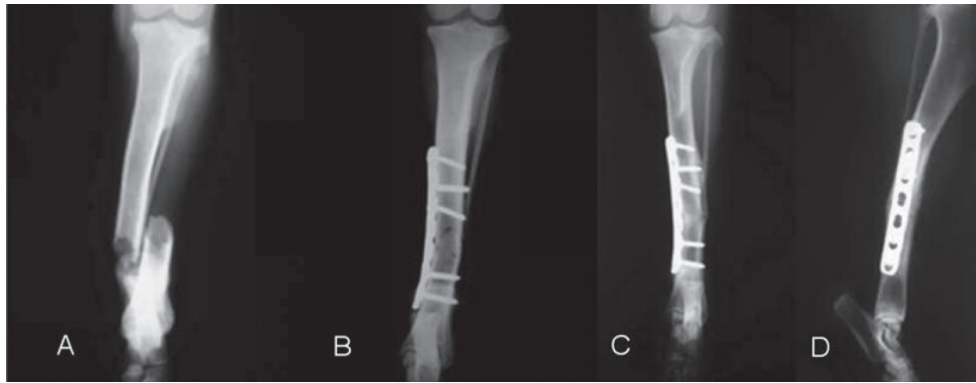
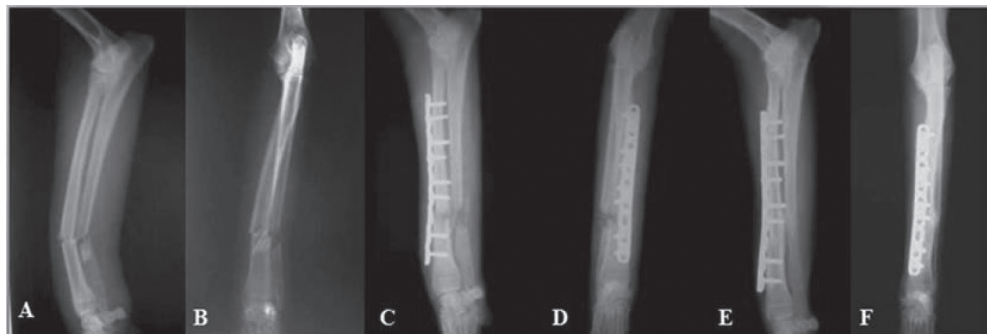


Fig 1. Preoperative CrCd radiograph (A) and postoperative 10th day CrCd radiograph (B), 60th day CrCd radiograph (C), 60th day ML radiograph (D) of the case 5. Locking screws are placed bicortically

Şekil 1. Olgu 5'in preoperatif CrCd radyografisi, postoperatif 10.gün CrCd radyografisi (B), 60.gün CrCd radyografisi (C), 60.gün ML radyografisi (D). Kilitli vidalar bikortikal yerleştirildi

Fig 2. Failure of anatomic reduction. Pre-operative ML (A), CrCd (B) radiographs and postoperative 10th day ML (C), CrCd (D) radiographs, 90th day ML radiograph (E), 90th day CrCd radiograph (F) of the case 11. The slight callus formation was seen on the 90th day radiograph

Şekil 2. Anatomik redüksiyon hatası. Olgu 11'in preoperatif ML (A), CrCd (B) radyografileri ve postoperatif 10. gün ML (C), CrCd (D) radyografileri, 90. gün ML radyografisi (E), 90. gün CrCd radyografisi (F). 90. gün radyografisinde hafif kallus formasyonu görülmektedir



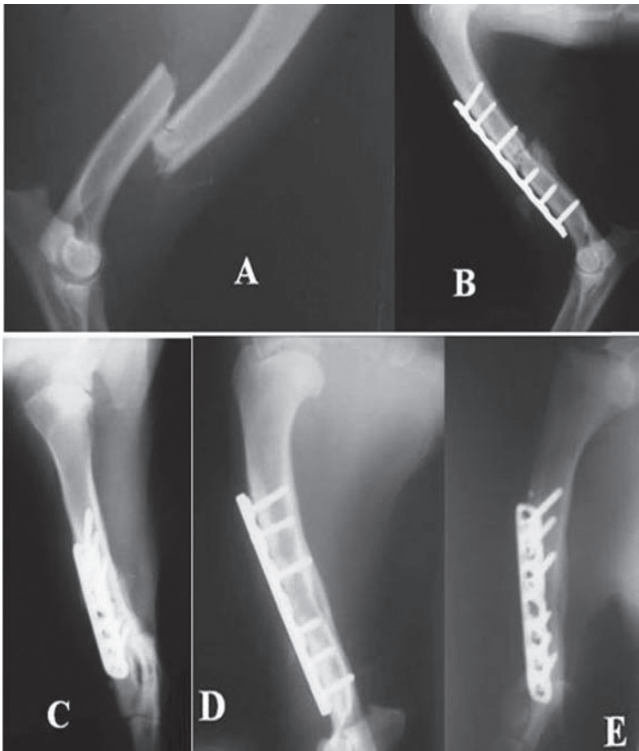


Fig 3. Radiographs are taken preoperative CrCd (A) and postoperative 10th day ML (B), 25th day CrCd (C), 90th day ML (D) and 90th day CrCd (E) of the case 21

Şekil 3. Olgu 21'in preoperatif CrCd (A) ve postoperatif 10.gün ML (B), 25.gün CrCd (C), 90. gün ML (D), 90. gün CrCd (E) radyografileri alındı

showed anatomic loss of reduction, and loss of secondary reduction in the X-rays. During the physical examinations on the 25th day, the lameness score was evaluated as 0 in all cases: however, the pain score was 2 in three cases (3, 4, 12) and 1 in others.

With radiographs taken on the 60th day, it was determined that cortical integrity was sustained and reshaping had begun. In addition, cases 1, 11, 21, 22 and 32 showed reduced callus presence. After the clinical examination on the 25th day, pain and lameness scores were not reevaluated.

In the radiographic evaluation performed in the 90th day, it was recorded that all cases had cortical continuity, complete loss of fracture line and there was evidence of re-modelling. It was also found that the callus size had decreased in cases 1, 11, 21, 22 and 32. There was no evidence of osteomyelitis, delayed union, or lack of union on the follow-ups until the end of 3rd months.

Telephone interviews of owner's to assess their dog's limb function occurred between 6 and 12 months. Functional outcome was excellent in 26 dogs but the other owners could not be reached.

DISCUSSION

There is still little data on LCP systems in veterinary medicine. Osteosynthesis with plates is one of the most stable

fixation techniques for veterinary orthopedic surgeons. Locked plates are designed to enable flexible internal fixation without disturbing the periosteal biology⁵. Since they do not exert pressure on the periosteal blood flow, they do not hinder fracture healing and fracture hematoma²¹.

During the 3 months clinical and radiological follow up period, no fracture complications other than mild reduction loss in 2 cases (anatomic) were noticed in different control intervals. This showed that the system provides sufficient stability. Locked plating enables stable fracture fixation without the need for compressing the plate directly onto the bony surface or complete plate contouring^{5,9}. Combination (Hybrid) technique was performed using both conventional and locking screws on the same plate hole. Principally the standard screws were always placed first. Since the LCP combination technique was used in this study, plates were contoured only slightly.

There are three main problems in internal fixation with plate and screws. These are primary loss of reduction, secondary loss of reduction, and compression of the periosteum leading to a disturbance of the cortical blood supply^{1,5,23}. These problems were unresolved until the innovation of the LCP system^{11-13,23-25}.

Two cases (case 11 and 32) in the study were found to have failure of anatomic reduction intraoperatively and on radiological assessment immediately following the operation. However, this was not found in subsequent examinations, suggesting this may have been related to both the mild loss of reduction and the stability of the implant.

Implant failure (plate failure or breakage of the screw) is a complication reported in 7% of plate fixations²⁶. Sommer et al reported two plate fractures in 144 patients with LCP, despite stable screws²⁷. According to a biomechanical study made in 2003, damage occurred on the DCU (Dynamic Compression Unit) when the LCP was exposed to overload²³. Stoffel reported consistent results with Frigg. Stoffel reported that plate failure was observed on the DCU when the plates had a smaller cross sectional area²⁸. In our study, no case showed complications such as plate torsion or breakage. Only for the case no, 10, where the locking screw head was broken, could be a defective screw which in controls showed no secondary reduction loss postoperatively.

No complications, such as soft tissue and/or bone infection, delayed union or non-union were observed. This was considered to be related to the right choice of antibiotic, implant, surgical technique and postoperative care.

In a study comparing vitalium, stainless steel and titanium implants on a rabbit tibia, Linder and Lundsgok concluded that titanium implants were significantly better than other implants in bone healing²⁹. Millar et al.³⁰ compared stainless steel and titanium screws in their histological study on adult beagle dog bones, and reported that removal of the titanium which was as an expensive system, was not

required, and that it had better tissue adaptation³⁰. As we also used titanium plates and screws, they were not removed.

When using the TLA, the screw is securely locked to the plate when a "click" is heard. In this study, we used TLA; thus, a standard power was applied.

It was reported that there were two main issues when evaluating the clinical outcome of the fracture: Weight-bearing on the affected limb and presence of pain when palpating the fracture line^{21,31-33}. Various scores on the pain scale were recorded according to the type of surgery, age, breed and fright displayed by the case¹⁶. Although it does not directly evaluate pain, lameness can be used as a pain indicator³⁴. In this study, the lameness scores, declined parallel with pain scores.

All the cases other than 5 showing callus formation (case 1, 11, 21, 22 and 32) healed with primary bone healing, however, the 5 cases healed secondarily as a result of lack of absolute stabilization and/or flexible fixation.

The clinical and radiological outcomes of the LCP system were found to be promising. More comprehensive detailed studies with the use of the results of this study are required, as there are little scientific data to be followed for the clinical use of LCP and the routine clinical use of this system in veterinary medicine.

REFERENCES

- Wagner M:** General principles for the clinical use of the LCP. *Injury*, 34 (2): 31-42 2003.
- Frigg R:** Development of the Locking Compression Plate. *Injury*, 34 (2): 6-10, 2003.
- Plecko M, Lagerpusch N, Pegel B, Andermatt D, Frigg R, Koch R, Sidler M, Kronen P, Klein K, Nuss K, Gedet P, Bürki A, Ferguson SJ, Stoeckle U, Auer JA, von Rechenberg B:** The influence of different osteosynthesis configurations with locking compression plates (LCP) on stability and fracture healing after an oblique 45° angle osteotomy. *Injury*, 43 (7): 1041-1051, 2012.
- Miller DL, Goswami T:** A review of locking compression plate biomechanics and their advantages as internal fixators in fracture healing. *Clin Biomech (Bristol, Avon)*, 22 (10): 1049-1062, 2007.
- Gautier E, Sommer C:** Guidelines for the clinical application of the LCP. *Injury*, 34 (2): 63-76, 2003.
- Şengöz Ö, Olcay B:** A new implant system called locked compression plate in veterinary practice. *Veteriner Cerrahi Dergisi*, 14 (1): 44-47, 2008.
- Hasenboehler E, Rikli D, Babst R:** Locking compression plate with minimal invasive plate osteosynthesis in diaphyseal and distal tibial fracture: A retrospective study of 32 patients. *Injury*, 38 (3): 365-370, 2007.
- Haaland PJ, Sjöström L, Devor M, Haug A:** Appendicular fracture repair in dogs using the locking compression plate system: 47 cases. *Vet Comp Orthop Traumatol*, 22 (4): 309-315, 2009.
- Aguila AZ, Manos M, Orlansky AS, Todhunter RJ, Trotter EJ, Van der Meulen MC:** *In vitro* biomechanical comparison of limited contact dynamic compression plate and locking compression plate. *Vet Comp Orthop Traumatol* 18 (4): 220-226, 2005.
- Piermattei DL, Flo GL:** Fractures: Classification, Diagnosis, and Treatment, In, Piermattei DL, Flo GL (Eds): Brinker, Piermattei, and Flo's Handbook of Small Animal Orthopedics and Fracture Repair. 4th ed., pp.125-159, Saunders, Philadelphia, 2006.
- Synthes:** Locking Compression Plate (LCP) System Brochure, West Chester, PA 2003. http://www.synthes.com/sites/NA/Products/Trauma/PlateandScrewSystems/Pages/Locking_Compression_Plate___28LCP_29_System.aspx, Accessed: October 2004.
- Schwandt CS, Montavon PM:** Locking Compression Plate fixation of radial and tibial fractures in a young dog. *Vet Comp Orthop Traumatol*, 18 (3): 194-198, 2005.
- Greife RM, Archdeacon MT:** Locking plate technology: Current Concepts. *J Knee Surg*, 20 (1): 50-55, 2007.
- Olcay B, Şengöz Ö, Kaya Ü:** Clinical and Radiological evaluation of the Locking Compression Plate (LCP) application in long-bone fractures in dogs TÜBİTAK-TOVAG Project Number: 106O766, 2008.
- Unger M, Montavon PM, Heim UFA:** Classification of fractures of long bones in the dog and cat: Introduction and clinical application. *Vet Comp Orthop Traumatol*, 3, 41-50, 1990.
- Bergmann HM, Nolte I, Kramer S:** Comparison of analgesic efficacy of preoperative or postoperative carprofen with or without preincisional mepivacaine epidural anesthesia in canine pelvic or femoral fracture repair. *Vet Surg*, 36 (7): 623-632, 2007.
- Cross AR, Budsberg SC, Keefe TJ:** Kinetic gait analysis assessment of in a sodium urate-induced synovitis model in dogs. *Am J Vet Res*, 58 (6): 626-631, 1997.
- Sande R:** Radiography of orthopaedic trauma and fracture repair. *Vet Clin North Am: Small Anim Pract*, 29 (5): 1247-1260, 1999.
- Greiff J:** Bone healing in rabbits after compression osteosynthesis: A comparative study between the radiological and histological findings. *Injury*, 10 (4): 257-267, 1979.
- Cornell CN, Lane JM:** Newest factors in fracture healing. *Clin Orthop Relat Res*, 277, 297-311, 1992.
- Bhandari M, Guyatt GH, Swiontkowski MF, Tornetta P, Sprague S, Schemitsch EH:** A lack of consensus in the assessment of fracture healing among orthopaedic surgeons. *J Orthop Trauma*, 16 (8): 562-566, 2002.
- Griffon DJ:** Fracture healing. In, Johnson AL, Houlton EF, Vannini R (Eds): AO Principles of Fracture Management in the Dog and Cat. 1st ed., pp. 72-98, AO Publishing, Switzerland, 2005.
- Frigg R:** Locking compression plate (LCP): An osteosynthesis plate based on the dynamic compression plate and the point contact fixator (PC-Fix). *Injury*, 32, 63-66, 2001.
- Koch D:** Implants: Description and application. In, Johnson AL, Houlton EF, Vannini R (Eds): AO Principles of Fracture Management in the Dog and Cat. 1st ed., pp 26-72, AO Publishing, Switzerland, 2005.
- Namazi H, Mozaffarian K:** Awful considerations with LCP instrumentation: A new pitfall. *Arch Orthop Trauma Surg*, 127, 573-575, 2007.
- Riener BL, Butterfield SL, Burke CJ:** Immediate plate fixation of highly comminuted femoral diaphyseal fractures in blunt polytrauma patients. *Orthopedics* 15, 907-916, 1992.
- Sommer C, Gautier E, Müller M, Helfet DL, Wagner M:** First clinical results of the Locking Compression Plate (LCP). *Injury*, 34, 43-54, 2003.
- Stoffel K, Dieter U, Stachowiak G, Gächter A, Kuster MS:** Biomechanical testing of the LCP-how can stability in locked internal fixators be controlled? *Injury*, 34, 11-19, 2003.
- Linder L, Lundskog L:** Incorporation of stainless steel, titanium and vitallium in bone. *Injury*, 6, 277-285, 1975.
- Millar BG, Frame JW, Browne RM:** A histological study of stainless steel and titanium screws in bone. *British Journal of Oral and Maxillofacial Surgery*, 28, 92-95, 1990.
- Nicholls PJ, Berg ED, Bliven FE, Kling JM:** X-Ray Diagnosis of Healing Fractures in Rabbits. *Clinical Orthopaedics and Related Research*, 142, 234-236, 1979.
- Frost HM:** The biology of bone healing. An overview for clinicians. Part II. *Clin Orthop Relat Res*, 248, 294-309, 1989.
- Starr AJ:** Fracture repair: Successful advances, persistent problems, and the psychological burden of trauma review. *J Bone Joint Surg Am*, 90, 132-137, 2008.
- Hudson JT, Slater MR, Taylor L, Scott HM, Kerwin SC:** Assessing repeatability and validity of visual analogue scale questionnaire for use in assessing pain and lameness in dogs. *Am J Vet Res*, 12, 1634-1643, 2004.