

Survey on the Presence of Nematodes and Associated with Pathology in Marine Mammals from Turkish Waters

Gökmen Zafer PEKMEZCİ¹  Banu YARDIMCI¹ Ali Tümay GÜRLER²
Cenk Soner BÖLÜKBAŞ² Mustafa AÇICI² Şinasi UMUR²

¹ Department of Aquatic Animal Diseases, Faculty of Veterinary Medicine, University of Ondokuz Mayıs, TR-55139 Kurupelit, Samsun - TURKEY

² Department of Parasitology, Faculty of Veterinary Medicine, University of Ondokuz Mayıs, TR-55139 Kurupelit, Samsun - TURKEY

Makale Kodu (Article Code): KVFD-2013-9409

Summary

Presence of marine mammal nematodes in Turkey is poorly known. One bottlenose dolphin (*Tursiops truncatus*) and four harbour porpoises (*Phocoena phocoena*) stranded on the Turkish coast were examined at necropsy between 2009 and 2012. Harbour porpoise stranded from Marmara Sea were only infected by three species of lungworms (Metastrongyloidea): *Stenurus minor*, *Halocercus invaginatus* and *H. taurica*. Anisakid, pseudaliid, filarioid and spirurid nematodes were not found in the investigated organs and alimentary canal from harbour porpoises and bottlenose dolphin from Black Sea. The present study represents the first geographic record of *H. taurica* from Turkish waters. Moreover, *S. minor* is the first and new host record of harbour porpoise from the coast of Black Sea. Additionally, pathological findings associated with lungworms are also present.

Keywords: Metastrongyloid nematodes, Marine mammals, Pathological findings, Turkish waters

Türkiye Suları'ndaki Deniz Memelilerinde Nematodların Varlığının Araştırılması ve Patolojisi

Özet

Türkiye'deki deniz memelilerinin nematodlarının varlığı yeterince bilinmemektedir. 2009-2012 yılları arasında sahile vuran bir şişe burunlu yunus (*Tursiops truncatus*) ile dört liman yunusunun (*Phocoena phocoena*) nekropsileri yapıldı. Marmara Denizinde sahile vuran liman yunusu sadece üç tür akciğer kurdu (Metastrongyloidea): *Stenurus minor*, *Halocercus invaginatus* ve *H. taurica* ile enfekte idi. Karadeniz'deki şişe burunlu yunus ile liman yunuslarının sindirim kanalı ve incelenen organlarında anisakid, filarioid, pseudaliid ve spirurid nematodlar bulunamadı. Bu araştırma Türkiye sularında *H. taurica*'nın ilk coğrafik kaydını göstermektedir. Bununla birlikte *S. minor* Karadeniz kıyılarındaki liman yunuslarında ilk ve yeni konak olarak kaydedilmiştir. Ayrıca akciğer kurtları ile ilgili patolojik bulgular da sunulmuştur.

Anahtar sözcükler: Metastrongyloid nematodlar, Deniz memelileri, Patolojik bulgular, Türkiye suları

INTRODUCTION

Cetaceans are parasitized by a wide diversity of endo and ectoparasites in various tissues, organs and cavities [1]. Damage to and mortality of individuals and populations caused by parasitic infections are dependent upon several factors, including the parasite species, its abundance, the health status of the host and competition with other pathogens. Parasites of cetaceans can influence the behavior of their hosts, population size, the dynamics of

the food chain and community structure [2]. Nematodes represent the broadest group of parasites in the marine mammals. The Crassicaudinae are the largest nematodes in cetaceans. Pseudaliids often infect the respiratory system, causing sufficient damage to affect survival. Filarioids are highly pathogenic in pinnipeds and are probably responsible for significant mortality, especially in young animals. Anisakid nematodes in the stomach are of little



İletişim (Correspondence)



+90 362 3121919



zpekmezci@omu.edu.tr

consequence to the host [3]. The parasitic fauna of cetaceans in Turkey is still little known. Parasites have been reported in a few species of cetaceans in Turkey, including striped dolphins and harbour porpoises [4,5]. Therefore, this is the first geographic record of *Halocercus taurica* from Turkish waters. Moreover, *Stenurus minor* was the first record of harbour porpoise from the Black Sea. Additionally, pathological findings associated with lungworms are also presented.

MATERIAL and METHODS

Parasites were collected from stranded or dead one bottlenose dolphin (*Tursiops truncatus*) and four harbour porpoises (*Phocoena phocoena*) in Turkish waters, during the period 2009 and 2012. One harbour porpoise were obtained from the Marmara Sea, while the others were collected from the Black Sea. Postmortem examinations were performed according to standardized European necropsy protocol for cetaceans [6]. Lung nematodes were detected by visual observation of light-colored nodules on the surface, by palpation, or by searching major airways. Nematodes were collected during the necropsy. After collection, nematodes were fixed and preserved in 70% ethanol. Nematodes were cleared in phenol from 5 to 60 min, depending on the size and thickness of the parasite. After clarification, the parasites were mounted on slides. The internal structures were visualized under a Nikon Eclipse 80i light microscope equipped with differential interference contrast (Nomarski DIC) optics and morphological identification was based on identification keys [7-9]. Accurate estimates of intensity of parasites were generally not possible. The nematodes were photographed the digital image analysis system (Nikon Digital Sight DS-L1). After necropsy of porpoises, lung tissue samples were fixed in 10% neutral formaldehyde solution for pathological examination. Tissue samples were routinely taken processed and embedded in paraffin. Tissue sections 4–6 μ in width were stained with haematoxyline-eosin (HE) and examined under light microscope (Nikon Eclipse 80i).

RESULTS

Parasitological investigations were carried out on bottlenose dolphin and harbour porpoises originating from the Turkish waters. *S. minor*, *H. invaginatus* and *H. taurica* were only found in the lungs of porpoise from Gemlik Bay (40°26'N, 29°09'E), Marmara Sea, Turkey (Fig. 1e-g). This is the first geographic record of *H. taurica* from the Turkish waters. Moreover, *S. minor* is the first and new host record of harbour porpoise from the coast of Black Sea. Filarioids, pseudaliids, spirurids and anisakids, especially *Anisakis* spp., were not found in the investigated organs and alimentary canal from porpoises and the bottlenose dolphin in Black Sea. In the macroscopic examination, whitish to grey nodules that were raised above the pleural

surface, pulmonary parenchyma, and in the bronchi, and bronchioles, varying between pin point to 0.5 cm diameter over the surfaces and cross sections were observed. The cross sections of these nodules revealed a thick cystic capsule formation with parasitic remnants inside. There were also congestion and emphysema observed in the lung tissue samples (Fig. 1a). In the microscopic examination, different maturation stages according to three species of parasites were observed in bronchus, bronchioles, alveolar lumens and interstitial tissues covered with fibrous connective tissue. There was also concomitant bronchointerstitial pneumonitis composed of mononuclear and necrotic cells. In addition, dystrophic calcification and bacterial colonies were seen in the areas close to the parasites (Fig. 1b-d).

DISCUSSION

There was little evidence on the presence of parasitic infections in marine mammals in Turkey. Numerous parasitological studies have been carried out on marine mammals [10-14] but few were reported on parasites of marine mammals from Turkish waters [4,5]. *Anisakis* spp., *Contracaecum* spp. and *Pseudoterranova* spp. were collected from striped dolphins (*Stenella coeruleoalba*) in Eastern Mediterranean coast [4]; while ascaridoids were not found in dolphin and porpoises from Black Sea in the current study. In concordance to these findings, larval ascaridoids, especially *Anisakis* spp. larvae, were not found in more than ten fish species (mackerel, whirling, anchovy, etc.) from Black Sea [15]. A molecular study should be performed for the identification of ascaridoids from Turkish cetaceans. Parasitism of the respiratory system is a relatively common finding in stranded cetaceans, resulting in mild chronic lesions. Metastrongyloid nematodes usually associated with respiratory system, cranial sinuses, middle ear, and circulatory system of their odontocete hosts. Lungworms can be quite pathogenic, but the infections are not the primary cause of death. Lungworm (Metastrongyloidea: Pseudaliidae) are known to occur in the lungs of harbour porpoises [9,12,16]. Lungworms of the family Pseudaliidae, genera *Halocercus*, *Pseudalius* and *Stenurus* are the most common parasites found in cetaceans [16]. Lungworms have been implicated as a common and important contributing factor in the mortality of harbour porpoise [17]. Infections with *Halocercus* spp. are usually confined to the lungs, but other pseudaliids (e.g. *Stenurus* spp.) invade the pulmonary and mesenteric arteries, cranial sinuses, brain, middle and inner ears, eustachian tube and oral cavity [18]. Pseudaliid nematodes have been found in the respiratory and alimentary tract and auditory/cranial sinuses on *P. phocoena* originating from different areas: the German North Sea, the German Baltic, southern Baltic and Norwegian and Icelandic waters [6,19-21]. *S. minor* has been reported in harbour porpoises from different geographical localities [6,12,17,20,22,23].

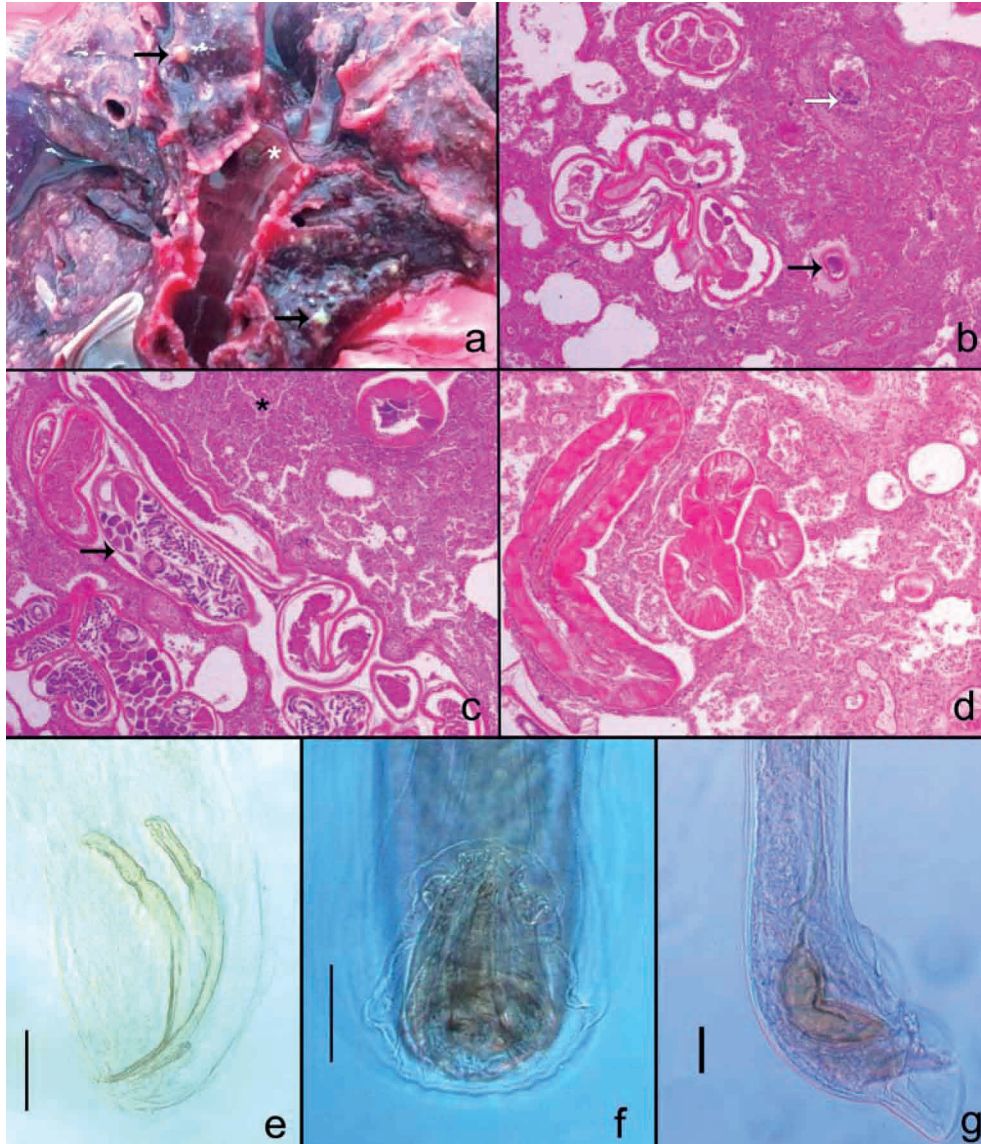


Fig 1. a- Appearance of whitish to grey nodules of parasite (black arrow) in the lung and parasite cluster (asterisk) in the bronchus lumen, b- General appearance of parasite, calcification (black arrow) and basophilic bacteria cluster (white arrow) in the lung, c- Female Metastrongyloid, with developing larvae, within the bronchus lumen (black arrow) and interstitial inflammatory reaction (asterisk), d- Transverse and longitudinal cross section of parasites, e- *H. invaginatus*, caudal end male, lateral view, original, f- *H. taurica*, caudal end male, ventral view, original, g- *S. minor*, caudal end male, lateral view, original. Bar: 50 µm

Şekil 1. a- Akciğerdeki beyazımsı-grimsi parazit nodülleri (siyah ok) ve bronş lümenindeki parazit yığınlarının (yıldız) görünümü, b- Akciğerde parazit, kalsifikasyon (siyah ok) ve basofilik bakteri kümesinin (beyaz ok) genel görünümü, c- Bronş lümenindeki dişi Metastrongyloid, gelişmiş larvalı, (siyah ok) ve interstitial yangı reaksiyonu (yıldız), d- Parazitlerin uzunlamasına ve enine kesitleri, e- *H. invaginatus*, erkek arka uç, lateral görünüm, original, f- *H. taurica*, erkek arka uç, ventral görünüm, original, g- *S. minor*, erkek arka uç, lateral görünüm, original. Bar: 50 µm

S. minor is the first geographic report of from harbour porpoises in Black Sea. However, this species was found from striped dolphins in Turkish Eastern Mediterranean Sea coast [4]. Pulmonary nematodes belonging to the genus *Halocercus* were one of the most prevalent [13]. Three species of *Halocercus* have been reported in harbour porpoises, *H. invaginatus*, *H. taurica* and *H. kirbyi* [15]. *H. invaginatus* has been reported from Dutch waters, Spanish Atlantic coast, German and Norwegian waters [11,20,24]. Veryeri [5] reported *H. invaginatus* from a stranded harbour porpoise from Black Sea. *H. taurica* was previously reported

from the Northwest Atlantic, Northwest Pacific, Black and Azov Seas [16]. Moreover, this is the first geographic report of *H. taurica* from in Turkish coast of the Black Sea. The macroscopic and microscopic changes according to the parasites and the other pneumonia findings of the lungs resembled the results of the studies of dolphin and other marine mammals performed by Parsons et al. [25] and Gonzales-Viera et al. [26]. The bacterial mixed infection case was showed concurrency with previous studies [25,26]. The identification of the parasitic fauna of cetaceans not only contributes to a better understanding of the causes

of stranding and mortality, but also provides valuable information on the biology and ecology of cetaceans [13]. Additionally, parasites could be used as biological tags of marine mammal populations, as indicators of migration and feeding, as a means of separating intraspecific variation of inshore and off-shore populations, as indicators of general state of health, and as an aid in assessing mortality [27]. For this reason, additional data from other cetaceans are required to establish the parasitological information in Turkish waters.

REFERENCES

1. **Dailey MD:** Parasitic diseases. In, Dierauf LA, Gulland FMD (Eds): CRC Handbook of Marine Mammal Medicine. 767-778, CRC Press, Boca Raton, 2001.
2. **Raga JA, Fernández M, Balbuena JA, Aznar J:** Parasites. In, Perrin WF, Würsig B, Thewissen HGM (Eds): Encyclopedia of Marine Mammals. 867-876, Academic Press, San Diego, 2002.
3. **Geraci JH, St Aubin DJ:** Effects of parasites on marine mammals. *Int J Parasitol*, 17, 407-414, 1987.
4. **Aytemiz I, Dede A, Danyer E, Tonay AM:** Morphological identification of parasites found in the stomach contents of by caught striped dolphins (*Stenella coeruleoalba*) from Turkish Eastern Mediterranean Sea coast. *J Black Sea/Medit Environ*, 18, 238-245, 2012.
5. **Veryeri NG:** Postmortem examinations of stranded dolphins found on the Black Sea coast near Ordu, Turkey (Mammalia: Cetacea). *Zool Middle East*, 55, 129-132, 2012.
6. **Siebert U, Wünschmann A, Weiss R, Frank H, Benke H, Frese K:** Post-mortem findings in harbour porpoises (*Phocoena phocoena*) from the German North and Baltic Seas. *J Comp Pathol*, 124, 102-114, 2001.
7. **Baylis HA, Daubney R:** A revision of the lung-worms of Cetacea. *Parasitology*, 17, 201-215, 1925.
8. **Dougherty EC:** The lungworms (Nematoda: Pseudaliidae) of the Odontoceti. Part I. *Parasitology*, 36, 80-94, 1943.
9. **Arnold PW, Gaskin DE:** Lungworms (Metastrongyloidea: Pseudaliidae) of harbor porpoises *Phocoena phocoena* (L., 1758). *Can J Zool*, 53, 713-735, 1975.
10. **Dailey M, Stroud R:** Parasites and associated pathology observed in cetaceans stranded along the Oregon coast. *J Wildl Dis*, 14, 503-511, 1978.
11. **Abollo E, Lopez A, Gestal C, Benavente P, Pascual S:** Macroparasites in cetaceans stranded on the northwestern Spanish Atlantic coast. *Dis Aquat Org*, 32, 227-231, 1998.
12. **Gibson DI, Harris EA, Bray RA, Jepson PD, Kuiken T, Baker JR, Simpson VR:** A survey of the helminth parasites of cetaceans stranded on the coast of England and Wales during the period 1990-1994. *J Zool*, 244, 563-574, 1998.
13. **Garvalho VL, Bevilaqua CM, Iñiguez AM, Mathews-Cascon H, Ribeiro FB, Pessoa LM, de Meirelles AC, Borges JC, Marigo J, Soares L, de Lima Silva FJ:** Metazoan parasites of cetaceans off the northeastern coast of Brazil. *Vet Parasitol*, 173, 116-122, 2010.
14. **Oliveira JB, Morales JA, González-Barrientos RC, Hernández-Gamboa J, Hernández-Mora G:** Parasites of cetaceans stranded on the Pacific coast of Costa Rica. *Vet Parasitol*, 182, 319-328, 2011.
15. **Pekmezci GZ, Onuk EE, Yardımcı B, Bölükbaş CS, Gürler AT, Açıcı M, Umur Ş:** Ülkemiz karasularında yakalanan ve Samsun'da tüketime sunulan bazı deniz balıklarında zoonoz *Anisakis* türlerinin moleküler karakterizasyonu. Ondokuz Mayıs Üniversitesi, Veteriner Fakültesi, Proje No: OMU PYO 1901.12.013, 2012.
16. **Measures LN:** Lungworms of marine mammals. In, Samuel WM, Pybus MJ, Kocan AA (Eds): Parasitic Diseases of Wild Mammals. 279-300, Iowa State University Press, 2001.
17. **Baker JR, Martin AR:** Causes of mortality and parasites and intestinal lesions in harbour porpoises (*Phocoena phocoena*) from British waters. *Vet Rec*, 130, 554-558, 1992.
18. **McClelland G:** Nematoda (roundworms). In, Rohde K (Ed): Marine Parasitology. 104-115, CABI Publishing, Wallingford, 2005.
19. **Rokicki J, Berland B, Wroblewski J:** Helminths of the harbour porpoise, *Phocoena phocoena* (L.), in the southern Baltic. *Acta Parasitol*, 42, 36-39, 1997.
20. **Lehnert K, Raga JA, Siebert U:** Macroparasites in stranded and by caught harbour porpoises from German and Norwegian waters. *Dis Aquat Org*, 64, 265-269, 2005.
21. **Siebert U, Tolley K, Vikingsson GA, Ólafsdóttir D, Lehnert K, Weiss R, Baumgärtner W:** Pathological findings in harbour porpoises (*Phocoena phocoena*) from Norwegian and Icelandic waters. *J Comp Pathol*, 134, 134-142, 2006.
22. **Faulkner J, Measures L, Whoriskey FG:** *Stenurus minor* (Metastrongyloidea: Pseudaliidae) infections of the cranial sinuses of the harbour porpoise, *Phocoena phocoena*. *Can J Zool*, 76, 1209-1216, 1998.
23. **Jauniaux T, Petitjean D, Brenez C, Borrens M, Brosens L, Haelters J, Tavernier T, Coignoul F:** Post-mortem findings and causes of death of harbour porpoises (*Phocoena phocoena*) stranded from 1990 to 2000 along the coastlines of Belgium and Northern France. *J Comp Pathol*, 126, 243-253, 2002.
24. **Slob CM, Hendrikx WML, Borgsteede FHM, García Hartmann M:** Lung worms in harbour porpoises (*Phocoena phocoena*) from Dutch waters. In, García Hartmann M (Ed): Proceedings of the Third ECS Workshop on Cetacean Pathology: Lung Pathology, (special issue). 35-40, Lissabon, Portugal, 1996.
25. **Parsons ECM, Jefferson TA:** Post-mortem investigations on stranded dolphins and porpoises from Hong Kong waters. *J Wildl Dis*, 36, 342-356, 2000.
26. **Gonzales-Viera O, Chavera A, Yaipén-Llanos C, Perales-Camacfo R:** Histopathological aspects and etiology of pneumonias in stranded marine mammals from Lima-Peru. *Braz J Vet Pathol*, 4, 23-29, 2007.
27. **Dailey MD:** Parasites as an aid to understanding marine mammal populations. In, Geraci JR, St Aubin DJ (Eds): Biology of Marine Mammals: Insights through Stranding. 243-244, Springfield, Virginia, 1979.