

Examination of Equine Udder and Teat by B-Mode Ultrasonography

Örsan GÜNGÖR*

Şükrü Metin PANCARCI*

Ali KARABACAK**

* University of Kafkas, Veterinary Faculty, Department of Obstetrics and Gynaecology, 36040, Kars - TURKEY

** Military Veterinary School and Central Commandership, Gemlik, Bursa - TURKEY

Yayın Kodu: 2005/27-A

Summary

Eighteen multiparous mares with 36 mammary lobes and 36 teats were used. All of the mares were lactating at various stages during ultrasound examinations. Ultrasonographic examinations of the mammary gland and teat were performed by using a portable, B-mode, real time ultrasound scanner equipped with 5 and 7.5 MHz linear array probes either directly touching the mammary skin or using a water bath. During the examinations, the ultrasound probe was moved vertically and horizontally. The wall of the teat consists of three distinct layers. The teat sinus filled with milk was monitored as anechoic images. Ultrasound examinations revealed that septum, which divides teat sinus, elongates as a hyperechoic line. Furthermore, the papillary duct was monitored as an anechoic image. Furstenberg's rosette was determined as an hyperechoic line. Also, the ostium papillare was found as anechoic, thin lines among hyperechoic lines. Ultrasonographic examinations of the mammary lobes revealed the parenchyma of the mammary gland as homogeneous and hyperechoic image. Moreover, ductus lactiferouses and sinus lactiferouses were observed anechoic in hyperechoic mammary parenchyma.

Keywords: Mare, udder, teat, ultrasound.

Kısıraklarda Memenin ve Meme Başının B-Mode Ultrasonografi ile Muayenesi

Özet

Araştırmada 18 kısırağa ait 36 meme sarnıcı ve 36 meme başı kullanıldı. Ultrasonografik muayeneler yapıldığında kısırakların tümü laktasyonun farklı evrelerindeydi. Memelerin muayenesi 5 ve 7.5 MHz frekanslı prob ile çalışan B-mode real time linear array taşınabilir ultrasonografi cihazı ile, prob direkt memeye temas ettirilerek ya da meme su banyosu içinde iken yapıldı. Muayene sırasında prob vertikal ve horizontal olarak uygulandı. Meme başının, vertikal olarak yapılan muayenesinde, meme başı duvarının üç farklı tabakaya sahip olduğu belirlendi. İçi sütle dolu olan sinus papillarisler ise anekojen olarak saptandı. Sinus papillaris'i ikiye ayıran septum hiperekojen bir şerit tarzında, ductus papillarisler ise anekojen olarak belirlendi. Fürstenberg rozeti ductus papillaris ve sinus papillaris arasında hiperekojen bir katman olarak, ostium papillareler ise hiperekojen katmanlar arasında anekojen ince çizgiler halinde görüldü. Meme lobunun ultrasonografik muayenesinde, meme parenşimi homojen hiperekojenik görüntüler verdi. Ductus lactiferuslar ve sinus lactiferuslar hiperekojen meme parenşiminin içinde anekojen olarak saptandı.

Anahtar sözcükler: Kısırak, meme, meme başı, ultrason

İletişim (Correspondence)

Dr. Örsan GÜNGÖR

Tel: +90 474 2426800 - 1236

e-mail: gungorrsan@hotmail.com

INTRODUCTION

Ultrasonographic examinations have been very important diagnostic tool for recent years in veterinary practice^{1,2}. Veterinary ultrasonography has gained significant value in the gynaecological examination of mares³. Ultrasonography has been used to monitor and diagnose ovarian functions, pregnancy, postpartum uterine involutions, ovarian and uterine malformations in equine reproduction^{2,4,5}. At first, Caruola and Mochiere⁶, used A mode ultrasonography equipped with 1 MHz probe for examination of mammary glands in lactating cows. Afterwards, Cartee et. al.⁷ reported applicability of the B mode real time ultrasonography for the diagnosis of dysfunction regarding milk flow and teat abnormalities. Plenty of researches have been done for detailed ultrasonographic examination of mammary lobes and teat in cow, sheep, dog and sow⁸⁻¹⁰. However, few researches¹¹ have been performed for ultrasonographic examination of mammary gland in mares.

Recently, researchers^{7,9,10,12} have reported that ultrasonography is routinely used for diagnosis of mammary teat dysfunctions in addition to classical examination methods. As long as appropriate equipment is used, morphological abnormalities in mammary gland parenchyma, cisterns of mammary gland and teat, papillary duct can be diagnosed in cow, sheep and goat. The udder of the mare is located ventrally on the abdomen between the two hind legs¹³. The udder comprises right and left mammary glands each surmounted by a teat. Each gland accommodates two (sometimes three) duct systems which channel the milk through increasingly larger ductus lactiferous into a lactiferous and in the teat sinus. Two papillary ducts ending at the teat orifices convey the milk to the outside (Fig. 1)¹⁴.

The purposes of this study are to describe the structure of mammary gland and teat by ultrasonography in mares.

MATERIAL and METHODS

In this study, 18 multiparous mares with 36 mammary lobes and 36 teats were used in Horse Production and Training Battalion in Military Veterinary School and Central Commandership, in Gemlik, Bursa, Turkey in spring 2003. All of the mares were lactating at

various stages during ultrasonographic examinations. At least two hours prior to ultrasound examinations, foals were isolated from their dams. Following the handling of mares in clinic; their mammary skin was cleaned with antiseptic solutions (Dezen, Vetaş, Turkey). Ultrasonographic examinations of mammary gland and teat were performed by using a portable B-mode real time ultrasound scanner (Scanner 200, Pie Medical) equipped with 5 and 7.5 MHz linear array transducers directly touching to the mammary skin or in a warm water bath. At direct examinations of mammary gland and teat, special gel (Konix, Turkuaz Medical, Turkey) was spread on the transducer to achieve better contact between skin and probe by eliminating presence of air between these sites. At examinations in water bath, plastic cups, with various sizes, filled with warm water were used. The transducer was placed in contact with the plastic. During examinations, ultrasound probe was moved vertically and horizontally. At first, mammary teat was examined; afterwards, orifice of teat, papillary duct, Furstenberg's rosette, teat sinus, septum of teat sinus were monitored respectively. Following the examination of mammary teat, mammary lobes were examined. In this regard, mammary parenchyma, sinus lactiferous and ductus lactiferous were monitored. Moreover, any pathological changes were investigated in these mammary sections. All images obtained at examinations were printed by black-white printer (p90, Mitsubishi).

RESULTS

Vertical ultrasonographic examination of teat indicated that wall of teat consists of three distinct layers as follows; thin hyperechoic inner layer (mucous membrane), homogeneous and thick median layer with moderately echogenicity (muscle layer), and with bright echogenity outer layer (skin/epidermis) respectively (Fig. 2). In contrast, teat sinus filled with milk was monitored as anechoic images (Fig. 2). Moreover, ultrasound examination revealed that septum, which divides teat sinus, elongates as a hypoechoic line until teat end i.e., ostium papillare. Furthermore, papillary duct was monitored at the right and left sides of line dividing teat sinus as an anechoic image (Fig. 3). Furstenberg's rosette was determined as a moderately echogenic line between papillary duct and teat sinus. Also ostium papillare was found as anechoic thin lines among hyperechoic lines (Fig. 3).

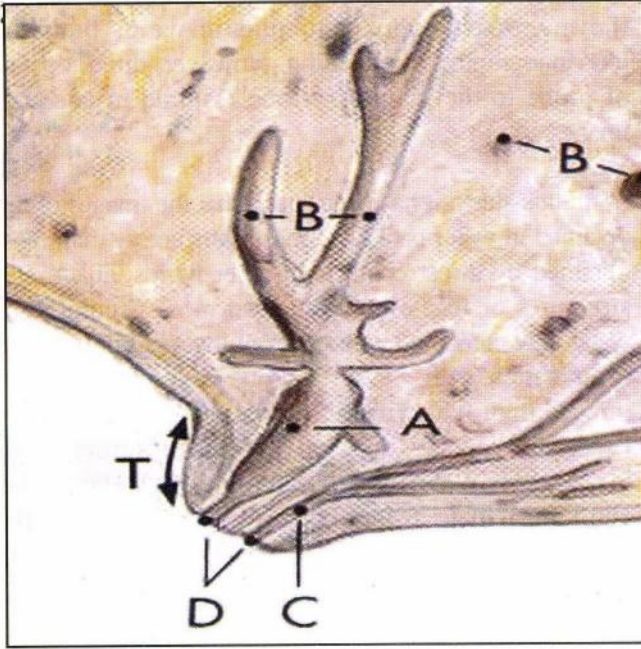


Figure 1. Udder, sagittal section through a teat¹⁴.

T: Teat, A: sinus lactiferous, B: ductus lactiferous, C: papillary duct, D: ostium papillare

Şekil 1. Meme ve meme başının sagittal kesiti¹⁴.

T: Meme başı, A: Ductus lactiferus, C: Meme başı kanalı, D: Meme başı deliği.

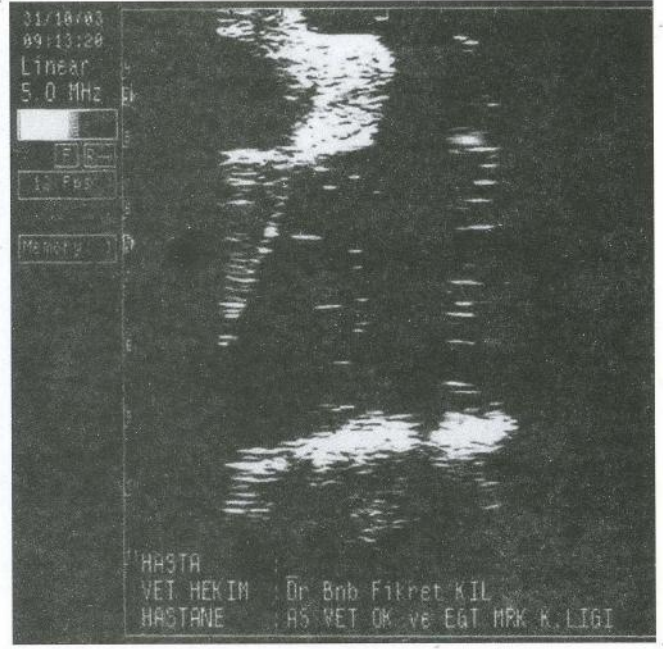


Figure 3. A vertical view of mammary teat orifice in water bath (with 5 MHz probe). op: ostium papillare

Şekil 3. Meme başının su banyosundaki vertikal görüntüsü (5 MHz probe). op: meme başı deliği

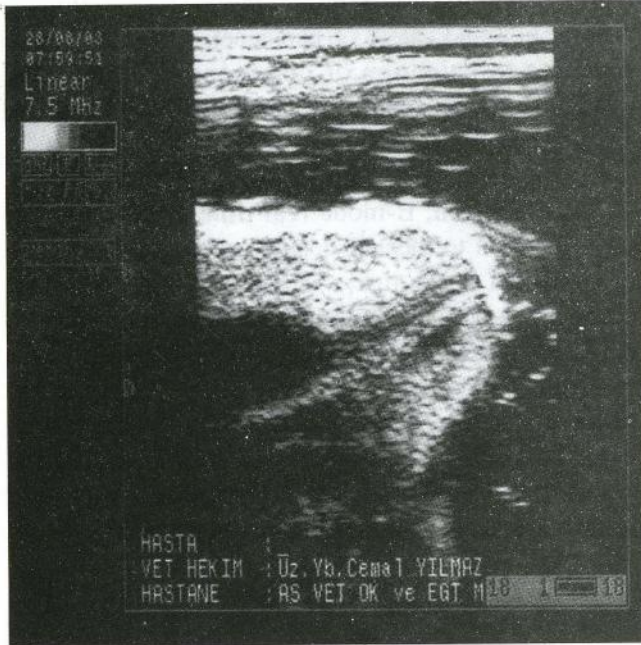


Figure 2. A vertical view of mammary teat in water bath (with 7.5 MHz probe). ts: teat sinus, pd: papillary duct, Fr: Furstenberg's rosette, ol: outer layer (epidermis), ml: midlayer (muscle layer), il: inner layer (mucous membrane), s: septum dividing mammary teat sinus.

Şekil 2. Meme başının su banyosunda vertikal görüntüsü (7.5 MHz probe). ts: meme başı sistemasi, pd: meme başı kanalı, Fr: Furstenberg rozeti, ol: epidermis, ml: kas katı, il: mukoz membran s: meme başı sistemasi ikiye bölen duvar.

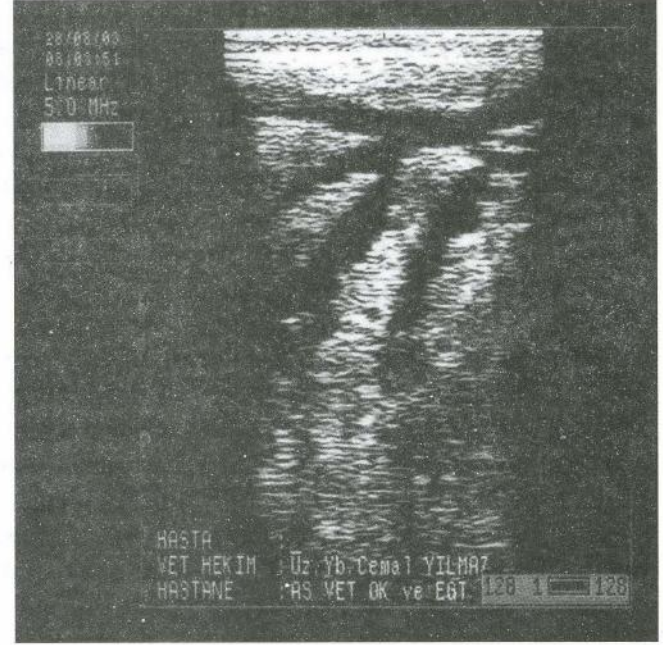


Figure 4. A horizontal view of mammary lobe obtained with direct contact (with 5 MHz probe). gp: parenchyma of mammary gland, dl: ductus lactiferous

Şekil 4. Probu meme lobuna direkt teması ile elde edilen horizontal görüntü (5 MHz probe). gp: meme parenşimi, dl: ductus lactiferus

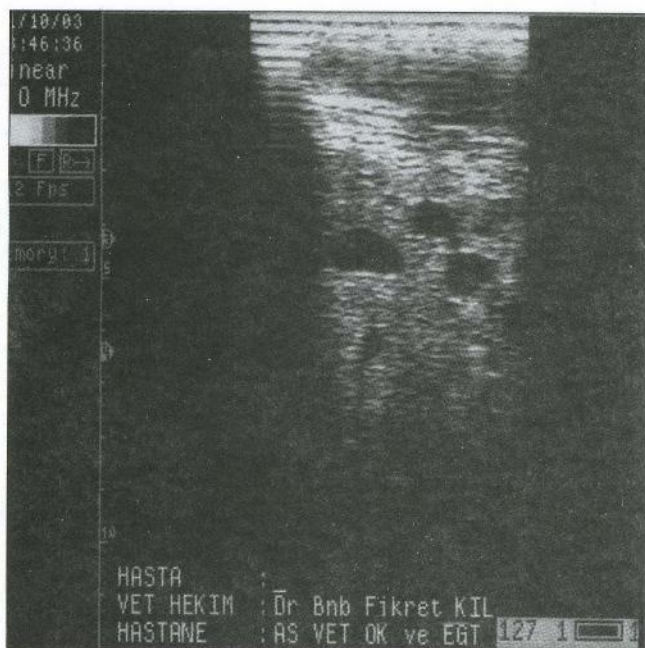


Figure 5. A vertical view of sinus lactiferous with direct contact (with 5 MHz probe). sl: sinus lactiferous

Şekil 5. Sinus lactiferusların, pobun meme lobuna direkt teması ile elde edilen vertikal görüntüsü (5 MHz probe). sl: sinus lactiferus

Ultrasonographic examination of mammary lobes revealed parenchyma of mammary gland as homogeneous and hyperechoic image. Moreover, ductus lactiferous were observed as elongating anechoic branches in hyperechoic mammary parenchyma (Fig. 4). Ductus lactiferous monitored as anechoic images elongated to sinus lactiferous with rounder and bigger anechoic images (Fig. 5).

DISCUSSION

While Seeh et al¹⁵ reported that direct contact of 3.5 and 5.0 MHz probe to teat could reveal images with adequate quality, Stocker et. al.¹⁶, Will et al¹⁷, and Saratis and Grunert¹⁸ declared that ultrasonographic examination of the teats in a water bath resulted in better images. Moreover, it has been indicated that better images were obtained when teat was filled with milk or neutral solutions^{9,15}. Sendag and Dinc⁹ reported that structures within the mammary gland sinus could be monitored by ultrasonography in lactating cows because milk is placed at fluid-solid interphase. Thus, it has been thought that use of lactating mares gave an advantage to this study. Since foals were restricted from suckling for at least two hours before the ultrasonographic examination, the mammary teat sinuses and mammary lobes were filled with milk. This sometimes caused a difficulty to handle

the mammary lobes into plastic water beds for ultrasonographic examination. However, direct contact of probe to the mammary lobe resulted in adequate images.

In this study, it has been found that the images of teat obtained in water bath were more satisfactory than those obtained by direct contact. In other words, anatomical structures of teat were monitored more accurately in water bath compared to direct examination. Furthermore, examination with 7.5 MHz probe gave more detailed images than that with 5.0 MHz probe in this study. Especially, papillary duct and Furstenberg's rosette were more clearly defined by using 7.5 MHz probe. Ultrasonographic images obtained by 5.0 and 7.5 MHz probes were accepted as being equal for examination of the mammary lobe.

Plastic materials used for warm water bath should be smooth for better contact and permeable for ultrasound waves. The upper sides of these plastic materials should be smooth for full coverage of mammary region without causing any irritation.

It should be kept in mind that proper handling of mares has a vital importance for ease of mammary examination and safety of personnel. Especially, mares sensitive to palpation of udder and teat should be examined carefully and should be calmed by giving sedative drugs if needed.

In conclusion, B-mode real time ultrasonography could be used to identify detailed anatomical structures of udder and teat in mares. The use of ultrasonographic examination of equine udder and teat could facilitate the diagnosis of any abnormalities, and it warrants further research. Examination of teat in water bath provided better results than examination via direct contact of probe to teat. In contrast, direct examination of mammary lobe is recommended due to satisfactory images with direct technique and difficulties in the examination in water bed.

REFERENCES

1. Adams GP, Kastelic JP, Bergfelt DR, Ginther OJ: Effect of uterine inflammation and ultrasonically-detected uterine pathology on fertility in the mare. *J Reprod Fertil Suppl*, 35: 445-454, 1987.
2. Alaçam E: Pregnancy detection. In, Alaçam E (Ed): Reproduction, Artificial Insemination, Parturition and Infertility in Domestic Animals. (In Turkish: Evcil Hayvanlarda Reprodüksiyonun Sun'ı Tohumlama Doğum ve İnfertilite). 1st ed.. Dizgievi, Konya, 127-138, 1994.

- 3 **Kahn W, Volkmann D, Kenney R:** Ultrasonography in the mare. In, Kahn W (Ed): Veterinary Reproductive Ultrasonography. Schlütersche Verlagsanstalt und Druckerei GmbH & Co., Hannover. pp 11-8, 1994.
- 4 **Allen WE, Arbeid PE, Kooros K, Pycock JF:** Ultrasonic appearance of the equine corpus haemorrhagicum. *Vet Rec*, 121: 422-423, 1987.
- 5 **Ginther OJ, Pierson RA:** Ultrasonic anatomy of equine ovaries. *Theriogenology*, 21: 471-483, 1984.
- 6 **Caruolo EV, Mochiere RD:** Ultrasonograms of lactating mammary glands. *J Dairy Sci*, 50:225-230, 1967.
- 7 **Cartee RE, Ibrahim AK, Mcleary D:** B-mode ultrasonography of the bovine udder and teat. *J Am Vet Med Assoc*, 188: 1284-1287, 1986.
- 8 **Ruberte J, Carretero A, Fernandez M, Navarro M, Caja G, Kirchner F, Such X:** Ultrasound mammography in the lactating ewe and its correspondence to anatomical section. *Small Rum Res*, 13: 199-204, 1994.
- 9 **Şendağ S, Dinç DA:** Ultrasonography of the bovine udder. (In Turkish:İneklerde Memenin Ultrasonografisi). *Turk J Vet Anim Sci*, 23: 545-552, 1999.
- 10 **Franz S, Hofmann-Parisot M, Baumgartner W, Windischbauer G, Suchy A, Bauder B:** Ultrasonography of the teat canal in cows and sheep. *Vet Rec*, 149:109-112, 2001.
- 11 **Waldrige BM, Ward TA:** Ultrasound examination of the equine mammary gland. *Equine Pract*, 21:12-13,1999.
- 12 **Bruckmaier RW, Blum JW:** B-mode ultrasonography of mammary glands of cows, goats, and sheep during alpha- and beta-adrenergic agonist and oxytocin administration. *J Dairy Sci*, 59: 151-159,1992.
- 13 **Easley J:** Mammary Gland Surgery. In, McKinnon AO, Voss JL (Ed), Williams & Wilkins Equine Reproduction, Rose Tree Corporate Center USA, pp:461-463, 1993.
- 14 **Budras K, Sack WO, Röck S, Wünsche A, Henschel E:** Anatomy of the Horse. 3rd ed. Schlütersche GmbH & Co. Hannover, Germany, 2001.
- 15 **Seeh C, Hospes R, Bostedt H:** Use of visual methods (sonography/endoscopy) for the diagnosis of a webbed teat in cattle. *Tierarztl Prax*, 24: 438-442, 1996.
- 16 **Stocker H, Battig U, Duss M, Zahner M, Flückinger M, Eicher R, Rüsç P:** Die abklärung von zitzenstenosen beim Rind mittels Ultraschall. *Tierarztl Prax*, 17: 251-256, 1989.
- 17 **Will S, Würgau ST, Fraunholz J, Bouabid C, Leidi W:** Sonographische Befunde an der papilla mammae des Rindes. *Dtsh Tierarztl Wschr*, 97: 403-406, 1990.
- 18 **Saratis P, Grunert E:** Ultraschalluntersuchungen zur Abgrenzung der räumlichen Ausdehnung von Zitzenstenosen und anderen Zitzen beränderungen beim Rind. *Dtsh Tierarztl Wschr*, 100: 159-163, 1993.