


Auricular Abscessation in Red-Eared Sliders (*Trachemys scripta elegans*)

Banu YARDIMCI *  Cenk YARDIMCI ** Kerem URAL *** Sertel SEÇER ****

* Ondokuz Mayıs University, Faculty of Veterinary Medicine, Department of Diseases of Aquatic Animals, TR-55139 Samsun - TURKEY

** Ondokuz Mayıs University, Faculty of Veterinary Medicine, Department of Surgery, TR-55139 Samsun-TURKEY

*** Adnan Menderes University, Faculty of Veterinary Medicine, Department of Internal Medicine, TR-09010 Aydın-TURKEY

**** Ankara University, Faculty of Agriculture, Department of Fisheries and Aquaculture, TR-06110 Ankara- TURKEY

Makale Kodu (Article Code): KVFD-2009-1076

Summary

Four red-eared sliders (*Trachemys scripta elegans*) at the age of 2 to 5 years old were presented with histories of abscess formation at the base of the auricular area becoming larger over time. *Pasteurella testudinis* was diagnosed on microbiological examination of the abscessed material in all cases. Treatment included surgical intervention confined to surgical debridement and removal of abscess contents. Enrofloxacin was administered in all operated cases. As a result, lesions resolved with surgical treatment, coinciding with regression of the infection.

Keywords: Auricular abscessation, Red-eared sliders, *Pasteurella testudinis*

Kırmızı Yanaklı Su Kaplumbağalarında (*Trachemys scripta elegans*) Kulak Apsesi

Özet

Yaşları 2 ila 5 arasında değişen 4 adet kırmızı yanaklı su kaplumbağası (*Trachemys scripta elegans*) kulak kaidesinde bulunan ve zamanla büyüme gösteren apse hikayesi ile sunuldu. Tüm olgularda, apse içeriğinden alınan örneklerin mikrobiyolojik muayenesinde *Pasteurella testudinis* izole edildi. Cerrahi olarak apse içeriğinin uzaklaştırılması ve debridemanı yapıldı. Operasyon uygulanan tüm olgularda enrofloksasin uygulandı. Sonuç olarak, uygulanan müdahale ile lezyonlarda tam bir iyileşme sağlandı.

Anahtar sözcükler: Kırmızı yanaklı su kaplumbağası, Kulak apsesi, *Pasteurella testudinis*

INTRODUCTION

Aural abscessation, swelling due to pus in the tympanic cavity or middle ear, was recently reported to be cause of morbidity and mortality in free-living Eastern box turtles (*Terrapene carolina carolina*)¹. Mucin-secreting epithelium lining the upper respiratory tract and middle ear of free-living box turtles with aural abscess exhibit varying degrees of pathologic changes, including squamous metaplasia, hyperkeratinization, mucosal hyperplasia, inflammation, and mucosal erosion^{2,3}.


The objectives of the present case report were to


describe the treatment, gross and histopathological changes of the four red-eared slider (*Trachemys scripta elegans*) with aural abscess, and to discuss the relationship of the lesions to the proposed and bacteriologically verified etiological agent.

CASES HISTORIES

Four red-eared slider (*Trachemys scripta elegans*) had aural abscessation (three unilateral (*Fig. 1a*) and

 İletişim (Correspondence)

 +90 362 3121919/3903

 byardimci@omu.edu.tr

one bilateral). The ages of the cases were 2, 4, 3 and 5 years respectively. All of them were female and living in a semi-aquatic hobby aquarium with their male mates. The clinical diagnoses were made on the basis of physical examination with microbiological isolation and identification. All were anesthetized with intramuscularly injection of 20 mg/kg ketamine HCl (Alfamine 10%, Egevət, İzmir, Turkey) . A 4-5 mm long linear skin incision was performed to the peak point of the swelling. After removal of the pus, the pouch was lavaged with sterile saline and the incision line was sutured. In order to eliminate the infection enrofloxacin (Baytril-K 5%, Germany) was administered at the dose of 10 mg/kg/72 h for 4 times by intramuscular route. None of the cases showed recurrence after the treatment.

Cultures of specimens from which *P. testudinis* was recovered, were inoculated onto 5% bovine blood agar and then incubated at 37°C under 95% air - within 5% CO₂. *Pasteurella testudinis* was identified as gram-negative pleomorphic rods on the basis of hemolytic activity developed at beef blood agar, indole production in tryptose broth, positive oxidase reaction, and lack of motility .

The allocation of the abscesses were unilateral in three and bilateral in one case. Consistencies of the abscess contents were fluctuant in three and caseified in one, bilateral case (Fig. 1b). That bilateral case was brought immediately after death for necropsy examination so that this case did not evaluated in the treatment group. But, because the clinical outlook wholly resembled to the study cases, postmortem

macroscopic and microscopic evaluation was performed in order to shed light on the study.

Macroscopically, at the cut surface of the 5 mm diametered, firm, bulged swelling; caseified, yellowish coloured, chronic abscess formation surrounded with fibrous capsula was observed.

At the microscopic examination, some of the stratum spinosum cells were seen to be swelled and rounded, with their cytoplasm show a granular outlook whilst some of which contained cytoplasmic vacuol formations. Also significant thickening in the keratin layer was observed. In dermis; distinct hyperemia, lymphocyte infiltration accompanied by heterophils and micro-hemorrhagic foci were seen (Fig. 1 c,d).

DISCUSSION

The effects and the role of those bacteria on free-ranging green turtle populations are not very well recognized. The presence of potential pathogenic bacteria in free-living turtle tissues everytime does not show illness and should be evaluated with regard to the various stressor conditions. During mating behaviour, the superficial tissues of female turtles may be injured by male bites and claws. Especially skin lesions and sea water aspiration are the most common routes for the entrance of microorganisms in sea turtles ^{4,5}. Therefore the microorganism found in this study may be considered to be an opportunistic pathogen. It is also possible that concomitant diseases and/or environment-associated,

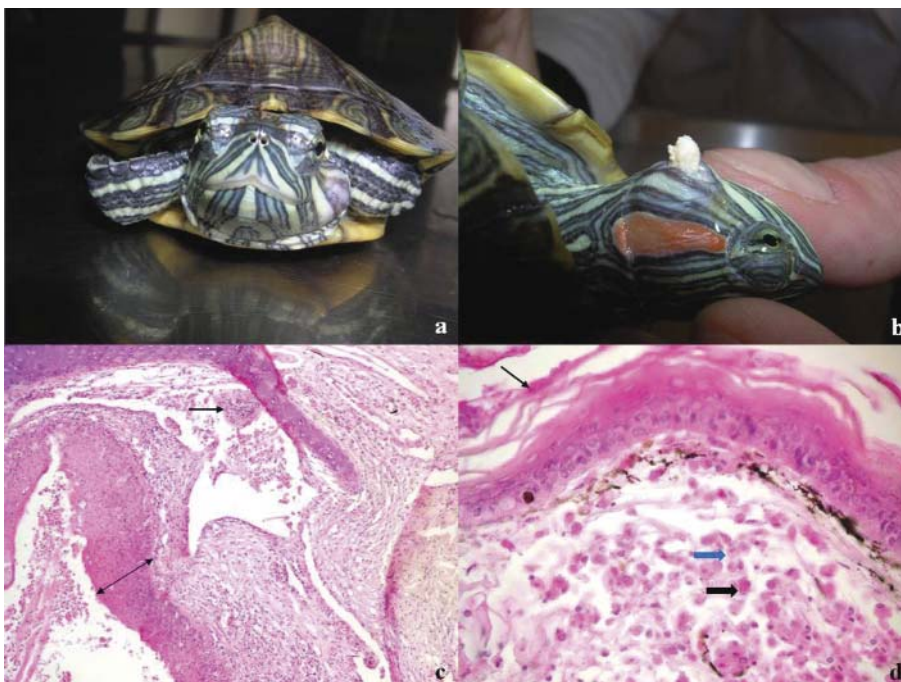


Fig 1. a. Clinical outlook of unilateral auricular abscessation (case no:1), b. Caseified abscess content (case no: 4), c. Hyperplasia at epidermis (double-headed arrow) and focal lymphocyte infiltration at dermis, HE x100, d. Hyperkeratinization at epidermis (thin black arrow), heterophil infiltration (thick black arrow) and micro haemorrhage at dermis (thick blue arrow), HE x400

Şekil 1. a. Unilateral kulak apsesinin klinik görünümü (olgu no:1), b. Kazeifiye apse içeriği (olgu no: 4), c. Epidermiste hiperplazi (iki yönlü ok) ve dermiste fokal lenfosit infiltrasyonu, HE x100, d. Epidermiste hiperkeratinizasyon (ince siyah ok) ile dermiste heterofil infiltrasyonu (kalın siyah ok) ve mikro hemoraji (kalın mavi ok), HE x400

reproductive, hormonal or other stressors, may affect the immune system and result in abscess formation. Disrupted vitamin A metabolism, poor water quality and/or contaminated water are emphasized as to be predisposing factors for the formation of aural abscesses ^{3,6}.

In a retrospective study carried out in Wild Life Center of Virginia between 1991-2000, 50 of 694 reptiles were (7%) examined for aural abscessation ¹.

In this study, *P. testudinis* was the common micro-organism. In most of the reptiles, the latter microbe has been considered a resident flora, where as it has also been associated with ulcerative stomatitis, abscess, hypopyon, necrotizing dermatitis, and pneumonia in turtles and reptiles ⁷⁻¹⁰.

According to the latter authors discussed the assessment of *P. testudinis* as a similarly commensal agent with at most opportunistic pathogenic potential. However it should be mentioned that the presence of *P. testudinis* in turtle abscesses does not always indicate to a specific pathogenic role of this agent in this condition, as it may be a common commensal. Sparsely abscess due to *P. testudinis* of turtles and tortoises was previously reported. Therefore in the authors experience *P. testudinis* may play a more specific role in abscess formation of turtles ¹¹.

In present study, death was thought to be occurred due to septicemia originating from chronic abscess at the auricular area with inflammatory changes and progressive hyperemia of liver and intestines.

During the last decade there has been a significant increase in the number of red-eared slider (*Trachemys scripta elegans*) as a pet in Turkey. Therefore the present authors interest to the diseases of those turtles was aroused following recognizing the present cases. Further studies with larger turtle populations with abscess formation may be valuable in order to establish the nature and pathology of those diseases in Turkey.

REFERENCES

- Brown JD, Sleeman JM:** Morbidity and mortality of reptiles admitted to the wildlife center of Virginia, 1991 to 2000. *J Wildl Dis*, 38, 699-705, 2002.
- Brown JD, Richards JM, Robertson J, Holladay S, Sleeman JM:** Pathology of aural abscess in free-living eastern box turtles (*Terrapene carolina carolina*). *J Wildl Dis*, 40, 704-712, 2004.
- Holladay SD, Wolf JC, Smith SA, Jones DE, Robertson JL:** Aural abscesses in wild-caught box turtles (*Terrapene carolina*): Possible role of organochlorine-induced hypovitaminosis A. *Ecotoxicol Environ Saf*, 48, 99-106, 2001.
- George RH:** Health problems and diseases of sea turtles. In, Lutz PL, Musick PL (Eds): *The Biology of Sea Turtles*. 363-368, CRC Press, Washington, 1997.
- Oros J, Torrent A, Calabuig P, Deniz S:** Diseases and causes of mortality among sea turtles stranded in the Canary Islands, Spain (1998-2001). *Dis Aquat Organ*, 63, 13-24, 2005.
- Brown JD, Sleeman JM, Elvinger F:** Epidemiologic determinants of aural abscessation in free living eastern box turtles (*Terrapene carolina*) in Virginia. *J Wildl Dis*, 39, 918-921, 2003.
- Aguirre AA, Balazs GH, Zimmerman B, Spraker TR:** Evaluation of Hawaiian green turtles (*Chelonia mydas*) for potential pathogens associated with fibropapillomas. *J Wildl Dis*, 30, 8-15, 1994.
- Bonney CH, Hartfield DA, Schmidt RE:** Klebsiella pneumoniae infection with secondary hypopyon in Tokay gecko lizards. *JAVMA*, 173, 1115-1116, 1978.
- Glazebrook JS, Campbell RSF:** A survey of the diseases of marine turtles in northern Australia. I. Farmed turtles. *Dis Aquat Organ*, 9, 83-95, 1990.
- Glazebrook JS, Campbell RSF, Thomas AT:** Studies on an ulcerative stomatitis-obstructive rhinitis-pneumonia disease complex in hatchling and juvenile sea turtles, *Chelonia mydas* and *Caretta caretta*. *Dis Aquat Organ*, 16, 133-147, 1993.
- Jang SS, Biberstein EL:** Observations on the occurrence of *Pasteurella testudinis* in clinical specimens from animals. *J Vet Diagn Invest*, 3, 176-179, 1991.