

# The Advantages of Autologous Adipose Derived Mesenchymal Stem Cells (AdMSCs) over the Non-steroidal Anti-inflammatory Drugs (NSAIDs) Application for Degenerative Elbow Joint Disease Treatment in Dogs - Twelve Cases

Jakub NICPOŃ<sup>1</sup>  
Agnieszka ŚMIESZEK<sup>2</sup>

Krzysztof MARYCZ<sup>2</sup>  
Nezir Yaşar TOKER<sup>3</sup>

Jakub GRZESIAK<sup>2</sup>

- <sup>1</sup> Wrocław University of Environmental and Life Sciences, Department and Clinic of Veterinary Surgery, 51 Grunwaldzki Square, 50-366 Wrocław - POLAND  
<sup>2</sup> Wrocław University of Environmental and Life Sciences, Electron Microscope Laboratory, Kożuchowska 5b, 51-631, Wrocław - POLAND  
<sup>3</sup> İstanbul Üniversitesi, Veteriner Fakültesi, Biyokimya Anabilim Dalı, TR-34320 Avcılar, İstanbul - TÜRKİYE

Makale Kodu (Article Code): KVFD-2013-10105

## Summary

In the present study based on clinical case reports, twelve dogs (7 males, 5 females) between the ages of 5 and 11 years old, with clinically diagnosed osteoarthritis of the elbow joint were undertaken for comparison of the therapeutic effect derived from the standard non-steroidal antiinflammatory drug (NSAIDs) treatment with novel, autologous adipose-derived mesenchymal stem cell (AdMSCs) application. Animals were not under any treatment for 3 last months before the diagnosis. Individuals from experimental group were treated with autologous adipose-derived mesenchymal stem cells, while individuals from control group received Mavacoxib (Trocoxil). After 0, 60, 90 and 180 days of the treatment, all individuals were clinically evaluated. Additionally, examination of synovial fluid from all of the animals was performed after 0, 60, 90 and 180 days. The CT analysis were performed at day 0 and 180 days after the treatment. The AdMSCs therapy in the case of elbow joint degeneration (OA) decreased the discomfort and reduced accompanying clinical symptoms like pain, stiffness when walking and lameness. In contrast, though the animals from control group showed the improvement during first period of experiment, the OA symptoms reoccurred 90 days after the application of NSAIDs. This work is the first report that not only describes the picture of clinical examination, but is also based on synovial fluid analysis and CT evaluation. The injections of autologous stem cells did not exhibit any adverse reactions, which confirms the safety of this method. Our research confirmed the efficiency of AdMSC injections for the treatment of elbow joint osteoarthritis in dogs, which improve the clinical picture and the patients' condition, however without the regresses of osteofites.

**Keywords:** Adipose-derived mesenchymal stem cells, Canine, Elbow joint diseases, Osteoarthritis

## Köpeklerde Dejeneratif Dirsek Eklemi Bozukluğu Tedavisinde Non-steroidal Antiinflatuar Ajan (NSAIA) Uygulanmasından Sonra Adipoz Doku Kökenli Otolog Mezenkimal Kök Hücrelerin (ADKOMKH) Faydası - Oniki Olgu

### Özet

Bu çalışma klinik olarak dirsek ekleminde osteoarthritis tespit edilen, standart non-steroidal anti inflammatuar ilaçlardan (NSAIA) türetilmiş terapötik ilaçla tedavi edilen 5-11 yaş arasında, oniki (7 erkek, 5 dişi) köpekte, adipoz doku orijinli otolog mezenkimal kök hücrelerin (ADKOMKH) etkinliğini karşılaştırmak için yapılmıştır. Teşhisten önce hayvanlara 3 ay boyunca herhangi bir uygulama yapılmamıştır. Deneysel gruptaki bireyler adipoz kökenli otolog mezenkimal kök hücrelerle tedavi edildi, buna karşın kontrol grubun bireylerine Mavacoxib (Trocoxil) uygulandı. Uygulamanın 0, 60, 90 ve 180. günlerinde, her bir birey klinik olarak muayene edildi. Ayrıca, tüm hayvanlardan 0, 60, 90 ve 180. günlerde ilgili eklemlerden alınan synovial sıvıların analizi yapıldı. Ayrıca, 0 ve 180. günlerde CT analizi yapıldı. Dirsek eklemi dejenerasyonunda (OA); ADKOMKH ile tedaviye alınan hayvanlarda; ağrı, yürürken oluşan sertlikler, topallıklar gibi klinik semptomlar hafifledi. Kontrol grubundaki hayvanlar da deneyin ilk periyodun da gelişme görülmesinin aksine, OA semptomunun NSAIA uygulamasından 90 gün sonra tekrarladığı gözlemlendi. Bu çalışma, sadece klinik incelemenin görüntüsünü anlatan bir çalışma değil aynı zamanda synovial sıvı analizi ve CT değerlendirilmesine dayanan ilk çalışmadır. Otolog mezenkimal kök hücrelerin uygulanması metodun güvenliğini onaylayarak, herhangi bir istenmeyen reaksiyon sergilemedi. Bu çalışma, AdMSC uygulamasının köpeklerde osteofitik gerileme olmaksızın; dirsek eklemi osteoarthritisindeki verimliliği artırmış, klinik bulguları ve hasta kondüsyonunu geliştirmiştir.

**Anahtar sözcükler:** Adipoz-kökenli mezenşimal kök hücreler, Köpek, Dirsek eklemi bozukluğu, Osteoarthritis



### İletişim (Correspondence)



+90 532 3256478



nezirtoker@msn.com

## INTRODUCTION

In recent years, an increasing percentage of degenerative joint diseases have occurred in the practice of small animal veterinary medicine. This is due to several reasons, the most important of which is the genetics factor. It often does not show any signs in the early stage of ontogenesis but symptoms appear in later periods of life [1,2]. One of the most often occurring locomotive system disorders in dogs is elbow joint degeneration (EJD). This disease results in movement disturbances and consequently, may lead to different stages of lameness and/or a stiff gait. These symptoms may increase with exercise, long periods of inactivity or cold weather. Also, a high degree of pain and inflammation usually accompanies this disease.

EJD treatment is based mainly on steroidal and non-steroidal anti-inflammatory drug application [3]. Unfortunately, this treatment does not support the regeneration of damaged articular cartilage but only relieves pain and reduces the inflammatory process. Moreover, prolonged usage of the above mentioned drugs may indirectly lead to clinical complications and bring unsatisfying treatment progress [4]. Therefore, alternative treatment strategies should be established.

Last decade resulted in the discovery of mesenchymal stem cells and their pro-regenerative abilities [5-7]. This population of adult stem cells is common in many tissues, including bone marrow and subcutaneous fat. Mesenchymal stem cells are characterized by a high capacity for self-renewal and plasticity for differentiation, thus giving hope of returning to full efficiency before the disease state. Mesenchymal stem cells (MSC) are a promising tool in current veterinary medicine, which is confirmed by an increasing number of clinical trials [8,9]. Experiments performed both on animal and human beings showed that low differentiated MSC are able to differentiate into specialized cells within the wound site, as well as having paracrine and endocrine abilities that support the regeneration of damaged tissues [10]. Additionally, MSC also show immunomodulatory properties since they are able to interact with T-cells and suppress their inflammatory reactions [11]. This feature results in a decrease in pain and inflammation during cellular therapy [12].

In our current research, we focused on the clinical effects of autologous mesenchymal stem cell therapy in dogs suffering from elbow joint degeneration, with regards to gold standard (NSAIDs). We confirmed the results of similar work showed by Black et al. [1], and additionally showed the data obtained from computer tomography observations and synovial fluid analysis. Our results confirmed the advantage of autologous AdMSCs intraarticular injections over the standard NSAIDs treatment in improving the clinical picture and the patients' comfort of life.

## MATERIAL and METHODS

### **Ethical Approval**

Ethical Approval The experiment was conducted with the approval of Bioethical Commission, as stated by the Second Local Bioethical Commission at the Department of Biology and Animal Breeding, at University of Environmental and Life Sciences in Wrocław, Chelmonskiego 38C, Poland (dec. number 177/2010 from 11.15.2010).

### **Qualification of Patients**

For the medical experiment, twelve dogs were used (7 males, 5 females), between the ages of 5 and 11 years old. The breeds of the dogs were as follows: German Shepherd (4 individuals), Labrador Retriever (2 individuals), Boxer (2 individuals) and 4 crossbreeds, all of whom suffered from elbow joint degeneration that occurred at least 5 months before the therapy. Patients' weight was determined to be between 25 and 50 kg. The animals' owners signed the approval for experimental therapy, while this research is based on results from clinical case reports obtained for last two years in Surgery Department of University of Environmental and Life Sciences in Wrocław. Before the qualification to the therapy, blood tests were performed on all of the dogs for evaluation of their general condition and exclusion of any present comorbid diseases. In the clinical lameness evaluation, the lameness scale was applied, in which the 0 means no lameness and the 6 is the full walking disability. All animals undertaken to this study manifested walking disorders characteristic of osteoarthritis (OA), including lameness both in walking and trotting (2 and 3 from 6-ranged scale), limitation in range of movement and pain during manipulations. Computer tomography and synovial fluid analysis was performed in all of the qualified animals. According to the similarities in clinical symptoms, dogs were split into 2 groups with randomized individuals: the experimental group qualified for stem cell application consisted of 8 individuals, and the control group that undergo the NSAIDs treatment consisted of 4 individuals. Evaluations of synovial fluid were performed at day 0, 90 and 180 after treatment, while CT analyses were done at day 0 and 180. Clinical evaluations were performed at day 0, 60, 90 and 180. The control group consisted of one German Shepherd (6 years old, male), one Boxer (10 years old, female), one Labrador Retriever (5 years old, male) and one crossbred (8 years old, male), weighing between 25 and 50 kg. The experimental group consisted of the remaining 8 individuals (3 German Shepherds (5-10 years old, 1 male, 2 females), 1 Boxer (12 years old, female), 1 Labrador Retriever (5 years old, male) and 3 crossbreeds (7-11 years old, 2 males, 1 female) ), weighing also between 25 and 50 kg.

### **Computer Tomography**

Prior to CT investigation, animals were sedated by a

combination of Medetomidine (Cepetor, 10-20 µg/kg bw) with Butorphanol (Butomidol, 0.1-0.2 µg/kg bw) using intravenous cannula. In specific situations, animals were introduced into primary sleep using Propofol (Scanofol, 1 mg/kg bw). The examinations were performed by means of 16-row computer tomography (Siemens Somatom Emotion). CT investigations were performed in dorsal-ventral position of all qualified patients.

### Fat Tissue Collection

Dogs from the experimental group were sedated with Medetomidine (20 µg/kg) intramuscularly and with Butorphanol (200 µg/kg) intramuscularly. The area of iliac crest was prepared according to the surgery rules, followed by infiltration anesthesia with Lignocaine (2%). Afterwards, a sample of about 5 grams of adipose tissue was collected from all of the experimental animals for isolation and multiplication of MSC *in vitro*. Tissue samples were processed in sterile conditions under the laminar hood. Biopsies were washed with Hank's Balanced Salt Solution (HBSS, Sigma Aldrich) for any blood traces. Afterwards, tissues were minced and placed in collagenase solution (5 mg/mL, Sigma Aldrich) for 40 min at 37°C. After the digestion process, samples were centrifuged at 1200 g for 10 min for separation of mononucleated cells from the released oil and undigested tissue remnants. Cell pellets were re-suspended in a primary culture medium (DMEM:F12/Ham's with 10% of FBS and 1% of penicillin/streptomycin/amphotericin b, Sigma Aldrich) and placed in 25 cm<sup>2</sup> tissue culture flasks at a concentration of 5x10<sup>4</sup> cells/cm<sup>2</sup>. Cultures were maintained in a humidified incubator with 37°C and 5% CO<sub>2</sub>. After two days, the primary culture medium was changed to a secondary culture medium (DMEM with 4500 mg/L of glucose, 15% of FBS, 1% of penicillin/streptomycin/amphotericin b; Sigma Aldrich) and the cultures were propagated for the next five days. Before the application the cells were passaged twice. The time from adipose tissue collection to stem cell application was between 7 and 10 days. Cells were evaluated for proper morphology, phenotype (CD29<sup>+</sup>, CD44<sup>+</sup>, CD45<sup>-</sup>, CD105<sup>+</sup>) and behavior, in accordance with our previous research and the criteria determined by International Society for Cellular Therapy [12-14]. Microbiological tests were performed during the entire culture course for exclusion of any bacterial or fungal contamination. After multiplication, cells were collected in sterile 0.9% NaCl; counted and evaluated for viability, using the Thoma counting chamber and trypan blue exclusion methods. Afterwards, cell suspensions were collected into the syringe

at a concentration of 1.5x10<sup>6</sup> cells/mL and transported immediately to the clinic.

### Treatments

In experimental group, every individual received single injection of prepared autologous stem cell solution intra-articularly (1 ml/joint) to the elbow joint, two weeks after the collection of adipose tissue. Prior to the injection, animals were sedated using Medetomidine (20 µg/kg bw.) intramuscularly and with Butorphanol (200 µg/kg) intramuscularly, and the joint sites were prepared aseptically. The patients' owners were counseled to continue on prescribed rehabilitation program or walk their dogs two times a day. In the control group, animals were only treated with NSAIDs, which was Mavacoxib (Trocoxil, 2 mg/kg bw.) applied for six months (at day 0, 14 and once every next 30 days), administered orally.

## RESULTS

In a clinical examination on day 0, all 12 dogs manifested strong lameness of 2 and 3 degrees. In some cases, lameness was stronger during walking while others during a trot. At day 60, a clear improvement in the control group was noticed. Symptoms like stiffness in walk, pain and/or movement disabilities were prominently reduced. In dogs from the experimental group being treated with autologous stem cell applications, slight improvements were noticed at day 60, with decrease in lameness both in walk and in trot, and decrease in pain during manipulations. At day 90 in the control group, the results from clinical evaluation remained unchanged - the symptoms of movement disorders remained at the same level, while the pain was intensified, especially during manipulations. In experimental animals clinical results continued to improve - symptoms like walking stiffness and lameness or pain were found in only 3 of the 8 individuals from AdMSCs group. At day 180 in the experimental dogs, the clinical evaluation did not reveal any symptoms of walking disorders - lameness during walking and trotting and pain during manipulations were completely reduced. Only the range of movement in the joints remained at a constant, limited level. On the other hand, animals which received the NSAIDs manifested prominent lameness at the higher level than in day 0. The averaged results are shown in [Table 1](#).

The results from synovial fluid analysis correlated with clinical pictures of the examined animals. At day 0 in all 12 dogs, characteristic signs of chronic joint

**Table 1.** Mean results of lameness evaluation ± standard deviation at day 0, 60, 90 and 180

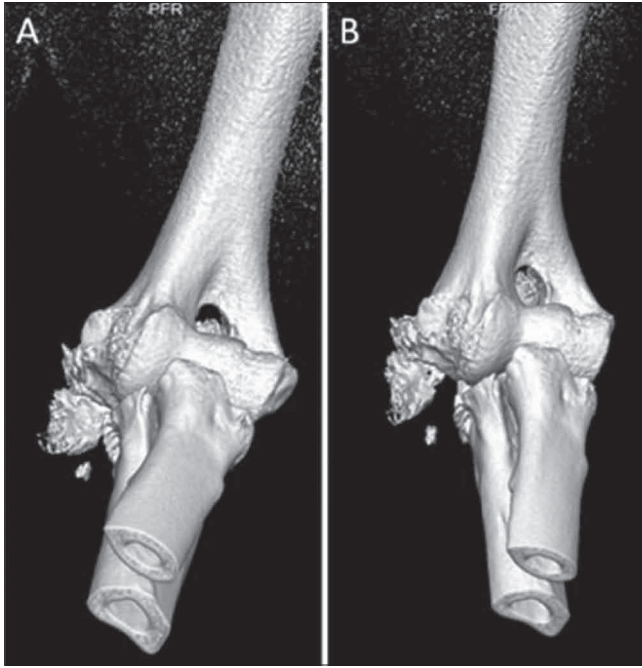
**Table 1.** Laminitisin gelişiminde ortalama sonuçların 0, 60, 90 ve 180. günlerdeki standart sapmasının ± değerlendirilmesi

Group	Day 0	Day 60	Day 90	Day 180
AdMSCs	2.5±0.53	1.87±0.64	0.37±0.51	0.12±0.35
NSAIDs	2.3±0.57	1.5±0.57	1.5±0.5	3.75±0.5

degeneration were detected. The leukocyte level was determined below  $6 \times 10^3/L$ , neutrophil level between 5 to 12%, and mononuclear cells in the range between 86 and 98 (individual cells). The synovial fluid was evaluated from light-yellow to colorless, clear, and in 7 cases slightly turbid. At day 90 in dogs from the control group, these parameters remained unchanged. Synovial fluid was determined slight turbid, however leukocyte, neutrophil and mononuclear cell levels were decreased. Clinical improvement was observed in the experimental group treated with stem cell therapy. Only in 2 cases was the synovial fluid turbidity maintained, and only 1 of the 8 was viscosity still decreased. Remaining parameters were within the normal range, where the leukocyte number was determined below  $4 \times 10^3/L$ , and the percentage of neutrophils decreased below 5%. At day 180 in the control group, the results showed deterioration. The leukocyte,

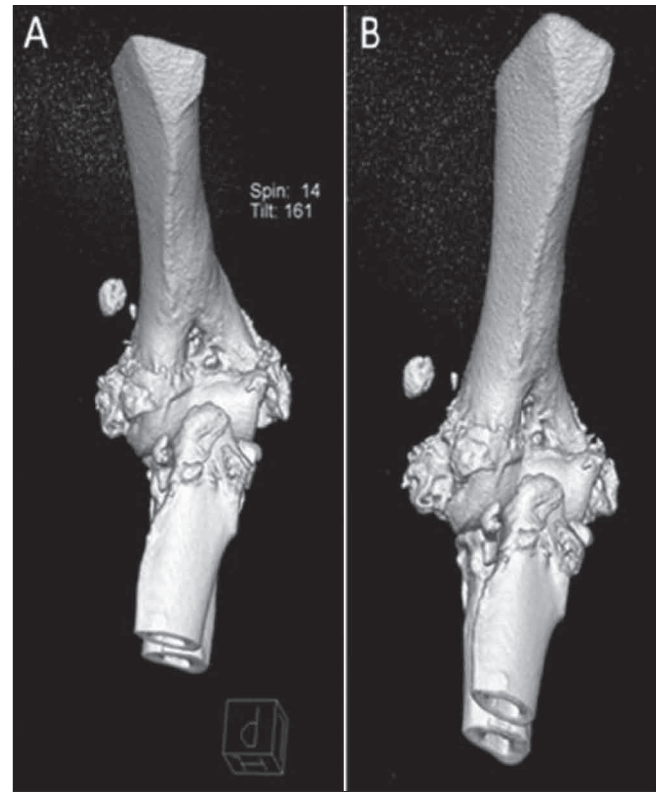
neutrophil and mononuclear cell levels were increased, and no increase in synovial fluid viscosity was noticed. In the experimental group, the synovial fluid analysis showed no signs of chronic inflammation. The number of leukocytes, as well as neutrophils and mononuclear cells was determined to be within normal range. In one case, persistent synovial colorless, with normal viscosity. The averaged results are shown in [Table 2](#).

Computer tomography investigations in animals of both groups revealed osteoarthritis of elbow joint with prominently visible degenerative changes on medial epicondyle of humerus. The administration of AdMSCs in experimental group did not result in improvement of superficial bone changes.



**Fig 1.** Computer tomography pictures showing changes in the elbow joint in dog from experimental group before (day 0, A) and 180 days after the application stem cells (B)

**Şekil 1.** Deney grubunda, 0. günde (A) ve 180. günde kök hücre uygulamasından sonra (B) köpek dirsek eklemindeki değişimini gösteren bilgisayar tomografi resmi



**Fig 2.** Computer tomography pictures showing changes in the elbow joint in dog from control group at day 0 (A) and day 180 of experiment (B)

**Şekil 2.** Kontrol grubunda deneyin 0. günde (A) ve 180. günde (B) köpek dirsek eklemindeki değişimini gösteren bilgisayar tomografi resmi

**Table 2.** Mean results  $\pm$  standard deviation of synovial fluid analysis at day 0, 90 and 180 in experimental and control group

**Tablo 2.** 0, 90 ve 180. günlerde ki siynovial sıvı analiz bulguların standart sapması  $\pm$

Group	Day 0		Day 90		Day 180	
	L/N%/M	SFCol/SFClar/SFV	L/N%/M	SFCol/SFClar/SFV	L/N%/M	SFCol/SFClar/SFV
EXP	4.12 $\pm$ 0.83/9.1 $\pm$ 2/ 94.5 $\pm$ 2.4	Colorless/slight turbid/ decreased	2.37 $\pm$ 0.91/3.1 $\pm$ 1.6/ 93.4 $\pm$ 1.6	Colorless/clear /normal	2.37 $\pm$ 0.74/2.75 $\pm$ 1.39 /90.5 $\pm$ 2	Colorless/clear /normal
CTRL	4 $\pm$ 1.41/10.2 $\pm$ 3.3/ 94 $\pm$ 2.8	Colorless/slight turbid/ decreased	3.75 $\pm$ 2.06/5.7 $\pm$ 3.9/ 93.7 $\pm$ 2.1	Colorless/slight turbid/decreased	4.5 $\pm$ 1.29/9 $\pm$ 2.58 /97.2 $\pm$ 0.95	Light yellow/slight turbid/decreased

L/N%/M - Leukocyte number ( $\times 10^3/l$ )/Neutrophil percentage/Mononuclear cell number; SFCol/SFClar/SFV - Synovial fluid color/Synovial fluid clarity/Synovial fluid viscosity

## DISCUSSION

Presently, many dogs of different age and breed suffer from degenerative joint disorders (DJD). Since 1990, the Orthopedic Foundation for Animals has noticed that 78 breeds are predisposed to DJD, of which 1.2% to 47.9% suffer directly from elbow joint degeneration (EJD) [15]. This disorder results in various degrees of lameness and pain, but in some cases it shows no prominent clinical manifestation [16]. Among many locomotive system disorders in dogs, osteoarthritis (OA) of the elbow joint has no satisfactory treatment yet. Optimal therapy should guarantee the full recovery of physical activity and considerable pain reduction. The existing methods of OA treatment are based primarily on the application of steroidal and/or non-steroidal anti-inflammatory drugs, which act only temporarily [17]. One of the most promising treatment methods is the auto-transplantation of mesenchymal stem cells isolated from adipose tissue [18]. In current research, we decided to treat patients with elbow joint OA using this novel method for evaluation of its actual efficiency. Our previous studies [19,20] showed beneficial effects of AdMSCs applications in equine hoof fractures and tendon disorders. These results, also confirmed by other clinical groups, support the thesis that AdMSCs application may induce the tissue regeneration processes [21]. Our findings suggest that mesenchymal stem cells work multi-directionally. Because of their multi-potent character and self-renewal capacity, AdMSCs might differentiate into chondrocytes under suitable circumstances. This leads to cartilage regeneration and thus recovery of physical activity. Most likely it may be caused by the paracrine effect of stem cells, which when introduced into an inflammatory environment, respond by shedding mesenchymal microvesicles (mMVs), as was reported by other groups [22]. An additional advantage of stem cell therapy is the immunomodulatory action of MSC [23], which leads to a decrease in local joint inflammation. Therefore, we can conclude that auto-transplantations of adipose-derived mesenchymal stem cells may also be utilized as anti-inflammatory agent, without causing adverse reactions seen after prolonged NSAIDs application. This thesis can be supported by our results from a cytological examination of synovial fluid, where the decrease in infiltrating inflammatory cells was noticed. Although the tendency is clear, the statistical analysis could not be performed because of the low number of individuals included in this research. Also no double blinded examination was performed, since this work is based on observations done from particular case reports.

The analysis of computer tomography pictures revealed that presence of significant osteophytes remained unchanged, both in experimental and control groups. It suggests that stem cell therapy treatment cannot decrease the quantity of osteophytes, although it brings the relief in pain and inflammation. According to other groups'

findings [24], we assume that these beneficial effects strictly correlate with stem cell paracrine action.

After the application of stem cells, none of patients exhibited any adverse reaction, which confirmed the safety of this method. In the first evaluation period of the experimental group, symptoms like stiffness in walking and lameness were slightly reduced, while in the control group, they substantially intensified.

In conclusion, the therapy with autologous mesenchymal stem cells isolated from adipose tissue in cases of elbow joint degenerative disorders decreases discomfort by reducing accompanying clinical symptoms like pain, stiffness in walking and lameness. Therefore, we state that this method is a substantial advance over the NSAIDs treatment, which works only in short time periods and may bring many adverse reactions. However, there is still lack of information about long-term therapeutic effect of MSC application and about the quality of regenerated cartilage after stem cell applications, so further prolonged experiments are essential.

## REFERENCES

1. Black LL, Gaynor J, Adams C, Dhupa S, Sams AE, Taylor R, Harman S, Gingerich DA, Harman R: Effect of intraarticular injection of autologous adipose- derived mesenchymal stem and regenerative cells on clinical signs of chronic osteoarthritis of the elbow joint in dogs. *Vet Ther*, 9 (3): 192-200, 2008.
2. Sandell LJ: Etiology of osteoarthritis: Genetics and synovial joint development. *Nat Rev Rheumatol*, 8 (2): 77-89, 2012.
3. Coleman CM, Curtin C, Barry FP, O'Flatharta C, Murphy JM: Mesenchymal stem cells and osteoarthritis: Remedy or accomplice? *Hum Gene Ther*, 21 (10): 1239-1250, 2010.
4. Hochberg MC, Altman RD, Brandt KD, Clark BM, Dieppe PA, Griffin MR, Moskowitz RW, Schnitzer TJ: Guidelines for the medical management of osteoarthritis. *Arthritis Rheum*, 38 (11): 1535-1540, 1995.
5. Del Bue M, Riccò S, Ramoni R, Conti V, Gnudi G, Grolli S: Equine adipose-tissue derived mesenchymal stem cells and platelet concentrates: Their association in vitro and in vivo. *Vet Res Commun*, 32 (1): 51-55, 2008.
6. Tuglu MI, Ozdal-Kurt F, Koca H, Sarac A, Barut T, Kazanc A: The contribution of differentiated bone marrow stromal cell-loaded biomaterial to treatment in critical size defect model in rats. *Kafkas Univ Vet Fak Derg*, 16 (5): 783-792, 2010.
7. Marycz K, Krzak-Roś J, Śmieszek A, Grzesiak J, Donesz-Sikorska A: Effect of oxide materials synthesized with sol-gel method on adhesion of mesenchymal stem cells. *Przem Chem*, 92 (6): 1097-1100, 2013.
8. Fortier LA, Smith RKW: Regenerative medicine for tendinous and ligamentous injuries of sport horses. *Vet Clin North Am: Equine Pract*, 24 (1): 191-201, 2008.
9. Qui Y, Feng G, Yan W: Mesenchymal stem cell-based treatment for cartilage defects in osteoarthritis. *Mol Biol Rep*, 39 (5): 5683-5689, 2012.
10. Hodgkiss-Geere HM, Argyle DJ, Corcoran BM, Whitelaw B, Milne E, Bennett D, Argyle SA: Characterisation and differentiation potential of bone marrow derived canine mesenchymal stem cells. *Vet J*, 194 (3): 361-368, 2012.
11. Lai RC, Chen TS, Lim SK: Mesenchymal stem cell exosome: A novel stem cell-based therapy for cardiovascular disease. *Regen Med*, 6 (4): 481-492, 2011.
12. Kang JW, Kang KS, Koo HC, Park JR, Choi EW, Park YH: Soluble factors-mediated immunomodulatory effects of canine adipose tissue-

derived mesenchymal stem cells. *Stem Cells Dev*, 17 (4): 681-693, 2008.

**13. Grzesiak J, Marycz K, Wrzeszcz K, Czogała J:** Isolation and morphological characterisation of ovine adipose-derived mesenchymal stem cells in culture. *Int J Stem Cells*, 4 (2): 99-104, 2011.

**14. Grzesiak J, Marycz K, Czogała J, Wrzeszcz K, Nicpoń J:** Comparison of behavior, morphology and morphometry of equine and canine adipose derived mesenchymal stem cells in culture. *Int J Morphol*, 29 (3): 1012-1017, 2011.

**15. Olsson SE:** Osteochondrosis in domestic animals. *ACTA Radiologic*, 358 (Suppl.): 299-305, 1978.

**16. Grondalen J:** Arthrosis in the elbow joint of young, rapidly growing dogs: Interrelation between clinical radiological and pathoanatomical findings. *Nordish Veterinarmedicin*, 34, 65-75, 1982.

**17. Luna SPL, Basilio AC, Steagall PVM, Machado LP, Moutinho FQ, Takahira RK, Brandao CVS:** Evaluation of adverse effects of long-term oral administration of carprofen, etodolac, flunixin meglumine, ketoprofen, and meloxicam in dogs. *Am J Vet Res*, 68 (3): 258-263, 2007.

**18. Guercio A, Di Marco P, Casella S, Cannella V, Russotto L, Purpari G, Di Bella S, Piccione G:** Production of canine mesenchymal stem cells from adipose tissue and their application in dogs with chronic osteoarthritis of the humeroradial joints. *Cell Biol Int*, 36 (2): 189-194, 2012.

**19. Marycz K, Toker NY, Grzesiak J, Wrzeszcz K, Golonka P:** The therapeutic effect of autogenic adipose derived stem cells combined

with autogenic platelet rich plasma in tendons disorders in horses *in vitro* and *in vivo* research. *J Anim Vet Adv*, 11 (23): 4324-4331, 2012.

**20. Marycz K, Grzesiak J, Wrzeszcz K, Golonka P:** Adipose stem cell combined with plasma-based implant bone tissue differentiation in horse suffered phalanx digitalis distalis fracture and *in vitro*. *Vet Med Czech*, 57 (12): 610-617, 2012.

**21. Black LL, Gaynor J, Gahring D, Adams C, Aron D, Harman S, Gingerich DA, Harman R:** Effect of adipose-derived mesenchymal stem and regenerative cells on lameness in dogs with chronic osteoarthritis of the coxofemoral joints: A randomized, double-blinded, multicenter, controlled trial. *Vet Ther*, 8 (4): 272-284, 2007.

**22. Ratajczak J, Kucia M, Mierzejewska K, Marlicz W, Pietrzkowski Z, Wojakowski W, Greco NJ, Tendera M, Ratajczak MZ:** Paracrine proangiopoietic effects of human umbilical cord blood-derived purified CD133+ cells-implications for stem cell therapies in regenerative medicine. *Stem Cells Dev*, 22 (3): 422-430, 2013.

**23. Nicpoń J, Marycz K, Grzesiak J:** The therapeutic effect of adipose derived mesenchymal stem cells injection in horses suffering from bone spavin. *Polish J Vet Sci*, 16 (4): 753-754, 2013.

**24. Ratajczak J, Wysoczynski M, Hayek F, Janowska-Wieczorek A, Ratajczak MZ:** Membrane-derived microvesicles: Important and under-appreciated mediators of cell-to-cell communication. *Leukemia*, 20 (9): 1487-1495, 2006.